

## The Cause

# Autopsy Report On the Death

Los Angeles

Senator Robert F. Kennedy's death was due to a "gunshot wound of the right mastoid penetrating the brain," Dr. Thomas T. Noguchi, Los Angeles county medical examiner, reported yesterday after a six-hour autopsy.

Dr. Noguchi indicated that pressure on the brain stem due to swelling of the brain and bleeding was a major factor in causing the 42-year-old senator's death.

The medical examiner told a press conference that the secondary pressure effect, rather than the penetration of the bullet, cause the brain stem damage.

### FINDINGS

Dr. Noguchi declined to answer questions which sought to get a more detailed explanation of the autopsy results. He said the complete findings will be compiled in an official document available "in due time."

Some of the more complete findings could be ready in a

few days, Dr. Noguchi said. He said "a number" of analyses, including microscopic tests of brain tissue, and study of X-rays taken before and after death, must be concluded.

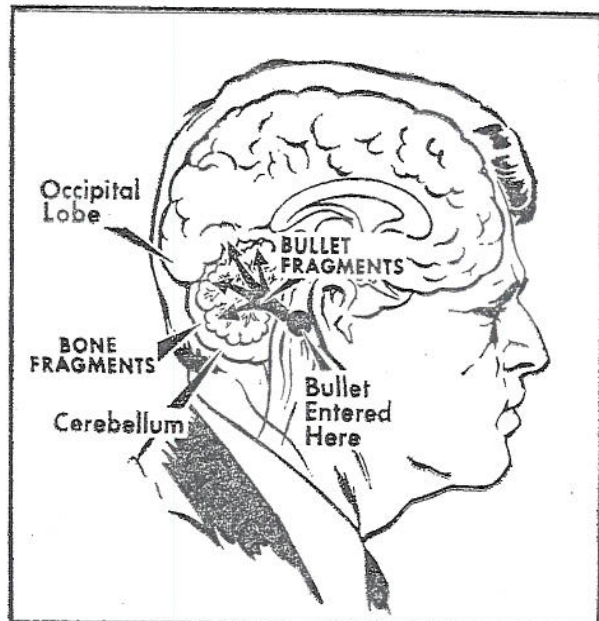
He said that scattered fragments of a single bullet and pieces of bone damaged the right side of the brain.

Dr. Noguchi declined to state the exact trajectory of the bullet, which entered the head behind the right ear, except to say that the trajectory was "from right to left and basically upward."

In response to questions he said the artery that serves the cerebellum was severed but declined to be specific.

He said there was X-ray evidence of fragments of the bullet in the right cerebrum, the thinking part of the brain. He added, however that the X-rays require further examination before cerebral damage can be stated for certain.

The news conference was replete with unanswered questions and confusion



UPI Telephoto

A diagram of the fatal wound

caused by the profusion of television cameras and reporters and the coroner's soft-voiced responses.

Dr. Noguchi said the autopsy showed that the surgery by the team which tried to save the senator's life was "amazing and very delicate."

A second bullet was found in the lower portion of the back of the neck, just beneath the skin. The physician said entry of this bullet was by way of the back of the right armpit.

The autopsy was per-

formed at Good Samaritan Hospital where Senator Kennedy died at 1:44 a.m. yesterday.

Times-Post Service

## Segovia's Surgery

Granada, Spain

Guitarist Andres Segovia, 74, was in good condition yesterday following an eye operation for a detached retina. The operation Wednesday was the second in less than a year on Segovia's eyes.

United Press