

# Blood Clot Lodged in

By Leroy F. Aarons

Washington Post Staff Writer

LONG BEACH, Calif., Sept. 25—Former President Nixon has a blood clot in his right lung that signals a "potentially dangerous situation," his doctor announced today.

Dr. John C. Lungren, Mr. Nixon's attending physician at Long Beach Memorial Hospital, told a hastily called press conference this morning that the condition, while dangerous, "is not critical at this time."

He said Mr. Nixon would continue to receive anti-coagulant drugs both intravenously and orally, but that his stay would extend beyond the originally projected one week, to 10 days to two weeks.

Mr. Nixon's lung blood clot, a condi-

tion called an embolism in medical terms, is a direct outgrowth of the phlebitis ailment in the vein of his left leg, Lungren explained. Part of the clot broke off in the leg, traveled through the vein and lodged in the "right mid-lung field on the lateral surface."

The clot—about the size of a dime—has caused some tissue damage and affected circulation in that section of the lung, Lungren said. The risk, he added, "is the breaking off of another clot, a larger clot which would cause more damage to the lung and a real danger at that time."

He said Mr. Nixon was responding to the anti-coagulant treatment, but it was too early to tell the response in the lung. He said no additional or dif-

ferent treatment has been prescribed. He said the former President had no pain in that part of his body, adding that it was not uncommon for a lung clot to remain "silent" and undetected.

The clot was discovered by an advanced medical detection method, using radioactive isotopes and a sensitized scanning device called an Ohio Nuclear camera. It works like this: a patient swallows or receives by injection the isotope, which is targeted for the ailing organ. The camera focuses on the isotope—which acts as a kind of internal X ray—and transmits a dotted picture to an accompanying console, from which a medical expert can read the presence of damage or other symptoms.

Mr. Nixon was given the roughly 40-

## Nixon's Lung

minute examination by Dr. Earl Dore, director of Long Beach Memorial's nuclear medicine department. The former President underwent two kinds of tests: a blood profusion scan and an "airway patency" scan. The first, hospital officials explained, was to determine blood flow in the lung, and the second to determine air flow.

Lungren said Mr. Nixon took the news of his lung clot "as he normally takes anything else."

He added, paraphrasing the former President, "It's another problem. I hate to be sitting here, lying with this thing in my vein [the intravenous application] all the time; can't move around. But, he said, if we have to do it, we have to do it."

Lungren implied, however, that Mr.

Nixon may have been chiefly responsible for the latest complication by resisting repeated pleas to accept treatment. He said Mr. Nixon refused treatment on at least two occasions in the past three months. He traced the former President's medical history as follows:

In June, just before his Middle East trip, Mr. Nixon developed swelling and pain in the lower left leg, but resisted his doctor's advice for treatment because "he decided there were more important things, and he went on his trip."

The phlebitis recurred while the then-President was in Egypt and again in Russia.

See NIXON, A6, Col. 1



Nixon at farewell to staff.

### NIXON, From A1

"Since he has left the White House he had no particular problem other than a continued swelling in the leg, and when he would get up and walk or ride for any period of time the leg would begin to swell to a great amount."

Lungren said Mr. Nixon had been warned by his personal physician, Dr. Walter Tkach, that any discomfort above the knee could mean trouble. Such discomfort occurred while Mr. Nixon was in Palm Springs at the home of his friend, Walter Annenberg.

Lungren examined him there on Sept. 11 and diagnosed a spreading of the phlebitis. He advised immediate hospitalization, but Mr. Nixon refused. He finally agreed to begin taking "anti-inflammatory drugs."

A week later, Lungren examined him again in San Clemente and again urged hospitalization. Mr. Nixon then

agreed, and entered the hospital Monday.

Experts in Washington, D.C., questioned Lungren's use of a lung scan to make his diagnosis. One cardiologist said that a lung scan is not precise enough to furnish proof positive that a clot exists, and that, in any case, it could not identify a clot as small as a dime.

But, this expert said, Mr. Nixon's history of phlebitis allows Lungren to make "the presumption" that the lung scan abnormality was caused by a blood clot.

Dr. John M. Keshishian, a surgeon who specializes in operation on blood vessels, said he would insist on an angiogram—an X ray using dyes—of the lung which would definitely show if a clot were involved.

The former President is staying in a private room in a recently opened ward on the hospital's sixth floor.

He is being attended by a medical corpsman not connected with the hospital, according to official sources, as

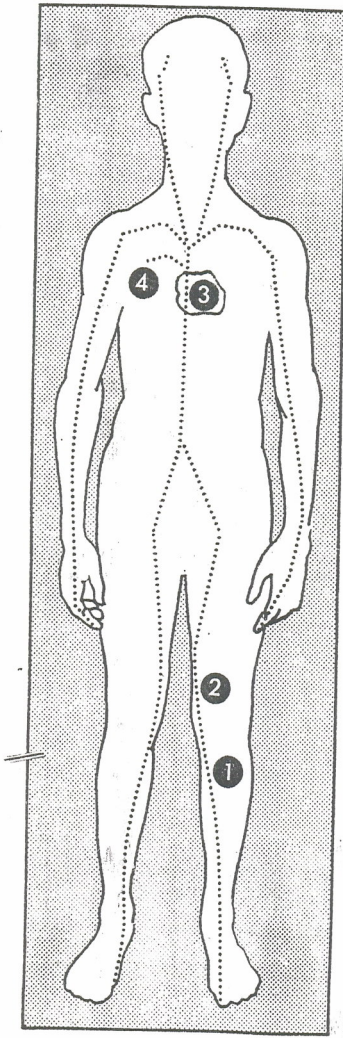
well as the regularly assigned ward nurses. He is eating hospital food, on a diet related to the treatment he is receiving.

Well-wishers have sent dozens of bouquets and messages to the former President, who asked that the flowers be distributed to rooms in the hospital without flowers. He gave a bouquet of huge roses and chrysanthemums to a hospital volunteer, Mary Huebner, who greeted Mr. Nixon when he arrived on Monday.

Mrs. Huebner said she was asked to bring a wheelchair to the ward for Mr. Nixon's use. "I think he is a sick man," she told a reporter, "and he looked to be under stress."

Lungren said Mr. Nixon was being given the anti-coagulant heparin intravenously, and, a drug called coumadin orally.

Lungren said he is not considering surgery for Mr. Nixon "at this time." He said the clot would not cause permanent damage "unless it extended."



The Washington Post

No. 1 locates site of June phlebitis; 2 is the current phlebitis from which piece of clot broke loose; 3 is the heart, and 4 the right lung.