

Anatomy of an Embolus

Until early last week, Richard Nixon's troubles with blood clots seemed confined to his sometimes painfully swollen left leg. The announcement that a clot had evidently passed through his heart and lodged in his right lung suggested that his life may indeed have been imperiled by his condition, if only momentarily. But the presence of such obstructions in the bloodstream is far more common than was generally realized only a few years ago and it is now evident that in only relatively few cases are they truly dangerous.

Nixon has been troubled by phlebitis—inflammation of a vein or veins—in his left leg on and off for ten years. In such cases, the medical problems begin with the valves in the veins that serve to keep blood flowing back to the heart. When these valves become inflamed—it may be from injury, infection, some forms of cancer or simply sluggish blood flow from inactivity—some blood is likely to be trapped in a pocket where it forms a clot. The danger then is that the clot, or thrombus, will begin to travel toward the heart and lungs.

Deeper Danger. When a thrombus does travel, it is called an embolus. The likelihood of an embolus appearing is negligible when the inflamed vein is near the skin's surface; it is vastly greater, however, if the clot forms in one of the large, deep veins. That is what apparently happened in Nixon's case. For some time after its formation in a vein deep in his left leg, the clot stayed in place. There, it caused the intermittent but painful swelling that bothered Nixon on his trip to the Middle East last June and, more severely, during his five-day stay at the Annenberg estate in Palm Springs early in September. At some point, Nixon's physicians say, a part of that clot, or possibly a new one, broke loose. The embolus was carried away in the bloodstream, like debris in a fast-flowing river, through the iliac vein and the inferior vena cava into the heart (see diagram).

The next move was potentially the most dangerous: if the clot had been as big as the end of a man's thumb, as some are, it could have caused a complete blockage of the great artery through which blood is pumped from the heart to the lungs. The result would have been a dramatic collapse of the patient and perhaps sudden death. Smaller clots usually produce only minor local lung damage.

Nixon's lung clot was evidently a small one—only "dime-size," speculated Dr. John Lungren, the ex-President's internist. Lungren and Radiologist Earl K. Dore discovered the clot through two recently refined tests using radioactive isotopes. First they injected human albu-

men tagged with radioactive iodine-131 or technetium into an arm vein. The radiant particles circulated through the small blood vessels of Nixon's lungs, and a scintillation scanner took an electronic "picture" of their distribution. Nixon's scan showed a blank area on the outer side of the right lung: the clot had settled there in a small artery, leaving an area of dead tissue where no blood is circulated to take up oxygen. Then the doctors ran a second test to determine whether Nixon's respiratory passages were open to this area and thus rule out any other lung disease. For this, Nixon inhaled an aerosol containing radioactive technetium. This time the scanner showed no obstruction.

Lungren prescribed the anticoagu-

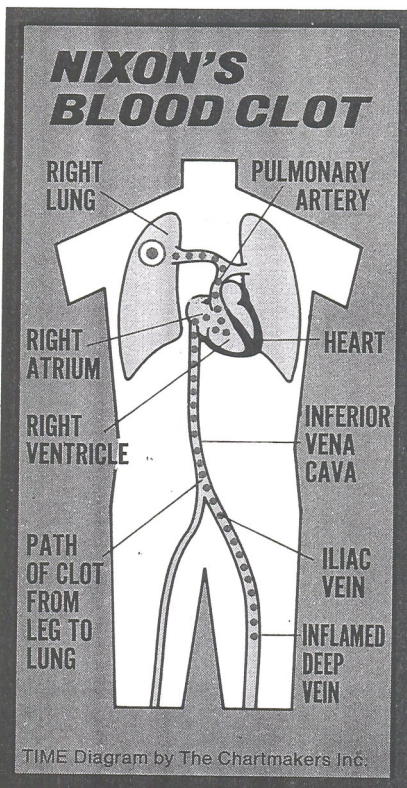
Increasing the Risk

When the records of hospital patients are analyzed by a computer, the electronic brain sometimes makes surprising discoveries by collating and relating data that a human mind would take many years to process. This has happened in the Boston metropolitan area, where a Boston University team led by Dr. Hershel Jick analyzed the records of 25,000 patients admitted to 24 hospitals in 1972. The surprise finding, reported in the British medical journal the *Lancet*, is that women aged 50 or over who take certain types of medication to relieve mild cases of high blood pressure run a threefold increased risk of developing breast cancer.

Some 10% to 20% of all U.S. women in the over-50 age group have some degree of hypertension, and hundreds of thousands of them are being medically treated for the condition. Most of these patients take a small daily dose of reserpine or a related alkaloid, both extracted from the roots of the Indian shrub, *Rauwolfia serpentina*. The rauwolfia products have been in use for 20 years, have generally been well tolerated in the dosage used by patients, and are inexpensive compared with newer medications for lowering blood pressure, such as guanethidine and methyldopa. The Boston team listed six products containing reserpine, usually in combination with a diuretic medication, that had been prescribed for the patients studied; dozens more are sold in the U.S. and other countries.

Cautious Checks. The investigators found that eleven, or 7.3%, of 150 women with newly diagnosed breast cancer had been taking reserpine medicines, whereas only 2.2% of 1,200 patients without breast cancer (but otherwise similar to the cancer-stricken women in age and other characteristics) had taken them. They reanalyzed their data to rule out hypertension itself as a cause or accelerator of breast cancer and also found no association with the alternative hypertension drugs. Cautious to a degree and determined not to be alarmist, the Boston group invited eminent epidemiologists in England and Finland to run a similar check. Their results were essentially the same.

Theories as to how reserpine-type alkaloids might influence breast cancer are inconclusive. A leading U.S. cancer epidemiologist, Manhattan's Dr. Ernest L. Wynder, believes that the action is not to cause the cancer—that usually takes many years—but to stimulate or accelerate its development. A somber *Lancet* editorial suggests that doctors will now have to weigh the apparently greater risk of breast cancer against the advantages of lowering blood pressure for mature women.



lants heparin (which must be injected) and Coumadin (taken by mouth) to prevent the formation of new clots. But the anticoagulants have little if any ability to dissolve existing clots. Given time, the human bloodstream will usually clear out clot debris on its own.

Some doctors suggested that Nixon's clot might be an old one that adhered to the lung wall some time ago. In that case, he would no longer need the heparin drip treatment. Lungren conceded that in any event, the clot was not causing pain or making it difficult for Nixon to breathe. The doctor explained that "it is not unusual to have a 'silent' clot"—meaning one that produces no symptoms.