

7627 Old Receiver Road
Frederick MD 21702

January 31, 1994

Mr. Larry J. Papp
59 Collingdon Drive
Brantford, Ontario
N35 3Cp CANADA

Dear Mr. Papp:

Thank you very much for your letter and the tracings of the hand-drawn sketches of the President's head wounds. My husband is pleased to have them and appreciates your sending them to him. They will be a part of the Crenshaw file in the archive established for his records at the local Hood College.

We both appreciate your good wishes and thank you for your understanding.

Sincerely,



Lillian Weisberg

Jan. 14/94

Larry J. Papp
59 Collingdon Dr.
Brantford, Ont. Canada
N3S 3C9

Dear Mrs. Weisberg:

I am saddened and concerned for Mr. Weisberg's state of health. I respect the fact he will be unable to correspond with me. I appreciate your reply in letting me know the circumstances and in giving me Dr. Cyril Wechts address. I had watched a documentary on television and there was a Dr. Charles Crenshaw on it. Apparently he was interviewing on the day President Kennedy was brought in. I wrote him and he replied with hand drawn pictures of the President's head wounds. I am enclosing them for they may be of interest to Mr. Weisberg, I hope. Dr. Crenshaw's drawings of which I traced leave no doubt of the directions of some of the shots fired. His drawings are backed up by Dr. Mc Celland of whom Dr. Crenshaw assisted at the time. I will trouble you no further, take care Mrs. Weisberg and please tell Mr. Weisberg he will be in my thoughts and I wish him only the best.

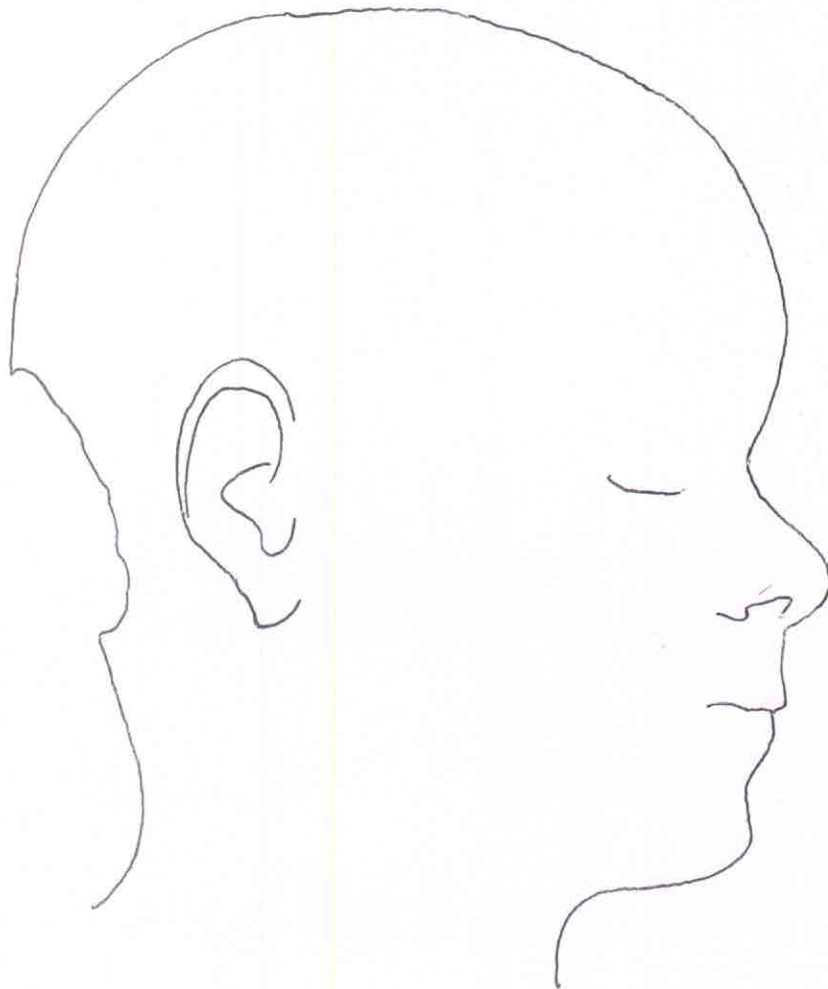
THANK YOU

Yours Sincerely
Larry J. Papp

DR. CHARLES A CRENSHAW M.D. F.A.C.S
DIRECTOR, DEPARTMENT OF SURGERY
JOHN PETER SMITH HOSPITAL OR
CHARLES A CRENSHAW, M.D. 215 N. RIVERCREST DR.
FORT WORTH, TEXAS 76107

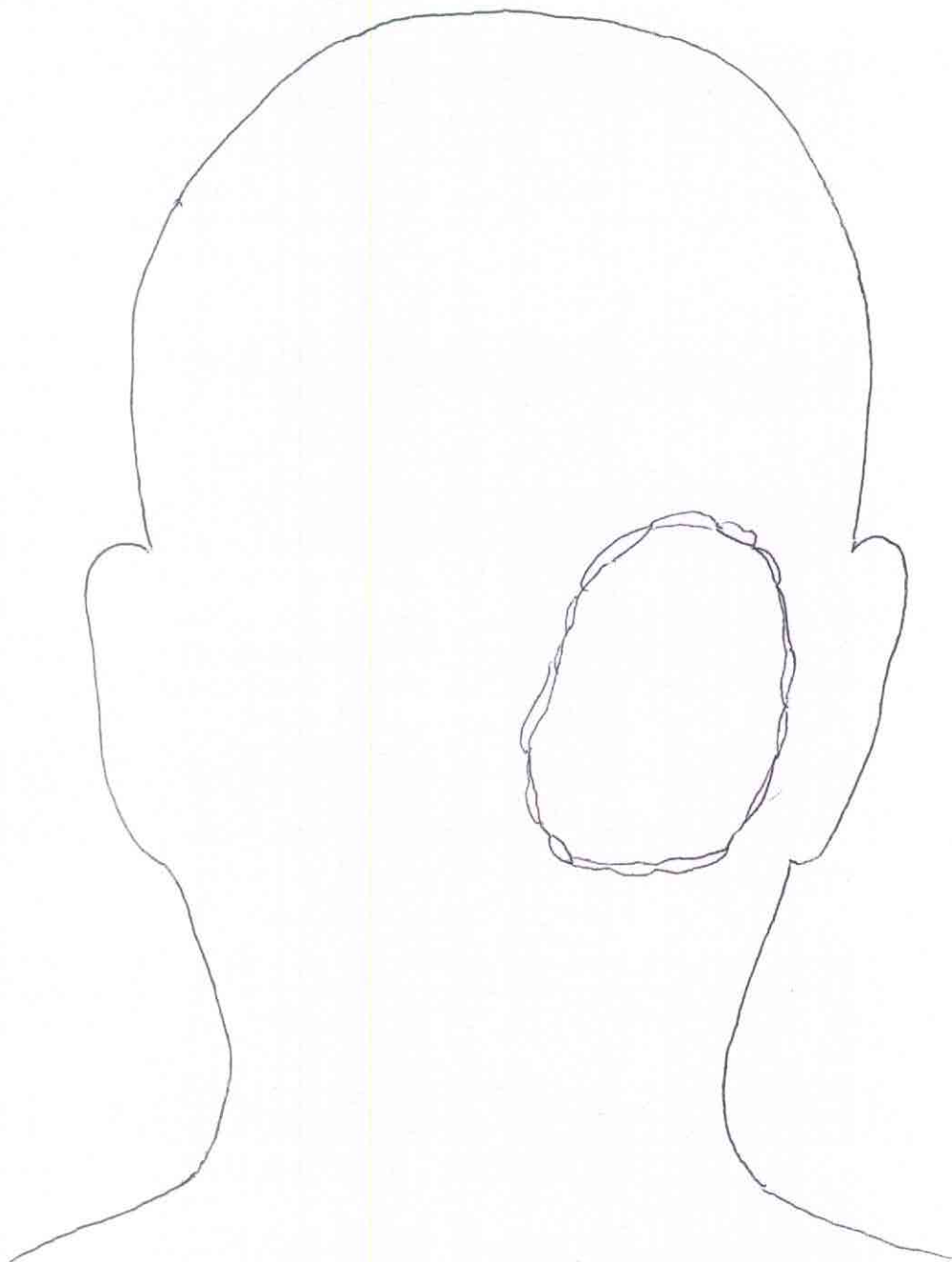
Mr. Weisberg all writing or printing on these drawings are Dr. Crenshaw's own words.

ALL DRAWINGS ARE FAITHFULL TRACINGS OF THOSE RECEIVED.



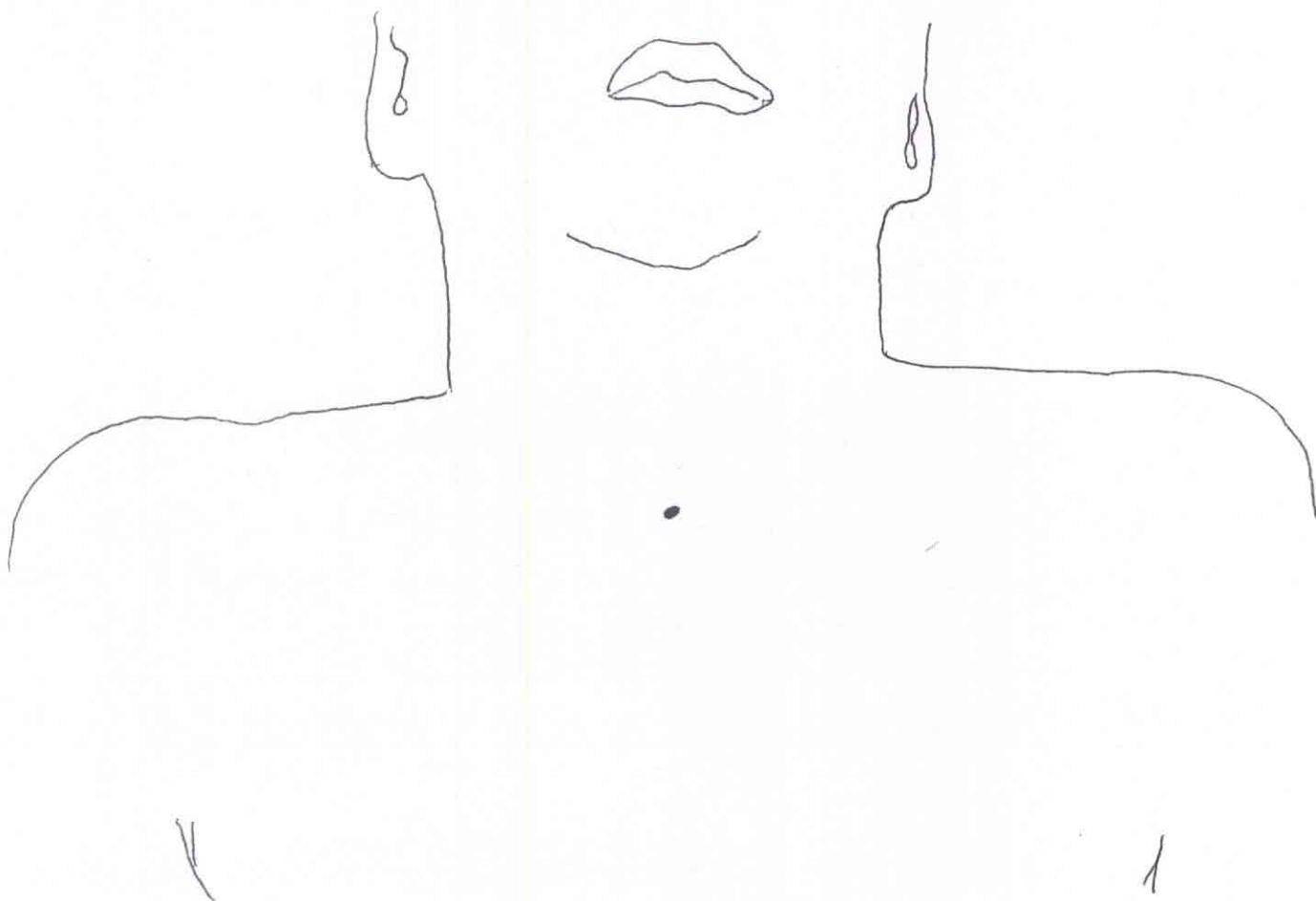
SIDE VIEW - RIGHT REAR OF HEAD

LARGE AVULSED AREA WITH LOSS OF SOME PARIETAL
AND MOST OF OCCIPITAL AREA OF LESION



EXIT WOUND - RIGHT REAR OF HEAD - (OCCIPITAL-PARIETAL AREA)

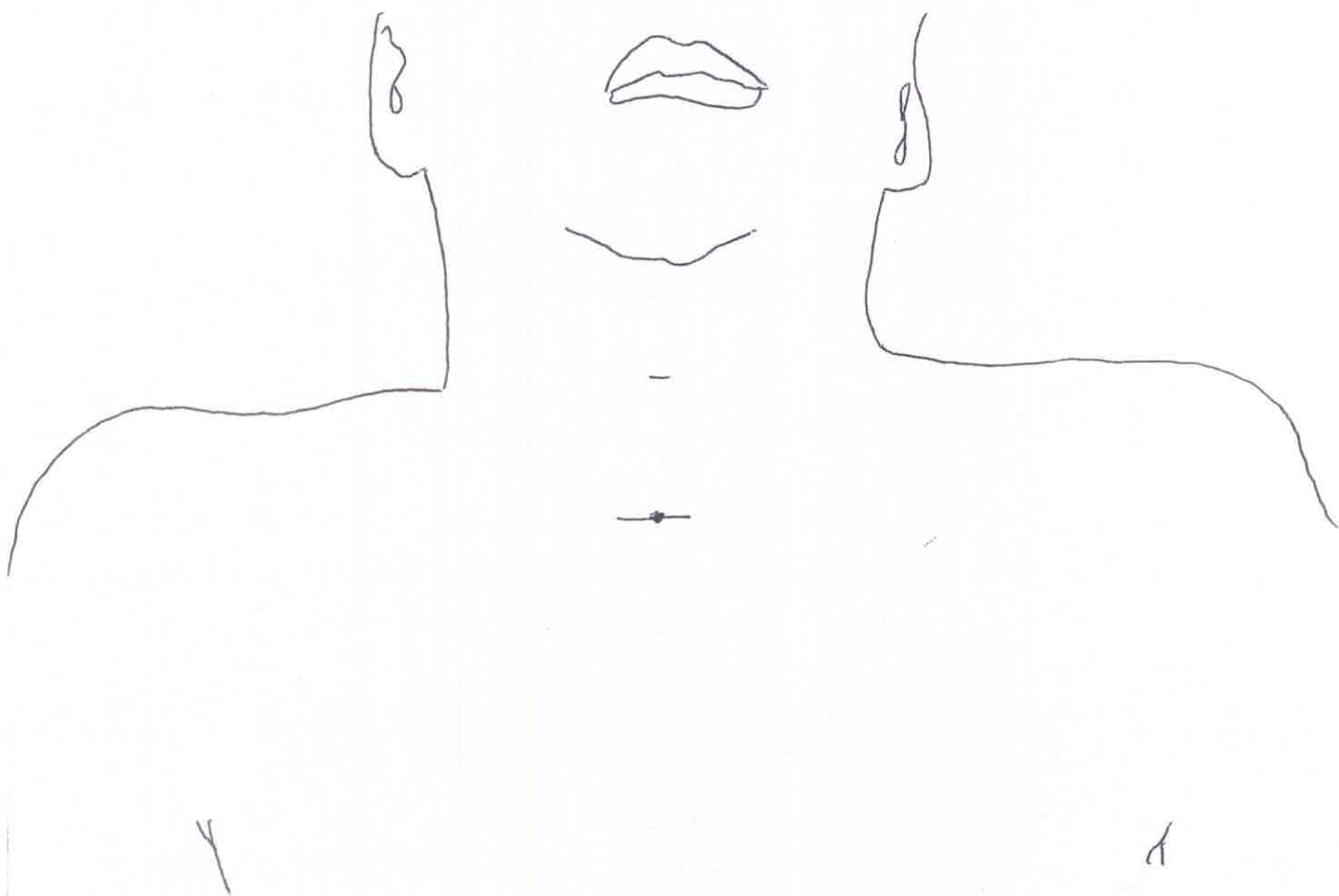
2 $\frac{3}{4}$ INCHES TO 2 $\frac{1}{2}$ INCHES (SIZE OF BASEBALL) AND SIZE OF MY FIST -
MORE OR LESS CIRCULAR - BONE AND HAIR GONE - CEREBELLUM
EXPOSED.



ENTRANCE WOUND TO THROAT

ANTERIOR LOWER THIRD OF THE NECK (TRACHEAL RING 2)-
SPHERICAL IN SHAPE WITH SHARP, SMOOTH MARGINS.

(4-6 mm IN SIZE, LESS THAN $\frac{1}{4}$ INCH)



ENTRANCE WOUND TO THROAT - (POST TRACHEOSTOMY)

POST TRACHEOSTOMY - BY DR. PERRY THROUGH THE ENTRANCE WOUND.
INCISION WAS SHARP, SMOOTH, APPROXIMATELY 1 TO 1 $\frac{3}{4}$ INCHES.
(INCISION EDGES WERE TOGETHER.)