

AFFIDAVIT OF DR. J. T. FRANCISCO


Now comes the affiant, after first being duly sworn and says as follows:

That he is Dr. J. T. Francisco and resides and is domiciled at 1196 Yorkshire, Memphis, Shelby County, Tennessee, United States of America; that he is employed by the University of Tennessee as a pathologist and by Shelby County, Tennessee, as Medical Examiner for Shelby County, Tennessee; that he is a duly licensed and practicing physician of the State of Tennessee and holds a Doctor of Medicine Degree from the University of Tennessee and has practiced medicine for thirteen years and has served as medical examiner for Shelby County, Tennessee, for seven years. That as part of his duties as medical examiner, he examines all violent, unusual, or unnatural deaths that occur within the County of Shelby, State of Tennessee, for purposes of discovering the cause of death and recommending autopsies upon such deaths investigated if he deems it necessary. During his seven years as medical examiner, affiant has examined approximately nine thousand bodies and performed approximately three thousand autopsies. Affiant is further certified by the American Board of Pathology in Anatomic, Clinical and Forensic Pathology. That affiant is forensic pathology consultant to the Chief Medical Examiner of the State of Tennessee. That on April 4, 1968, acting pursuant to his duties as medical examiner of Shelby County, Tennessee, and under order from the District Attorney General for the Fifteenth Judicial Circuit consisting of Shelby County, Tennessee, said District Attorney General being Phil M. Canale, Jr., and with the consent of Coretta Scott King, the widow of Dr. Martin Luther King, Jr., affiant performed an autopsy on the body of Dr. Martin Luther King, Jr., starting at approximately 2140 hours at the morgue of the University of Tennessee and John Gaston Morris reported in the Institute of Pathology at the University of Tennessee, 222 Madison Avenue, Memphis, Shelby County, Tennessee.

That during the examination and autopsy, affiant removed ^{a bullet} from beneath the skin in the region of the left scapula 56 inches superior to the right heel and 3 inches to the left of the midline of the spine, this being the termination point of a bullet that entered the right chin, passing through the chin and neck. That after removing the bullet, affiant physically marked the bullet by scratching the Autopsy No. 252 on the base thereof, and placed the same in plastic and enclosed the same in a Manila envelope, marking thereon and gave the same into the custody and gathering a written receipt from Lt. J. D. Hamby of the Memphis, Tennessee, Police Department. In accordance with the laws of the State of Tennessee, affiant did reduce the findings from the autopsy he performed upon the body of Dr. Martin Luther King, Jr., to writing in the form of an autopsy report bearing Case No. A68-252, did sign same under date of April 11, 1968, and filed said autopsy report with the Shelby County Medical Examiner, District Attorney General of the Fifteenth Judicial Circuit comprised by Shelby County, Tennessee, and with Chief Medical Examiner for the State of Tennessee. Affiant has examined a copy of the aforesaid autopsy report, which is attached and marked exhibit hereto, a certified and authenticated copy of which appears, is attached and is made by reference a part of the Governor's application for requisition, and certifies that it truly and accurately represents his findings in the autopsy of the body of Dr. Martin Luther King, Jr., and further certifies that it is a true and correct copy of the autopsy report filed with the Office of the Chief Medical Examiner for the State of Tennessee, Cordell Hull Office Building, Division of Post Mortem Examination, Office of Chief Medical Examiner, Nashville, Tennessee. That affiant has examined Certificate of Death, Tennessee Department of Public Health, Division of Vital Statistics, bearing File No. 2066, being a copy of the Certificate of Death on

Dr. Martin Luther King, Jr., ~~was~~ being attached and marked exhibit hereto, a certified and authenticated copy of which appears, is attached and is made by reference a part of the Governor's application for requisition, and does certify that it represents a true and correct copy of the original Certificate of Death on Dr. Martin Luther King, Jr., signed by affiant on April 5, 1968, giving the cause of death as gunshot wound to the thoracic cord. Affiant has examined survey report and plat, identified to affiant as being a drawing of the crime scene, said document bearing the notation in the lower right hand corner, Prepared by Arthur C. Holbrook, Memphis, Tennessee, April 13, 1968, Tenn. Cert. No. 5173, copy of said drawing being attached and made exhibit hereto, a certified and authenticated copy of which appears, is attached and is made by reference a part of the Governor's application for requisition, and affirms that the trajectory of a bullet traveling along the path as indicated in said drawing would be consistent with the entry of the bullet and subsequent course through the body of Dr. Martin Luther King, Jr.

Further affiant sayeth not.



DR. J. J. FRANCISCO, 1196 Yorkshire, Memphis, Shelby County, Tennessee, United States of America.

57

STATE OF TENNESSEE

COUNTY OF SHELBY

Before me J. A. Blackwell, Clerk of the Criminal Courts of Shelby County, Tennessee, being an officer constituted to take oaths, appeared DR. J. T. FRANCISCO, to me known personally and after being duly sworn, stated that the foregoing affidavit of three pages is true and correct to the best of his/~~her~~ knowledge, information, and belief. I hereby certify that this document is the ~~original~~ a true copy of the original affidavit of DR. J. T. FRANCISCO.

IN TESTIMONY WHEREOF I have hereunto set my hand and affixed the seal of said Court, at office, in the City of Memphis, this 10th day of June, 1968.

J. A. Blackwell
CLERK

STATE OF TENNESSEE

COUNTY OF SHELBY

I, Perry H. Sellers, sole and presiding Judge of the Criminal Court of said County Division I, certify that J. A. Blackwell, whose true and genuine signature appears above to the foregoing certificate, is now, and was at the time of signing the same, Clerk of said Court, and that said Court is a Court of Record; that his attestation is in due form, and his official acts, as such, are entitled to full faith and credit.

WITNESS my hand, this 10th day of June, 1968.

Perry H. Sellers
JUDGE

STATE OF TENNESSEE

COUNTY OF SHELBY

I, J. A. Blackwell, Clerk of the Criminal Courts of said County, certify that Honorable Perry H. Sellers, whose genuine official signature appears to the above and hereto annexed Certificate, is and was at the time of signing the same, sole and presiding Judge of the Criminal Court Division I, in and for the County and State aforesaid, duly commissioned and

qualified, and that all his official acts, as such, are entitled to full faith and credit.

IN TESTIMONY WHEREOF I have hereunto set my hand and affixed the seal of said Court, at office, in the City of Memphis this 10th day of June, 1968.

J. A. [Signature]

CLERK

57



CHARLES B. BLACKBURN
DIRECTOR
DIVISION OF PUBLIC WORKS

CITY OF MEMPHIS

MEMPHIS
TENNESSEE
3 8 2 0 5

APRIL 23, 1968

MR. FRANK E. HOLLOWAY, DIRECTOR
DIVISION OF FIRE & POLICE
CITY OF MEMPHIS
MEMPHIS, TENNESSEE

DEAR MR. HOLLOWAY:

PER YOUR REQUEST, DATED APRIL 22, 1968, THROUGH MR. CHARLES B. BLACKBURN, DIRECTOR, DIVISION OF PUBLIC WORKS, I WAS INSTRUCTED TO MAKE CERTAIN ENGINEERING MEASUREMENTS RELATIVE TO THE MURDER OF DR. MARTIN LUTHER KING. THESE MEASUREMENTS WERE TO BE FROM A POINT WHERE THE WEAPON WAS FIRED TO THE AREA WHERE DR. KING WAS STRUCK. THE MEASUREMENTS WERE TO BE TRIANGULATED.

THIS MORNING, APRIL 23, 1968, I AND SEVERAL ENGINEERING EMPLOYEES FROM THIS DEPARTMENT, MET WITH LTS. A. S. ZELINSKI AND J. L. HARRISON, OF THE POLICE DEPARTMENT, AT THE SCENE OF THE MURDER. THE MEASUREMENTS AND CALCULATIONS, HEREINAFTER DESCRIBED, WERE MADE BETWEEN 8:30 A. M. AND 10 A. M., THIS DATE.

I WAS SHOWN, BY LTS. ZELINSKI AND HARRISON, THE SPOT WHERE DR. KING WAS STANDING AND THE WINDOW FROM WHICH THE SHOT WAS FIRED AND THAT THE BULLET ENTERED DR. KING AT A POINT 59 INCHES ABOVE THE BALCONY FLOOR OF THE LORRAINE MOTEL, AND THAT THE GUN WAS RESTING ON A POINT ON A WINDOWSILL OF A BUILDING WHICH FRONTS ON SOUTH MAIN STREET AND ACROSS MULBERRY STREET FROM THE LORRAINE MOTEL.

AN ENGINEER'S TRANSIT WAS PLACED OVER THE SPOT WHERE DR. KING WAS SHOT. THE TELESCOPE BEING 59 INCHES FROM THE BALCONY FLOOR, AND THE INSTRUMENT WAS MADE LEVEL.

FROM THIS POSITION TWO TRIANGLES WERE ESTABLISHED, WITH A BASE LINE COMMON TO THE TWO TRIANGLES, ESTABLISHED AND MEASURED. ANGLES WERE TURNED, CHECKED, TURNED AGAIN, AND CHECKED AGAIN AND EVERY EFFORT WAS MADE TO PROVIDE FOR THE UTMOST ACCURACY OF THE CALCULATIONS.

THE LEVEL DISTANCE FROM THE POINT FROM WHICH THE SHOT WAS FIRED TO THE POINT WHERE DR. KING WAS STANDING IS 206.36 FEET. THE DISTANCE ALONG THE FLIGHT OF THE BULLET FROM THE POINT FROM WHICH IT WAS FIRED TO THE POINT WHERE DR. KING WAS STANDING IS 207.02 FEET.

Survey and Plot Exhibit to Dr. J. T. Ferguson

MRT FRANK C. HOLLOMAN, DIRECTOR OF FIRE & POLICE
APRIL 23, 1968
PAGE # 2

THE WINDOWSILL OF THE BUILDING FROM WHICH THE SHOT WAS FIRED IS 16.63 FEET HIGHER THAN A POINT 59 INCHES ABOVE THE FLOOR OF THE BALCONY ON WHICH DR. KING WAS STANDING WHEN SHOT.

IN ADDITION TO THE AFOREMENTIONED LTS. ZELINSKI AND HARRISON, THE FOLLOWING NAMED MEN FROM THIS DEPARTMENT WERE PRESENT AND ASSISTED IN THIS SURVEY, AND STATISTICS RELATIVE TO THESE MEN FURNISHED IN THE FOLLOWING ORDER: NAME, TITLE, AGE, LENGTH OF SERVICE WITH THIS DEPARTMENT, ADDRESS, AND HOME PHONE NUMBER.

ARTHUR C. HOLBROOK, ENGINEER OF SURVEYS, PLANS, & DESIGN; 52 YEARS OLD; 22 YEARS 5 MONTHS; 3730 SHIRLWOOD AVENUE; 323-8853.

ROBERT V. WENZLER; SENIOR PARTY CHIEF; 32; 15 YEARS 8 MONTHS; 4100 WARD AVENUE; 386-7766.

AARON RUSSELL; SENIOR PARTY CHIEF; 54; 28 YEARS 6 MONTHS; 2119 ALTA VISTA DRIVE; 357-3819.

BILLY FITE; INSTRUMENTMAN; 35; 11 YEARS; 2208 CASSIE AVENUE; 357-4522.

JOE TIDWELL, ENGINEERING AIDE; 21; 1 YEAR 7 MONTHS; 1992 DRIFTWOOD AVENUE; 357-3804.

THOMAS BOILLOT; ENGINEERING AIDE; 24; 7 MONTHS; 2085 LINDEN AVENUE; 278-0504.

CHARLES BROOKS; ENGINEERING AIDE; 18; 5 MONTHS; 4608 MCCRORY AVENUE; 685-1223.

I HAVE ATTACHED A SKETCH SHOWING THE TRIANGULATION AS SET UP AT THE SCENE, WITH ANGLES, MEASUREMENTS, AND CALCULATIONS ALSO SHOWN.

IF WE CAN HELP FURTHER IN THIS MATTER, PLEASE ADVISE.

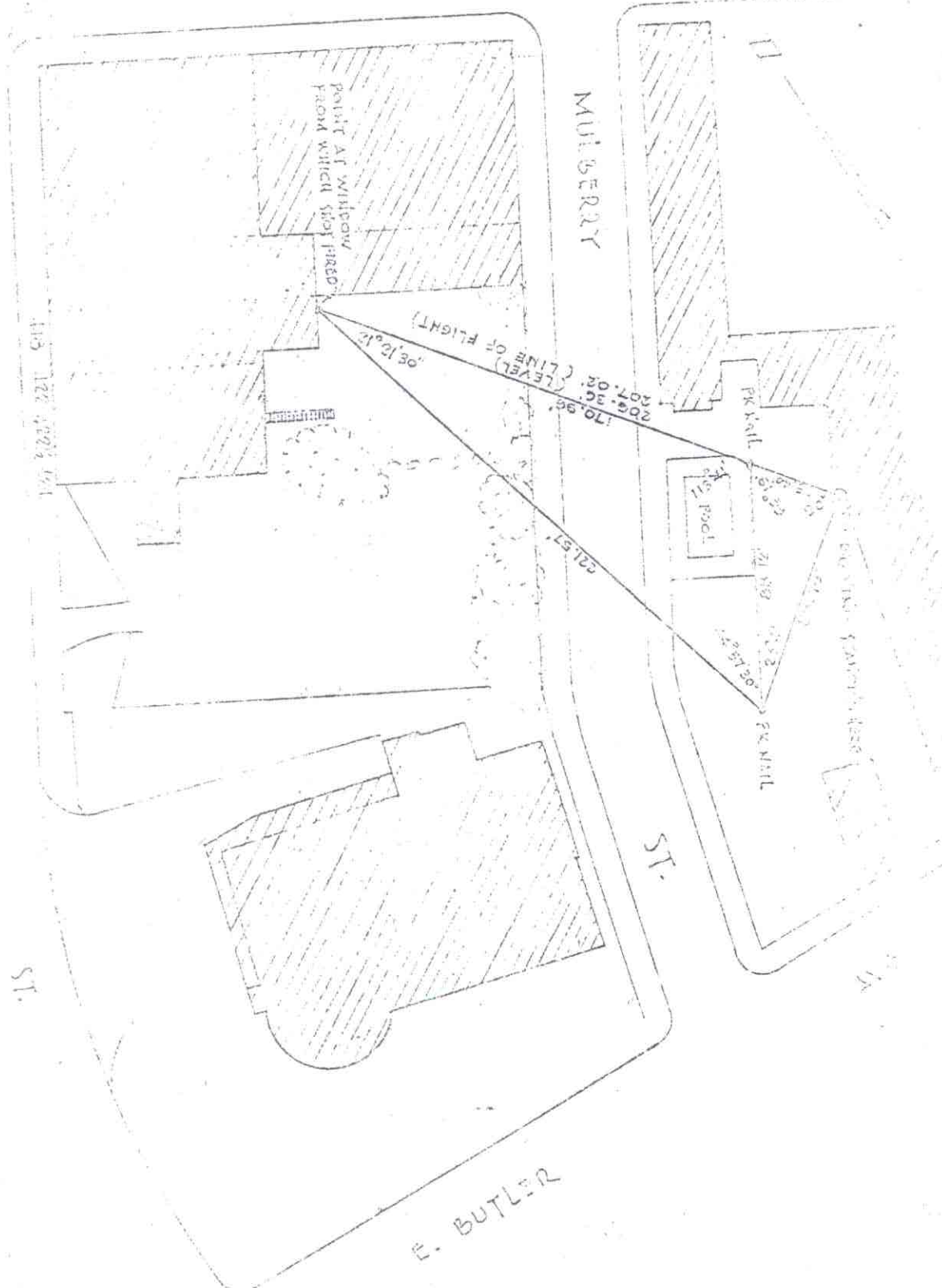
SINCERELY,



ARTHUR C. HOLBROOK, P.E.
ENGINEER OF SURVEYS, PLANS & DESIGN
TENNESSEE LICENSE NO. 5173

ACH:DT
ATTACHED

Survey and Plat Exhibit to Dr. J.T. FRANCISCO



Survey and Plat Exhibit to
 DR. J. T. FRANCISCO

PREPARED BY
 ARTHUR W. HOLLAND
 MEMPHIS, TENN.
 APRIL 23 1936

CERTIFICATE OF DEATH
 TENNESSEE DEPARTMENT OF PUBLIC HEALTH
 DIVISION OF VITAL STATISTICS

FILE NO. **2066**

MEMPHIS AND SHELBY COUNTY HEALTH DEPARTMENT

This is NOT a certified copy of the original certificate on file in the Tennessee Department of Public Health, Nashville. It is a reproduction of a copy made in this office before the original was transmitted to the state office for filing.
 Legal fee \$1.00 per copy

Date Issued June 10, 1968

Eugene W. Fowlkley, M.D., Registrar
 Division of Vital Records

by [Signature]
 Sue Lacey, Deputy Registrar

Death Certificate of Martin Luther King, Jr.

1. DECEASED - NAME Martin Luther King, Jr.		DATE OF DEATH (MONTH, DAY, YEAR) 4-4-68	
2. SEX Male		DATE OF BIRTH (MONTH, DAY, YEAR) 1-15-24	
3. COUNTY OF DEATH Shelby		HOSPITAL OR OTHER INSTITUTION - NAME St. Joseph Hospital	
4. CITIZENSHIP Georgia		SURVIVING SPOUSE (IF WIFE, GIVE MARRIAGE DATE) Coretta King (nee Scott)	
5. STATE OF BIRTH (IF BORN IN U.S.) Georgia		KIND OF BUSINESS OR INDUSTRY So. Christian Leadership Conference	
6. SOCIAL SECURITY NUMBER 253-36-3980		STREET AND NUMBER 16, 234 Sunset N.W.	
7. RESIDENCE - STATE Georgia		MAILING ADDRESS Atlanta, Ga.	
8. FATHER - NAME Fulton		MOTHER - MARRIAGE NAME Alberta Williams	
9. MOTHER - MARRIAGE NAME Alberta Williams		CITY, TOWN, OR LOCATION Atlanta	
10. MARRIAGE DATE 10, Married		INFORMANT - NAME Coretta King	
11. CITIZENSHIP Georgia		CITY, TOWN, OR LOCATION Atlanta	
12. MARRIAGE DATE 10, Married		CITY, TOWN, OR LOCATION Atlanta	
13. MARRIAGE DATE 10, Married		CITY, TOWN, OR LOCATION Atlanta	
14. MARRIAGE DATE 10, Married		CITY, TOWN, OR LOCATION Atlanta	
15. MARRIAGE DATE 10, Married		CITY, TOWN, OR LOCATION Atlanta	
16. MARRIAGE DATE 10, Married		CITY, TOWN, OR LOCATION Atlanta	
17. MARRIAGE DATE 10, Married		CITY, TOWN, OR LOCATION Atlanta	
18. MARRIAGE DATE 10, Married		CITY, TOWN, OR LOCATION Atlanta	
19. MARRIAGE DATE 10, Married		CITY, TOWN, OR LOCATION Atlanta	
20. MARRIAGE DATE 10, Married		CITY, TOWN, OR LOCATION Atlanta	
21. MARRIAGE DATE 10, Married		CITY, TOWN, OR LOCATION Atlanta	
22. MARRIAGE DATE 10, Married		CITY, TOWN, OR LOCATION Atlanta	
23. MARRIAGE DATE 10, Married		CITY, TOWN, OR LOCATION Atlanta	
24. MARRIAGE DATE 10, Married		CITY, TOWN, OR LOCATION Atlanta	
25. MARRIAGE DATE 10, Married		CITY, TOWN, OR LOCATION Atlanta	
26. MARRIAGE DATE 10, Married		CITY, TOWN, OR LOCATION Atlanta	
27. MARRIAGE DATE 10, Married		CITY, TOWN, OR LOCATION Atlanta	
28. MARRIAGE DATE 10, Married		CITY, TOWN, OR LOCATION Atlanta	
29. MARRIAGE DATE 10, Married		CITY, TOWN, OR LOCATION Atlanta	
30. MARRIAGE DATE 10, Married		CITY, TOWN, OR LOCATION Atlanta	
31. MARRIAGE DATE 10, Married		CITY, TOWN, OR LOCATION Atlanta	
32. MARRIAGE DATE 10, Married		CITY, TOWN, OR LOCATION Atlanta	
33. MARRIAGE DATE 10, Married		CITY, TOWN, OR LOCATION Atlanta	
34. MARRIAGE DATE 10, Married		CITY, TOWN, OR LOCATION Atlanta	
35. MARRIAGE DATE 10, Married		CITY, TOWN, OR LOCATION Atlanta	
36. MARRIAGE DATE 10, Married		CITY, TOWN, OR LOCATION Atlanta	
37. MARRIAGE DATE 10, Married		CITY, TOWN, OR LOCATION Atlanta	
38. MARRIAGE DATE 10, Married		CITY, TOWN, OR LOCATION Atlanta	
39. MARRIAGE DATE 10, Married		CITY, TOWN, OR LOCATION Atlanta	
40. MARRIAGE DATE 10, Married		CITY, TOWN, OR LOCATION Atlanta	
41. MARRIAGE DATE 10, Married		CITY, TOWN, OR LOCATION Atlanta	
42. MARRIAGE DATE 10, Married		CITY, TOWN, OR LOCATION Atlanta	
43. MARRIAGE DATE 10, Married		CITY, TOWN, OR LOCATION Atlanta	
44. MARRIAGE DATE 10, Married		CITY, TOWN, OR LOCATION Atlanta	
45. MARRIAGE DATE 10, Married		CITY, TOWN, OR LOCATION Atlanta	
46. MARRIAGE DATE 10, Married		CITY, TOWN, OR LOCATION Atlanta	
47. MARRIAGE DATE 10, Married		CITY, TOWN, OR LOCATION Atlanta	
48. MARRIAGE DATE 10, Married		CITY, TOWN, OR LOCATION Atlanta	
49. MARRIAGE DATE 10, Married		CITY, TOWN, OR LOCATION Atlanta	
50. MARRIAGE DATE 10, Married		CITY, TOWN, OR LOCATION Atlanta	
51. MARRIAGE DATE 10, Married		CITY, TOWN, OR LOCATION Atlanta	
52. MARRIAGE DATE 10, Married		CITY, TOWN, OR LOCATION Atlanta	
53. MARRIAGE DATE 10, Married		CITY, TOWN, OR LOCATION Atlanta	
54. MARRIAGE DATE 10, Married		CITY, TOWN, OR LOCATION Atlanta	
55. MARRIAGE DATE 10, Married		CITY, TOWN, OR LOCATION Atlanta	
56. MARRIAGE DATE 10, Married		CITY, TOWN, OR LOCATION Atlanta	
57. MARRIAGE DATE 10, Married		CITY, TOWN, OR LOCATION Atlanta	
58. MARRIAGE DATE 10, Married		CITY, TOWN, OR LOCATION Atlanta	
59. MARRIAGE DATE 10, Married		CITY, TOWN, OR LOCATION Atlanta	
60. MARRIAGE DATE 10, Married		CITY, TOWN, OR LOCATION Atlanta	
61. MARRIAGE DATE 10, Married		CITY, TOWN, OR LOCATION Atlanta	
62. MARRIAGE DATE 10, Married		CITY, TOWN, OR LOCATION Atlanta	
63. MARRIAGE DATE 10, Married		CITY, TOWN, OR LOCATION Atlanta	
64. MARRIAGE DATE 10, Married		CITY, TOWN, OR LOCATION Atlanta	
65. MARRIAGE DATE 10, Married		CITY, TOWN, OR LOCATION Atlanta	
66. MARRIAGE DATE 10, Married		CITY, TOWN, OR LOCATION Atlanta	
67. MARRIAGE DATE 10, Married		CITY, TOWN, OR LOCATION Atlanta	
68. MARRIAGE DATE 10, Married		CITY, TOWN, OR LOCATION Atlanta	
69. MARRIAGE DATE 10, Married		CITY, TOWN, OR LOCATION Atlanta	
70. MARRIAGE DATE 10, Married		CITY, TOWN, OR LOCATION Atlanta	
71. MARRIAGE DATE 10, Married		CITY, TOWN, OR LOCATION Atlanta	
72. MARRIAGE DATE 10, Married		CITY, TOWN, OR LOCATION Atlanta	
73. MARRIAGE DATE 10, Married		CITY, TOWN, OR LOCATION Atlanta	
74. MARRIAGE DATE 10, Married		CITY, TOWN, OR LOCATION Atlanta	
75. MARRIAGE DATE 10, Married		CITY, TOWN, OR LOCATION Atlanta	
76. MARRIAGE DATE 10, Married		CITY, TOWN, OR LOCATION Atlanta	
77. MARRIAGE DATE 10, Married		CITY, TOWN, OR LOCATION Atlanta	
78. MARRIAGE DATE 10, Married		CITY, TOWN, OR LOCATION Atlanta	
79. MARRIAGE DATE 10, Married		CITY, TOWN, OR LOCATION Atlanta	
80. MARRIAGE DATE 10, Married		CITY, TOWN, OR LOCATION Atlanta	
81. MARRIAGE DATE 10, Married		CITY, TOWN, OR LOCATION Atlanta	
82. MARRIAGE DATE 10, Married		CITY, TOWN, OR LOCATION Atlanta	
83. MARRIAGE DATE 10, Married		CITY, TOWN, OR LOCATION Atlanta	
84. MARRIAGE DATE 10, Married		CITY, TOWN, OR LOCATION Atlanta	
85. MARRIAGE DATE 10, Married		CITY, TOWN, OR LOCATION Atlanta	
86. MARRIAGE DATE 10, Married		CITY, TOWN, OR LOCATION Atlanta	
87. MARRIAGE DATE 10, Married		CITY, TOWN, OR LOCATION Atlanta	
88. MARRIAGE DATE 10, Married		CITY, TOWN, OR LOCATION Atlanta	
89. MARRIAGE DATE 10, Married		CITY, TOWN, OR LOCATION Atlanta	
90. MARRIAGE DATE 10, Married		CITY, TOWN, OR LOCATION Atlanta	
91. MARRIAGE DATE 10, Married		CITY, TOWN, OR LOCATION Atlanta	
92. MARRIAGE DATE 10, Married		CITY, TOWN, OR LOCATION Atlanta	
93. MARRIAGE DATE 10, Married		CITY, TOWN, OR LOCATION Atlanta	
94. MARRIAGE DATE 10, Married		CITY, TOWN, OR LOCATION Atlanta	
95. MARRIAGE DATE 10, Married		CITY, TOWN, OR LOCATION Atlanta	
96. MARRIAGE DATE 10, Married		CITY, TOWN, OR LOCATION Atlanta	
97. MARRIAGE DATE 10, Married		CITY, TOWN, OR LOCATION Atlanta	
98. MARRIAGE DATE 10, Married		CITY, TOWN, OR LOCATION Atlanta	
99. MARRIAGE DATE 10, Married		CITY, TOWN, OR LOCATION Atlanta	
100. MARRIAGE DATE 10, Married		CITY, TOWN, OR LOCATION Atlanta	

814 JEFFERSON AVENUE, MEMPHIS, TENNESSEE 38105

Eugene W. Fowlkley, M.D., Registrar
 Division of Vital Records

by [Signature]
 Sue Lacey, Deputy Registrar

Death Certificate of Martin Luther King, Jr.

PRELIMINARY ()
FINAL (X)

MISSISSIPPI DEPARTMENT OF PUBLIC HEALTH
OFFICE OF THE CHIEF MEDICAL EXAMINER
238 Madison Avenue
Memphis, Tennessee 38103

CASE NO. 468-252
COUNTY Shelby

AUTOPSY REPORT

NAME OF DECEDENT Walter Kane, Jr. RACE N SEX M AGE 39

HOME ADDRESS Atlanta, Georgia CITY OF TOWN STATE

COUNTY MEDICAL EXAMINER J. T. Francisco, M.D.
ADDRESS Memphis, Tennessee

DISTRICT ATTORNEY GENERAL Phil A. Canale
ADDRESS Memphis, Tennessee

DIAGNOSIS: Gunshot wound to body and face with:
Fracture of mandible
Laceration vertebral artery, jugular vein and sub-
clavian artery, right,
Laceration of spinal cord (lower cervical, upper
thoracic),
Intrapulmonary hematoma, apex, right upper lobe

CAUSE OF DEATH Gunshot wound to spinal column, lower cervical, upper
thoracic

NARRATIVE OF FINDINGS Death was the result of a gunshot wound to the
chin and neck with a total transection of the lower cervical and
upper thoracic spinal cord and other structures in the neck. The
direction of the wounding was from front to back, above downward ar
from right to left. The severing of the spinal cord at this level
and to this extent was a wound that was fatal very shortly after its
occurrence.

The purpose of this report is to provide a certified opinion to the County Medical Examiner and the District Attorney General. The facts and findings to support these conclusions are filed with the office of the State Medical Examiner.

DATE April 11, 1968 SIGNATURE: [Signature] M.D.
ADDRESS 858 Madison Avenue-Memphis, Tennessee

*Consists of Exhibit to Dr. J. T. Francisco
consisting of eleven (11) pages*

THE CITY OF MEMPHIS HOSPITALS
AUTOPSY PROTOCOL

Autopsy No. A68-252 Service Med. Ex. Hospital No. _____
 Name Martin Luther King, Jr. Age 39 Race Negro Sex Male
 Date of Admission DOA Date and Hour of Death 4-4-68 P.M.
 Date and Hour of Autopsy 4-4-68 10:45 P.M.
 Pathologist Drs. Serant and Francisco Assistant _____
 Checked by _____ Date Completed 4-11-68

FINAL PATHOLOGICAL DIAGNOSIS

PRIMARY SERIES:

- I. Distant gunshot wound to body and face
 - A. Fracture of right mandible
 - B. Laceration of vertebral artery, jugular vein and subclavian artery, right
 - C. Fracture of spine (T-1, C-7)
 - D. Laceration of spinal cord (lower cervical, upper thoracic)
 - E. Submucosal hemorrhage, larynx
 - F. Intrapulmonary hematoma, apex right upper lobe

SECONDARY SERIES:

- 1. Remote scars as described
- 2. Pleural adhesions
- 3. Fatty change liver, moderate
- 4. Arteriosclerosis, moderate
- 5. Venous cut-downs
- 6. Tracheostomy

LABORATORY FINDINGS:

Blood Alcohol - 0.01%

EXTERNAL EXAMINATION OF THE BODY

This is a well developed, well nourished Negro male measuring 69 1/2 inches in length and weighing approximately 145 pounds. The hair is black, the eyes are black, there is a thin mustache present.

EXTERNAL MARKS AND SCARS

There is a remote scar present in the center of the chest and a remote scar extending to the right axilla measuring 8 inches in length. There is a sutured vertical surgical incision present at the base of the neck. A sutured incision is present in the right chest at the anterior axillary line. Three needle punctures are present in the precordium, there is no hemorrhage present surrounding the area. There are blood splatters present on the palm and dorsum of the right hand. A remote scar is present in the right lateral chest. Sutured incisions are present in the left ante cubital fossa, one that is obliquely directed measuring 2 inches in length, one that is horizontally directed measuring 1 inch in length. There are two sutured incisions present on the medial aspect of the left ankle. The superior incision measuring 2 inches in length, the inferior incision measuring 1/4 inch in length. There is an extensive excavating lesion affecting the right side of the face beginning at a point 1 inch lateral to the right corner of the mouth and 1/2 inch inferior to the right corner of the mouth that measures approximately 3 inches in length. At the superior aspect of this gaping wound there is an abrasion collar that measures 1/8 of an inch in maximum thickness, having brownish discoloration present at the superior margin. Adjacent to this area there is extensive laceration of the soft tissues of the face with a fracturing of the right side of the mandible. A re-approximation of the tissues reveals the laceration to extend to the base of the neck and into the base of the neck with intervening skin unaffected in this area. The second penetrating wound at the base of the neck in the superior aspect of the chest measures 3 inches in length. The missile path is through the external jugular vein and vertebral artery. There is a penetration into the lateral aspect of the base of the neck into the upper thoracic and lower cervical cord - totally severing the lower cervical and upper thoracic cord passing through the spinal column at the level of C7 and T1 into the posterior aspect of the back. The bullet is removed from the posterior aspect of the back, 56 inches superior to the right heel and 55 1/2 inches superior to the left heel, 3 inches to the left of the midline of the spine in the medial aspect of the left scapula. The entrance wound is 61 1/2 inches superior to the right heel and 59 inches superior to the right heel with the head turned and positioned so that the wound in the face corresponds with the path of the missile into the neck and spine. The total thickness from the entrance wound to the posterior aspect of the back is 8 1/2 inches in thickness. The angle of the penetrating wound is approximately 45° from a sagittal plane at an angle from right to left inferiorly and anterior to posteriorly at about a 30° angle with a coronal plane.

SECTION

The abdominal panniculus measures an inch in maximum thickness. The skeletal muscles are red and fibillary. There is scarring present over the right anterior-superior chest with pleural adhesions present in this area.

continued.....

BODY

There is approximat
cavity and some subpleur
and the left in the per
pleural cavity.

present within the right thoracic
is present affecting the right
The missile did not enter the right

GROUP 1: 211-212 OF THE ORGANS

HEART:

Heart weighs 450 grams. The myocardium is pale brown. The valvular surfaces reveal no significant changes. There is focal yellowing of the subendocardial areas affecting the left aspect of the interventricular septum. The right ventricle measures 5cm. in maximum thickness. The left ventricle measures 20mm. in maximum thickness. The coronary ostia originate in normal position and have a normal distribution over the epicardial surface. There is minimal intimal proliferation present. Focal yellow plaquing is present in the ascending aspect of the aortic arch but ulceration is not present. There is no significant dilatation affecting the chambers of the heart.

AORTA:

Focal yellow plaques are present throughout the aorta but ulceration and calcification is not present. The great vessels originate normally. There is perivascular hemorrhage affecting the right carotid artery but no penetration of the wall. The right subclavian artery is lacerated.

ESOPHAGUS:

Partially digested food fragments are present throughout the esophagus.

TRACHEA:

Hemorrhagic mucoid material is present throughout the upper trachea.

LUNGS:

The right lung weighs 300 grams. The left lung weighs 325 grams. There is diffuse congestion, consolidation and hemorrhage affecting the right upper lobe of the lung. Frothy fluid is expressible from the sectioned surface. There is minimal wrinkling of the pleura diffusely throughout the pulmonary parenchyma.

BRAIN:

The brain weighs 1400 grams. There is some flattening of the gyri and narrowing of the sulci. The cerebral vessels are symmetrical. There is no subdural, epidural, or extradural hemorrhage present. There is no significant flattening throughout the cerebral vessels.

KIDNEYS:

The kidneys weigh 175 grams on the left and 150 grams on the right. The capsular surface is smooth. The parenchyma is of normal coloration. The cortical-medullary junction is prominent.

continued.....

PANCREAS:

The pancreatic parenchyma is well preserved. The lobular pattern is preserved. There is no fatty infiltration present. The parenchyma is yellowish-grey.

LARYNX:

There is diffuse hemorrhage present throughout the superior larynx along with submucosal hemorrhage that is present within the intra-laryngeal areas. There is a tracheostomy perforation that is superior to the thyroid penetrating to the right of the pyramidal lobe.

THYROID:

No significant changes.

SPLEEN:

The spleen weighs 80 grams. The capsule is wrinkled. There is no capsular thickening present. The follicles are not prominent.

STOMACH:

The stomach contains approximately 10cc. of partially digested food fragments. There is no ulceration present.

DUODENUM:

No significant changes.

GALLBLADDER:

The gallbladder contains approximately 5cc. of light green bile. No stones are present.

LIVER:

The liver weighs 1600 grams. The parenchyma is pale yellowish-brown. The lobular pattern is accentuated. The parenchyma is quite soft.

BLADDER:

There is approximately 25cc. of cloudy yellow urine present.

PROSTATE:

No significant gross abnormalities are present.

COLON:

The appendix is present. The colonic contents is normal.

SMALL INTESTINE:

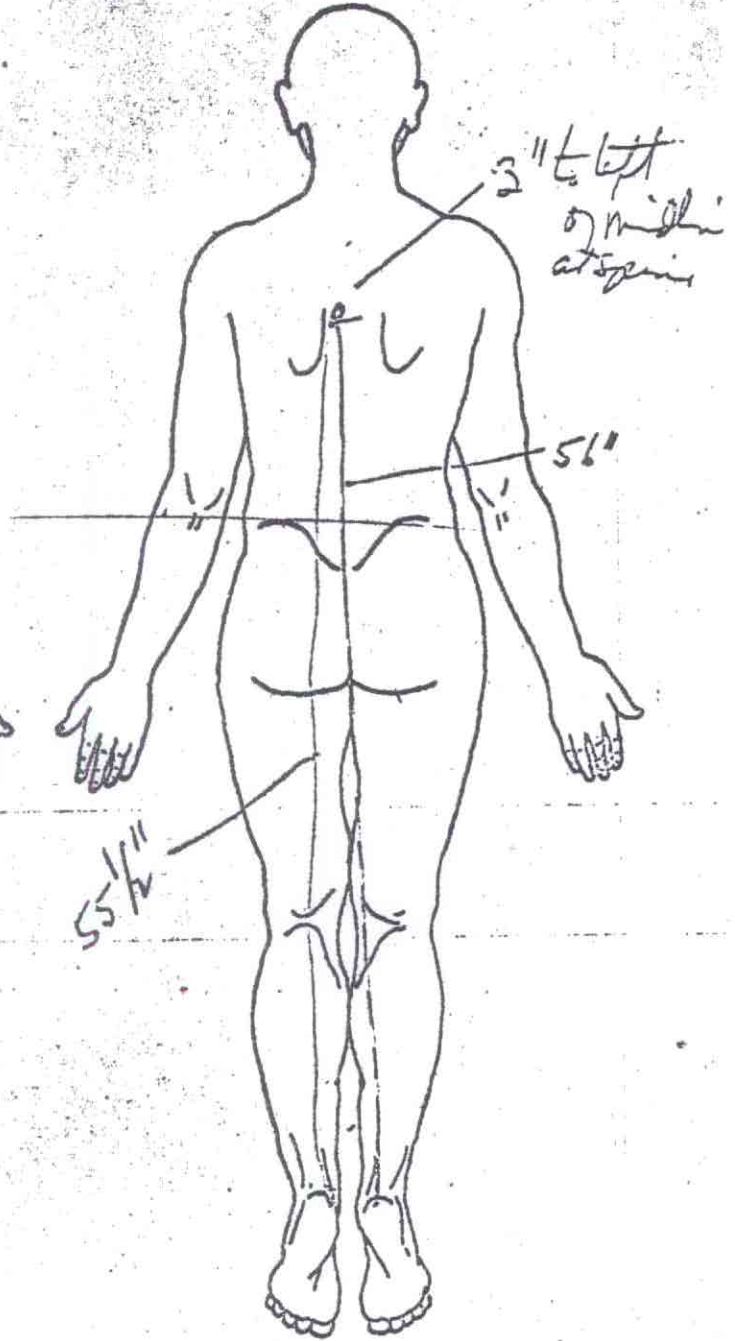
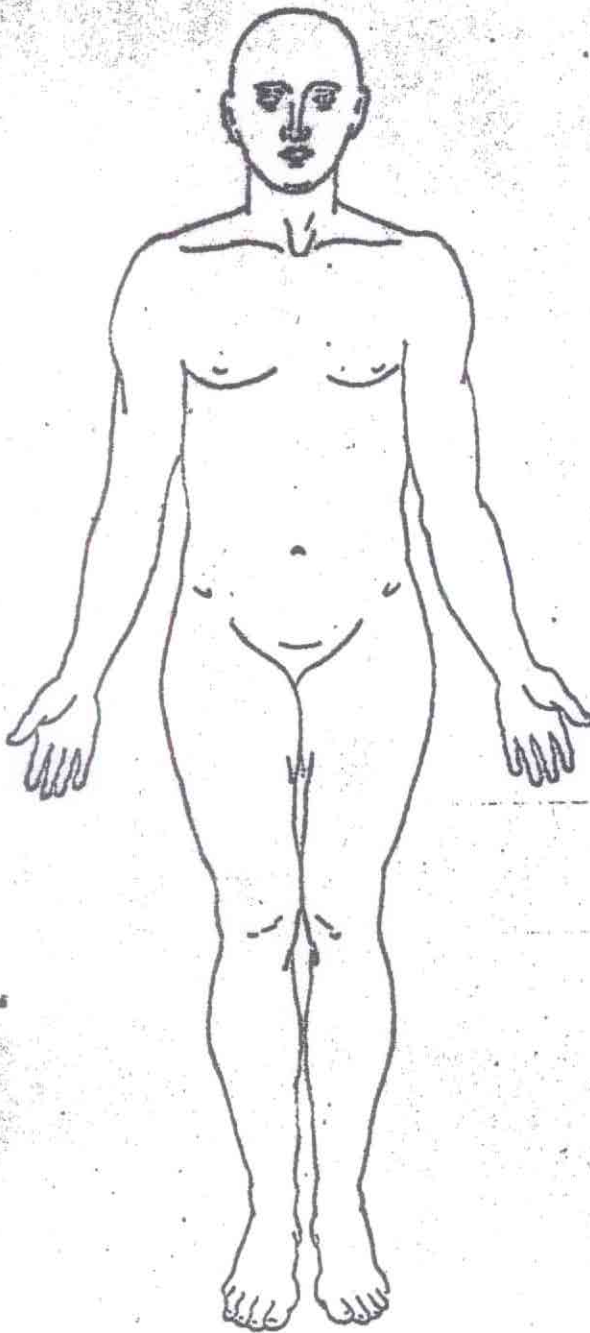
There is alternately liquid and gaseous distention present throughout the small intestine.

ADRENALS:

The adrenals are in normal position and weigh 8 grams together. The cortex is bright yellow. The medulla is grey.

Autopsy No. _____

#68-252

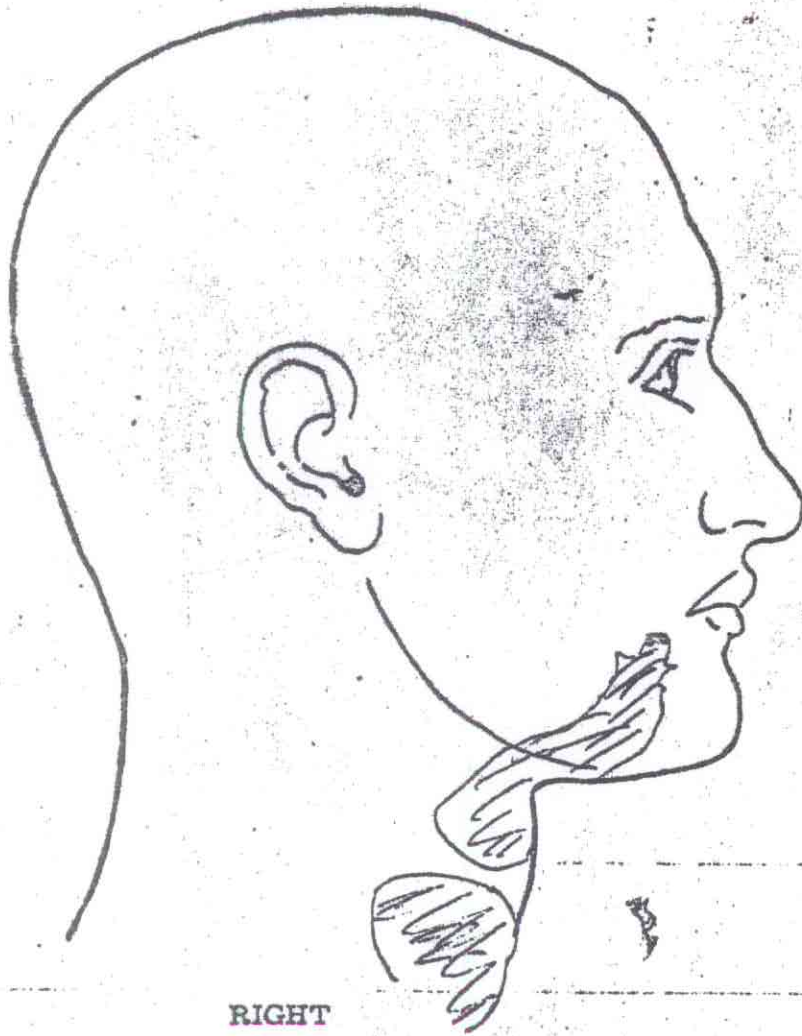


RIGHT HEAD

Special Chart 14

Autopsy No. _____

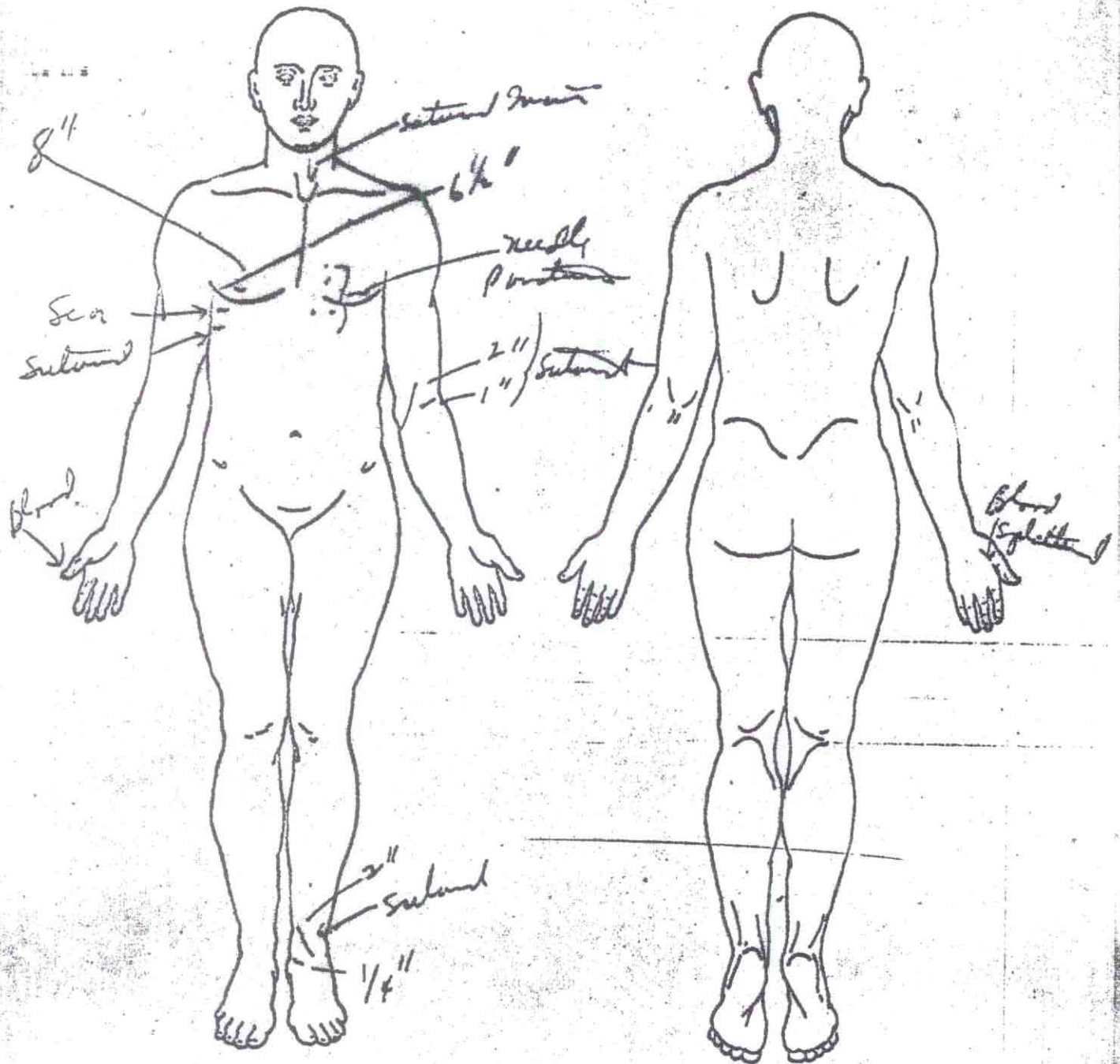
A68-252

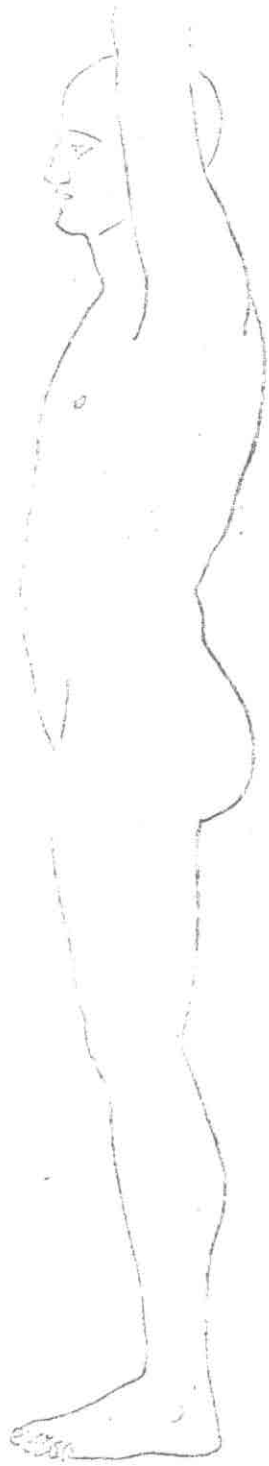

RIGHT

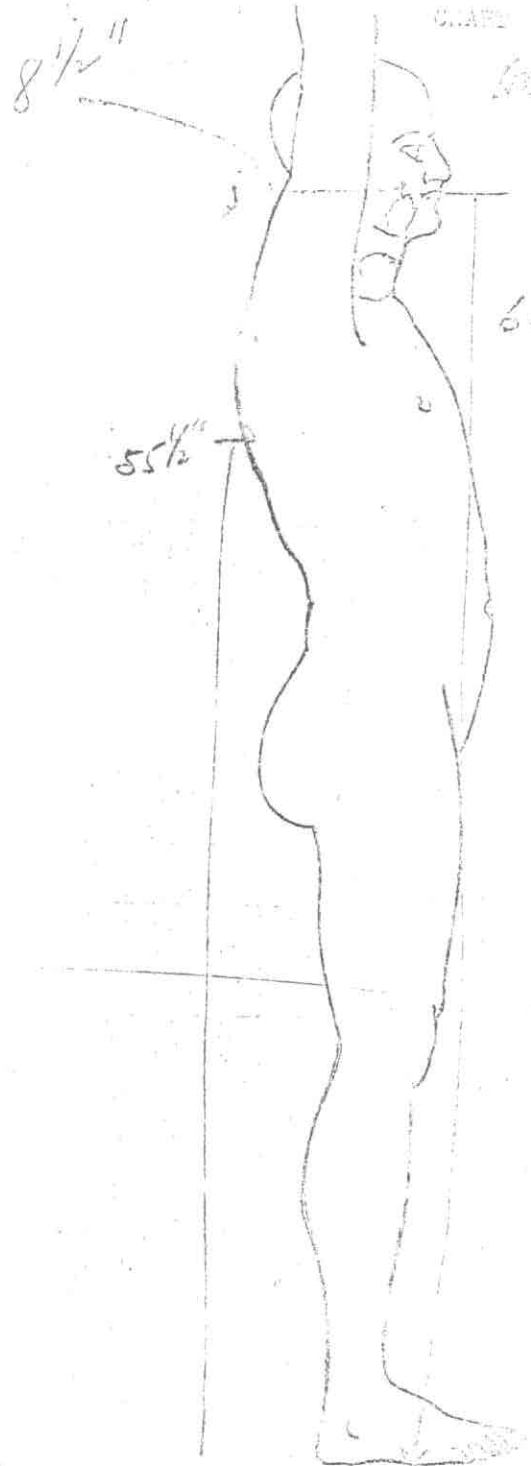
68

A68-252





LEFT



RIGHT

CLASS 2 17
100222

51 1/2"

55 1/2"

8 1/2"

MICROSCOPIC SUMMARY

- Focal areas of intra-alveolar hemorrhage are present throughout. Otherwise the alveoli are well preserved without hyperdistention or collapse. There is a loss of bronchial epithelium free within the lumens of the bronchioles. The pulmonary vessels reveal no significant changes.
- PANCREAS:** The pancreatic parenchyma is well preserved. The islets and acini are well preserved. There is minimal congestion present but no fibrosis or hemorrhage.
- KIDNEY:** The glomeruli and tubules are well preserved. There is no parenchymal fibrosis evident or vascular proliferation present. The tubules are filled with eosinophilic material. There is no collapse of the tubular lumen.
- THYROID:** The follicles are uniform and regular. There is a small quantity of extravasation of mature erythrocytes in peri-follicular locations. Cellular inflammatory reaction is not present. There is no margination of polymorphonuclear leucocytes within the areas of hemorrhage.
- LIVER:** There is diffuse cytoplasmic vacuolation throughout the hepatic cytoplasm being distributed throughout the lobules and in both pericentral and periportal locations. A small number of mononuclear cells are present in portal areas. There is some variation in size, shape of the hepatic nuclei. The vacuoles that are present are irregular in size, being numerous in some cells and being single large vacuoles in others with a disruption of cytoplasmic borders in some.
- ADRENAL:** There is congestion of the inner cortical zone of the adrenal. The cytoplasm is otherwise well maintained. The cortico-medullary ratio is maintained.
- SPLEEN:** The follicles are present but without secondary follicle centers. There is some congestion of the pulp. No hemorrhage is not present.
- HEART:** The myocardial fibers are well preserved. The nuclei are regular. Fibrosis is present in the myocardium and collagen. Inflammatory reaction is not present. The atrium reveals no significant changes.
- SKIN:** There is dermal hemorrhage present but no accumulation of polymorphonuclear leucocytes. Blackened clots are present throughout the hemorrhagic area of the dermis having no identifiable form. There is prominent eosinophilia of the collagen bundles. There is penetration into the dermal layers with an alteration of the structural properties of the epithelium-skin layer. A maturation of the epithelium adjacent to the site of the hemorrhage.

CORONARY:

There is moderate intimal proliferation along with an extra cellular deposition of lipid within the sub-intimal areas along with lipid filled macrophages present in this location. Small foci of perivascular mononuclear cells are present in the regions of most pronounced intimal proliferation.

PROSTATE:

The glandular elements are well preserved without any significant increase in collagenous connective tissue. Inflammatory reaction is not present.