

145769

date

cc. Schomer

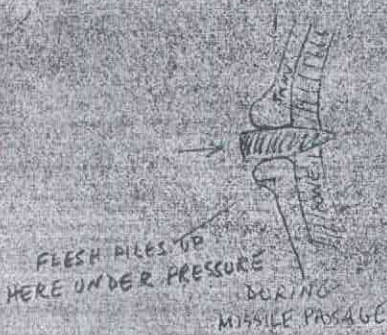
P.S. The following drawings illustrate why entrance wound in skin sometimes has characteristics of an exit wound when the skin in question is loosely attached over bone.

① PENETRATION INTO SKIN WHERE THERE IS NO UNDERLYING BONE



RESILIENT SKIN
MOVES INWARD WITH
THE MISSILE THEN
SNAPS BACK

② PENETRATION INTO SKIN WHERE THERE IS UNDERLYING BONE



PRESSURE BUILT UP IN THE
SKIN IS EXERTED OUTWARD,
SINCE BONE RESISTS MOVEMENT
OF SKIN INWARD