

J. A. M. A. - February 15, 1965

Suspicion of at least three Doctors, noted in J. A. M. A. February 15, 1965, that the Official Autopsy Report had omitted mention of the ADRENALS of President Kennedy - and the suspected ADDISON'S DISEASE.

Editor's note of unsuccessful inquiries of Officials regarding this information later admittedly omitted from the Official Autopsy Report.

 Letters

Steroids and Spontaneous Tendon Rupture

To the Editor:—In September, 1962, the author, a 39-year-old physician, ruptured his left Achilles tendon while playing competitive table tennis. It was presumed likely, because of the circumstances, that there was some relationship between the incident and the steroids which were being administered for eczematoid dermatitis. Steroids had been used for several months in doses of 20 to 40 mg of prednisone daily, with the development of severe Cushingoid manifestations. I implicate steroids because of the extensive metabolic aberrations that are known to occur and because the action that precipitated the rupture was seemingly innocuous.

An ordinary maneuver, springing forward, caused a complete severance of all the fibers of the Achilles tendon at the attachment to the calf muscles. There were no precipitating factors such as slippery floors or unusual twisting maneuvers, nor was this an initial match played under poor warm-up conditions. It was a typical action performed countless times in 30 years of continual competitive and professional participation in table tennis.

The diagnosis was immediately apparent. A surgeon was alerted and the surgical repair was performed the same night. The rupture was complete at the calf, no connections remaining. The plantaris was also ruptured. The condition was painful, but complete recovery occurred eventually, permitting full participation in competitive tennis and table tennis.

Just recently there appeared a Letter to the Editor¹ describing a similar event and referring to four others, one of which² involved a rupture of the Achilles tendon that occurred when the patient stood on his toes at the request of the physician, who wished to check on the chronic rupture that had occurred four months previously. These reports all described Achilles ruptures, some bilateral, all of which occurred in patients taking large

doses of steroids, and, in two instances, in patients with systemic lupus erythematosus. It was deemed possible that the relationship was to lupus rather than to the accompanying steroids. With the account of the incident herein described, however, it seems reasonably certain that the rupture was in fact due to the steroids alone and their complicated actions. This is another bizarre side effect of steroids.

— PETER FISHER, MD
Seattle

1. Sylbert, P.: Steroids and Spontaneous Tendon Rupture, *Lettsess, JAMA* 190:475 [Nov 2] 1964.
2. Small, G.G.: Bilateral Rupture of Achilles Tendons, *Brit Med J* 1:1687 (June 10) 1961.

Od's Bodikins

To the Editor:—Your recent communications on Hodgkin's disease (*JAMA* 190:910 [Dec 7] 1964) have inspired the following immortal lines:

Od's bodikins!
Cried Hodgkin,
Here is a canker
Worse than a chancre.

By the 23rd Psalm
As I'm Hodgkin, Tom,
We cannot endure it,
Somebody must cure it!

BERNARD STRAUSS, MD
New York

Official Autopsy Report on President Kennedy

To the Editor:—After reading the "Official Autopsy Report on President Kennedy" (FROM OTHER PAGES, *JAMA* 190, Oct 26, 1964, adv p 98) I wonder if this represents the complete autopsy protocol? It seems to be the complete report submitted, but it certainly would appear to be a grossly incomplete record. The forensic pathologist prides himself on his thoroughness in the positive findings, in the pertinent negative findings, and in the recording of other normal and abnormal findings that may be totally unrelated to the cause and mode of death. For instance, this "complete" record with its supplementary report fails to mention what the gross findings were with regard to such obvious and easily identifiable organs as the liver, spleen, kidneys, pancreas, thyroid, and adrenals. Some of these organs must have been found for they are mentioned under the section heading, "Microscopic Ex-

amination." Others apparently were not found, for no mention is made of them. A good autopsy protocol states, "Such and such an organ was not found or not examined." This one, however, leaves it up to guessing.

One can only assume from the report that a pair of organs we all would be most interested in knowing about was too difficult to find, namely, the adrenals. Such a pity to have been so close to the answer to a medical query much talked about both by lay and professional people before, during, and after the administration of President John F. Kennedy and not to have found even a smidgen of adrenal tissue to answer this perplexing, curious, and intriguing problem.

R. M. FAILING, MD
Santa Barbara, Calif

To the Editor:—Inasmuch as there was some controversy about the President and Addison's disease, I imagine you may have had many inquiries concerning the adrenals. Were there any abnormalities in the adrenals?

PAUL W. HUGHES, MD
Fort Lauderdale, Fla

To the Editor:—What became of President Kennedy's adrenals? No mention was made of them in any publication I have seen of the official autopsy report.

Capt THOMAS H. McCONNELL, MC, USA
Fort Campbell, Ky

✓ *Inquiries to the officials on this point have been unsuccessful.*—ED.

Lymphangioma and Arthus' Phenomenon

To the Editor:—Arthus' phenomenon, the local necrosis of tissue after injection of antigen in a sensitized animal, has been used to slough implanted tumors in experimental animals. Because I have had cases of extensive hemangiomas that have sloughed and regressed after partial excision, it occurred to me that the partial excision might have released an antigen that precipitated the process, which itself was perhaps an expression of the auto-immune disease process, destruction of seemingly normal tissue by the immune reaction. I have not had a non-resectable hemangioma on which I could try my thesis. I have had, however, two cases with extensive lymphangioma-hemangioma in which total excision was out

**MANAGEMENT OF ADRENOCORTICAL INSUFFICIENCY DURING
SURGERY**

A. M. A. ARCHIVES OF SURGERY
November, 1955

(Accepted for publication July 28, 1955.
Read at A. M. A. meeting, Atlantic
City, 6/8/55, 6 pp. - 737 through 742)

This is the article in the November, 1955 ARCHIVES OF SURGERY,
in which J. F. K. 's surgeon, Dr. James A. Nicholas, describes his
preparations for an "ADDISONIAN CRISIS" in an unnamed 37-year-
old man who underwent spinal surgery at Manhattan's Hospital for
Special Surgery on October 21, 1954 - the same day and the
same hospital where 37-year-old John F. Kennedy underwent the
same operation.

Management of Adrenocortical Insufficiency During Surgery

JAMES A. NICHOLAS, M.D.
CHARLES L. BURSTEIN, M.D.
CHARLES J. UMBERGER, Ph.D.
and
PHILIP D. WILSON, M.D., New York

Adrenocortical insufficiency, known to be present in patients with Addison's disease and in patients who have had bilateral adrenalectomy, may also be induced in patients who have been receiving therapy with cortisone or other corticosteroids. The possibility of death following surgical intervention in such persons has been pointed out.* This is particularly apt to occur in cases where emergencies require surgery to be performed without benefit of prior work-up and preparation.

We wish to describe our experiences in the management of three patients with adrenocortical insufficiency, each with a different problem, who required surgical intervention. We have had six patients with hypoadrenalism at the Hospital for Special Surgery in the past two years who required surgery; hence, it is by no means a rare problem. Five of the six patients had cortisone-induced cases of hypoadrenalism. All were prepared for surgery but one, and in only one who required emergency surgery did death occur.

Accepted for publication July 28, 1955.

From the Laboratory of Surgical Research and Anesthesiology, the Hospital for Special Surgery, Cornell University Medical College.

Read in the Symposium on New Agents and Methods for Analgesia and Anesthesia before the Section on Anesthesiology at the 104th Annual Meeting of the American Medical Association, Atlantic City, N. J., June 8, 1955.

* References 1, 2, 3, and 4.

The data on three of these patients are being presented in this paper to illustrate the methods whereby we managed the problems.

One patient had been receiving intensive hydrocortisone therapy for rheumatoid arthritis when he developed acute appendicitis. A second patient had suppressed adrenocortical function produced by cortisone therapy for pemphigus, and he required an elective femoral replacement arthroplasty of the hip. A third patient had known Addison's disease and needed spinal and sacroiliac fusions. Each of these patients presented different problems in the management of their adrenocortical deficiency. The successful results obtained in all but one case were due mainly to the extended metabolic work-up prior to, during, and after surgery. The scale of trauma in the surgery of these cases is very intense.

REPORT OF CASES

CASE 1.—*Example of Hydrocortisone-Induced Adrenocortical Insufficiency Requiring Emergency Surgery*

A man 47 years of age entered the clinic for rheumatic diseases of the Hospital for Special Surgery in 1940 because of rheumatoid arthritis involving the neck, shoulders, wrists, and knees. Gold therapy was started but was discontinued because it produced severe dermatitis. On Aug. 14, 1949, he was given 25 mg. of corticotropin (ACTH) by intramuscular injection, which resulted in good relief of his pains with diminution of his stiffness. Therefore, he was started on corticotropin therapy of 50 mg. twice a day. In January, 1950, his treatment was changed to desoxycorticosterone acetate (DCA) in 5 mg. doses on alternate days, combined with ascorbic acid. In November, 1951, his treatment was changed to hydrocortisone with phenylbutazone. This was maintained thereafter on low dosage. Despite this, he gained weight and developed some facial edema at times.

On Nov. 7, 1954, the patient was brought to the hospital in acute distress due to appendicitis. Ap-

pendectomy with drainage of a retrocecal abscess was performed during cyclopropane anesthesia. Preoperatively he was given an infusion of 1000 cc. of 5% dextrose in water. During the operation, intravenous therapy was continued with 250 cc. saline and 500 cc. of blood because the patient's hemoglobin was 11.4 gm. per 100 cc. of blood. All other vital signs were within normal limits. During the operation his arterial blood pressure, pulse rate, and respiratory rate remained normal. But immediately postoperatively, as he was emerging from anesthesia, severe surgical shock developed, characterized by low arterial blood pressure, rapid thready pulse, and cold clammy skin. The intravenous administration of 100 mg. of hydrocortisone free alcohol in 1000 cc. of 5% dextrose in saline resulted in considerable improvement within a half hour. Nine days later, viscera broke through the wound. Closure was made with through-and-through nonabsorbable surgical (silk) sutures during cyclopropane anesthesia, at which time an intravenous infusion of 1000 cc. of 5% dextrose in saline containing 100 mg. of hydrocortisone was administered. Immediately postoperatively he again manifested severe surgical shock, and he was treated with good results by the intravenous administration of another 100 mg. of hydrocortisone. Four days later a fecal fistula developed. The patient died a week later, after an episode of pyrexia which was not affected by antibiotic therapy. Autopsy revealed massive septicemia, with abscesses scattered throughout the peritoneum, the peribronchial tissue, and the myocardium. The adrenals were atrophic. One adrenal gland weighed 3.2 gm., the other 2 gm., with marked thinning of the cortex.

This case illustrates that prolonged therapy with hydrocortisone can result in hypocorticalism and that when such a patient requires surgical intervention, even of a relatively minor nature, he may require supplemental hydrocortisone to treat a crisis of acute adrenocortical insufficiency. Hypocorticalism was demonstrated both anatomically and functionally: anatomically, by the atrophy of both adrenal glands, with thinning of the cortex, and, functionally, by the states of surgical shock which developed following each of two relatively minor surgical procedures. In each instance, this complication occurred as soon as anesthesia wore off. In the first instance blood transfusion which was considered greater in quantity than the amount of blood lost during the appendectomy was ineffectual in preventing the postanesthetic shock. In

both instances the hypotensive state was corrected by the intravenous administration of additional hydrocortisone.

This case illustrates two other important points. First, patients receiving corticosteroid therapy may develop susceptibility to certain infections poorly responsive to antibiotics. Second, the administration of general anesthesia to such patients undergoing surgery may block or delay the state of acute adrenal cortex insufficiency until the effects of anesthesia are dissipated.

This case was the only fatality in our series, and death occurred not from hypocorticalism but from the massive sepsis, which may have been enhanced by our treatment of his insufficiency.

CASE 2.—Example of Elective Surgery in a Patient with Cortisone-Induced Hypocorticalism

A lawyer 43 years of age had been treated for pemphigus with cortisone for 5 years. His daily dose of cortisone had ranged from 200 to 1000 mg. Complications which ensued included cortisone-induced psychosis, which was treated by electroshock therapy, cortisone-induced osteoporosis, and bilateral avascular necrosis of the femoral heads together with avascular necrosis of the left humeral head. The patient developed so much pain and stiffness in his legs that he sought help and agreed to a prosthetic replacement of his left femoral head, which was performed on Jan. 13, 1954.

Preoperative laboratory findings disclosed that this patient had certain stigmata of hypoadrenalism. These included a failure to retain water, with high urinary output and arterial hypotension. When given 50 mg. of corticotropin in a 4-hour infusion, he did not retain salt nor did his 17-ketosteroid excretion rise. His total eosinophile count did not drop after this test. It was clear that this patient needed salt and adequate cortisone therapy, the dosage of which was to be determined by daily metabolic studies. He was given 2 liters of isotonic saline intravenously the first 24 postoperative hours and cortisone intramuscularly every 4 hours in doses of 50 to 100 mg. at a time, so that his daily dosage ranged between 400 and 600 mg. for 3 days. After the third day, results of the patient's blood chemistry studies were within normal limits and his urinary output and salt loss were normal. The first 2 days were characterized by wide swings in blood pressure and salt excretion. Twenty-four and 12 hours preoperatively he was given 100 mg. of cortisone intramuscularly.

ADRENOCORTICAL INSUFFICIENCY

On the day of operation the patient was given preanesthetic medication consisting of procainamide hydrochloride, 500 mg. orally, 75 minutes before anesthesia, and morphine sulphate, 10 mg., combined with scopolamine hydrobromide, 0.4 mg., injected hypodermically one hour before anesthesia. The intramuscular administration of cortisone was maintained. Anesthesia was induced by the intravenous injection of 400 mg. of hexobarbital sodium (Evipal Sodium) in a 2% aqueous concentration. This was followed by the administration of cyclopropane-oxygen anesthesia. During the operation, fluid therapy consisted of saline (1000 cc.), 6% dextran (500 cc.), blood (500 cc.), and 5% dextrose in water (500 cc.).

The patient was managed with saline and cortisone alone, and he was brought through the planned surgical procedure successfully. However, he required constant attention because he had nine bouts of hypotension in the first 72 hours. Salt excretion during this time was high, being 300 mEq. for the first 24 hours postoperatively.

We do not advocate this method for coping with the problem; but it is interesting to note that, despite the loss of a check rein on salt loss, patients requiring large-scale surgery can successfully survive.

CASE 3.—*Example of a Patient with Adrenal Insufficiency Due to Addison's Disease Requiring Elective Surgery* †

A man 37 years of age had Addison's disease for seven years. He had been managed fairly successfully for several years on a program of desoxycorticosterone acetate pellets of 150 mg. implanted every three months and cortisone in doses of 25 mg. daily orally. Owing to a back injury, he had a great deal of pain which interfered with his daily routine. Orthopedic consultation suggested that he might be helped by a lumbosacral fusion together with a sacroiliac fusion. Because of the severe degree of trauma involved in these operations and because of the patient's adrenocortical insufficiency due to Addison's disease, it was deemed dangerous to proceed with these operations. However, since this young man would become incapacitated without surgical intervention, it was decided, reluctantly, to perform the operations by doing the two different procedures at different times if necessary and by having a team versed in endocrinology and surgical physiology help in the management of this patient before, during, and after the operation.

† Dr. Ephraim Shorr, of the New York Hospital, provided advice in the management of this case.

It was planned to manage this patient with hydrocortisone intravenously throughout the surgical period and postoperatively as needed, supplementing this with desoxycorticosterone, saline, and cortisone as indicated. At 24 and 12 hours preoperatively he was given 100 mg. of cortisone intramuscularly.

The operation was accomplished on Oct. 21, 1954. Preanesthetic medication consisted of an opium preparation (Pantopon), 10 mg., and atropine sulphate, 0.4 mg., injected hypodermically one hour before induction of anesthesia. Anesthesia was obtained by the intravenous injection of 300 mg. of hexobarbital sodium in a 2% aqueous concentration followed by cyclopropane with oxygen. Endotracheal intubation was performed with a cuffed No. 36 Magill tube, and the patient was turned onto the prone position. Preanesthetic arterial blood pressure was 100 mm. Hg systolic and 64 mm. diastolic. The pulse rate was 72 per minute. These circulatory levels were maintained remarkably stable throughout the entire operation, which lasted more than 3 hours. The electrocardiogram which was observed during the procedure showed a regular sinus rhythm at all times. Fluid therapy consisted of 2000 cc. of blood to compensate for a similar amount of blood loss produced by the lumbosacral fusion followed by the sacroiliac fusion (both were done, since the patient's condition remained good). In addition, the patient received 100 mg. of hydrocortisone in 1000 cc. of 5% dextrose in saline, which was administered intravenously during the surgical procedure.

The postoperative course was satisfactory in that no Addisonian crisis developed at any time during the next 2 months. The urinary salt excretion during this time varied between 5 and 10 gm. a day, necessitating some replacement, and the arterial blood pressure was maintained within normal limits. To prevent negative salt balance, adequate amounts of desoxycorticosterone and saline were periodically administered. Minor complications, consisting of a urinary tract infection on the third postoperative day, a transfusion reaction characterized by mild angioneurotic edema, and a mild wound infection despite antibiotic therapy, occurred. In each instance increased cortisone and salt were given. Four months later, the patient was subjected to another surgical intervention for the removal of a Wilson plate which had been used in the spinal fusion as a form of fixation. The same program of management as used in the previous operation was employed, except that anesthesia was provided by means of local infiltration with 1% hexylcaine (Cyclaine) solution together with thiopental sodium by intravenous drip merely sufficient to cause drowsiness. No sequelae were noted other than the need for increased cortisone and added amounts of salt

and desoxycorticosterone immediately postoperatively. Water retention was never a problem.

This case is noteworthy because desoxycorticosterone provided a check rein on the tendency to develop salt loss and arterial hypotension. Desoxycorticosterone, it will be recalled, is an adrenocortical-like steroid that permits reabsorption of salt in the kidneys so that urinary salt loss is minimized. Though this patient had marked adrenocortical insufficiency, though the magnitude of his surgery was great, and though complications ensued postoperatively, this patient had a smooth postoperative course insofar as no Addisonian crisis ever developed.

ANESTHESIOLOGICAL CONSIDERATIONS

As to the effect of anesthesia on adrenocortical function during surgical trauma, previous studies have shown that uncomplicated general anesthesia modifies the usual response of the adrenal cortex to surgical stress.† By using the eosinophile count as an index of adrenocortical activity, it has been shown that the stress of surgical trauma produces a marked fall in the eosinophile count in the circulating blood.§ With use of this eosinopenic response with a fall of more than 50% of the eosinophiles as a criterion, it was observed that eosinopenia did not occur in 83% of the patients during uncomplicated general anesthesia for operations lasting more than 2 hours but that it did appear when the anesthesia wore off.¶ Similar studies during uncomplicated spinal anesthesia with surgery were less conclusive, in that 40% of the patients showed an eosinopenic response both during spinal anesthesia with surgery and after spinal anesthesia had worn off.¶ Although eosinophile counts in themselves provide only a rough estimate unless carefully done, they, along with urinary salt excretion, are useful aids in the day-to-day management of these patients.

Since acute adrenocortical insufficiency is accompanied by impaired homeostatic adjustments to stress, with inability to compensate for various circulatory disorders, it is important to avert stress-imposing reactions. Thus, high spinal anesthesia or deep general anesthesia, both of which may cause arterial

hypotension, should be avoided. Sympathetic blockade produced by drugs such as pentamethonium, hexamethonium, or trimethaphan camphorsulfonate (*d*-3,4[1',3'-dibenzyl-2'-ketoimidazolido]-1,2-trimethylene thiophanium *d*-camphor sulfonate) (Arfonad) should also be avoided, since pharmacological sympathetic blockade so produced may result in marked arterial hypotension from which recovery might be difficult. Respiratory depression from any cause should be prevented at all times. An excitement stage during induction of anesthesia should be averted by proper preanesthetic medication and by use of a small dose of an intravenous barbiturate. The management of postoperative pain should aim at securing pain relief without causing respiratory or circulatory depression.

COMMENT

The endocrinological and metabolic management of patients with hypocorticalism who require elective surgical therapy is important. It is suggested that such patients be made research projects for a biochemical team wherever feasible, in order to determine their metabolic status.

The preoperative estimation of hypocorticalism depends upon various factors. In the case of known Addison's disease, the diagnosis is obvious. Induced hypocorticalism resulting from prolonged therapy with cortisone or other corticosteroids should be suspected in any patient receiving such therapy prior to surgical intervention. Patients who have been treated with cortisone for only one or two weeks may, rarely, have suppressed adrenocortical function. In such cases corticosteroid therapy should be continued if surgery is required. If the patient has been receiving his treatment by oral administration, therapy should be maintained parenterally when the oral route is discontinued on the day of operation. There is an analogy here to diabetic patients requiring insulin therapy: in both instances endocrine therapy must be maintained, increased as necessary, but never interrupted. Although we have not seen prednisone (Meticorten)-

† References 5 and 6.

§ References 7, 8, and 9.

ADRENOCORTICAL INSUFFICIENCY

induced insufficiency, we presume that it, too, will be shown to occur.

When time permits, certain laboratory determinations are useful in planning individual management before, during and after surgery. Biochemical tests that are important include the eosinophile counts and electrolyte excretion in response to intravenous corticotropin; estimation of the 17-ketosteroids, the 17-hydroxycorticoids, and the acid steroid fraction¹¹ in the urine; measurement of daily urinary output; estimation of daily urinary salt excretion; determination of blood levels of sodium, potassium, chloride, and CO₂-combining power, and water load tests.

The following suggestions are advocated in the management of patients with hypocorticalism who require surgical intervention and anesthesia, although each case requires individualized treatment.

1. Increase the amount of corticosteroid preoperatively if the patient has been receiving such therapy. Never cease or decrease it unless it is possible to postpone surgery until a normal adrenal response has been reestablished.

2. Increase the salt intake during and after surgery. If salt loss is occurring, 6 to 9 gm. of sodium chloride may be necessary for the total daily replacement.

3. Estimate blood loss and fluid loss accurately and administer these amounts to the patient. Ascertain whether the patient is sweating and provide for appropriate salt replacement.

4. Be prepared to treat arterial hypotension that is not due to blood loss by the intravenous administration of hydrocortisone. This should be given by placing 100 mg. in a liter of saline and administering this quantity in from one to four hours.

5. Watch for signs of fluid retention by palpating the patient's bony prominences.

6. If increased stress, such as a postoperative infection, occurs, increase the amount of salt intake and of cortisone if necessary. However, decrease the cortisone thereafter as rapidly as possible. It may be advisable to change to desoxycorticosterone to diminish salt loss in excessive quantity rather than rely on high cortisone administration.

7. As soon as a salt balance can be obtained and maintained by oral intake, the dosage of corticosteroid should be diminished gradually but as rapidly as possible.

8. To maintain good nutrition, large amounts of protein are indicated. Sometimes it may be advisable to enhance this effect by the administration of testosterone.

9. These patients should be watched carefully day and night from the time of surgery until a proper metabolic and electrolyte balance is obtained. Asthenia, lassitude, weakness, and arterial hypotension indicate impending adrenocortical crisis. A low CO₂-combining power, excessive urinary salt loss, and low serum chloride and sodium also should alert one to the need for treatment. Hypokalemia must also be guarded against when using these steroids even as replacement.

10. In case of salt retention (as evidenced by edema) the amount of salt intake should be diminished. Desoxycorticosterone should be discontinued if it is being given then, but hydrocortisone or cortisone should be made available. If necessary, it may be wise to provide some potassium if too much sodium retention is present.

11. The urinary output should be measured and charted. Daily urinary output of more than 2000 cc. postoperatively the first 3 days should be suspected of containing an excess of salt loss, unless as a result of high fluid intake. Water intoxication and salt-losing nephritis should be ruled out.

12. If the patient has some cardiac disease with diminished cardiac reserve, other therapeutic aids should be given as indicated and the salt load must be watched carefully.

SUMMARY AND CONCLUSIONS

The management of three patients with adrenocortical insufficiency, each with a different set of conditions and each requiring surgery, is described. One patient had hypocorticalism induced by prolonged hydrocortisone therapy for rheumatoid arthritis; he survived two emergency operations but finally succumbed to septicemia. A second patient had cortisone-induced hypocorticalism and required a rather large-scale elective operation. The third patient was a known Addisonian who required an elective spinal fusion and sacroiliac fusion. All three patients were protected from the development of an adrenal crisis, though each of the patients was managed in a different manner. All required cortisone or hydrocortisone postoperatively in increased amounts. The management will vary, however, from patient to patient, depending upon many factors.

Some anesthesiological considerations on this problem are given. In the main these include avoidance of stress-imposing reactions, such as arterial hypotension and respiratory depression.

Patients who need surgical intervention and who have depressed adrenocortical function as a result of therapy with some corticosteroid may be managed safely through surgery of rather severe degree. If the proposed surgical procedure is of an elective nature, the optimum method of management would be to postpone the time of surgery until corticosteroid therapy has been discontinued and a sufficient length of time has elapsed to allow demonstration of normal adrenal reserve. If corticosteroid therapy must be continued, then it should not be discontinued during the time of surgical management; rather, corticosteroid therapy should be increased preoperatively, whether the surgical problem is an emergency or not. In the case of an elective procedure under such circumstances, the management is similar to that of the patient with known Addison's disease. The preoperative period should be utilized to evaluate the patient's metabolic and electrolyte requirements. Increased cortisone 24 hours before surgery is advised. During surgery, hydrocortisone should be given intravenously and sufficient salt intake should be given to the patient at all times. Postoperatively, corticosteroid therapy should be maintained as required by the patient in the immediate convalescent period, but it should be reduced gradually as rapidly as possible to prevent the possibility of sepsis and infection. Desoxycorticosterone is a very valuable salt-saving adjunct and should be used if necessary.

It is important to bear in mind that adrenocortical insufficiency may persist for many

weeks after prolonged corticosteroid therapy has been discontinued. The adrenocortical response of patients who require surgical intervention should be investigated carefully in order to avert acute adrenocortical insufficiency.

REFERENCES

1. Fraser, C. G.; Preuss, F. S., and Bigford, W. D.: Adrenal Atrophy and Irreversible Shock Associated with Cortisone Therapy, *J. A. M. A.* 149:1542-1543, 1952.
2. Lundy, J. S.: Cortisone Problems Involving Anesthesia, *Anesthesiology* 14:376-381, 1953.
3. Salassa, R. M., and others: Clinical Aspects of Suppression of Adrenal Cortical Function After Use of Cortisone, *Proc. Staff Meet., Mayo Clin.* 28:662-668, 1953.
4. Lewis, L., and others: Fatal Adrenal Cortical Insufficiency Precipitated by Surgery During Prolonged Cortisone Treatment, *Ann. Int. Med.* 39:116-126, 1953.
5. Traina, V., and Burstein, C. L.: Effect of Anesthesia on the Eosinopenic Response to Surgical Trauma: Preliminary Report, *Am. J. Surg.* 84:13-15, 1952.
6. Traina, V.; Burstein, C. L.; Ciliberti, B. J., and Rovenstine, E. A.: Pituitary-Adrenal Response to Surgical Trauma and Anesthesia: I. The Eosinopenic Response, *Anesthesiology* 14:449-455, 1953.
7. Almy, T. P., and Laragh, J. H.: Reduction in Circulating Eosinophils Following Epinephrine, Insulin and Surgical Operation, *Am. J. Med.* 6:507, 1949.
8. Roche, M.; Hills, A. G., and Thorn, G. W.: The Levels of Circulating Eosinophils as an Indicator of Adrenal Cortical Adequacy Following Major Surgery, *J. Clin. Endocrinol.* 2:662, 1949.
9. Hayes, M. A.: Shock and the Adrenocortex, *Surgery* 35:174-190, 1954.
10. Nicholas, J. A., and Wilson, P. D.: Adrenocortical Function in Operative Procedures Upon Bones and Joints, *J. Bone & Joint Surg.* 35A:559-572, 1953.
11. Nicholas, J. A.; Wilson, P. D., and Umberger, C. J.: A Comparison of Urinary Neutral 17-Ketosteroid Excretion with Other Fractions in Operations upon the Bones and Joints, *Surg., Gynec. & Obst.* 100:387-390, 1955.

U
L
L
T
of t
have
both
gene
preg
cerv
(doi
grea
first
neu
in t
of t
and
leve
pass
or t
thor
to s
loca
The
vess
mus
Stir
tion
rest
S
som
pass
clos
the
S
F
Adn
f

President Kennedy's Adrenals

John Nichols, MD

While the late President Kennedy held public office, an aura of mystery prevailed regarding his endocrine status. During his campaign for, and brief tenure of, the presidency, rumors circulated that he suffered from chronic adrenocortical insufficiency (Addison's disease). Credence was given to these rumors by failure of his attending physicians to deny the allegations. Since his death, speculation continues partially related to failure of federal officials to release pertinent data.^{1,2} This is in marked contrast to the intimate details of President Eisenhower's several illnesses which were given wide dissemination in various news media. The moral and ethical issues were carefully considered by Lt Gen L. D. Heaton and his associates³ when they concluded the world had a right to know of the medical details of President Eisenhower's operation for regional enteritis. President Eisenhower agreed with this. This writer also agrees that the public is entitled to knowledge of the health of their chief executive and candidates for this office. Details of the final illnesses of other presidents who died or were assassinated while in office have been disclosed and extensively discussed in medical journals.

It may be argued that a breach of physician-patient relationship would result if physicians, with direct professional knowledge of President Kennedy's illness, made public comment without consent. Witness the furor which arose from Lord Moran's disclosure⁴ of Churchill's clinical condition. However, none of the foregoing considerations would apply if any other person (physician or lay) drew conclusions from previously published data.

Known Published Facts

In a discussion on management of adrenocortical insufficiency during surgery, Nicholas et al⁵ in 1955 reported three cases—the third, a man aged 37 whose Addison's disease was stated to be well controlled for seven years. After extensive endocrine study, lumbosacral and sacro-iliac fusion was performed in the Hospital for Special Surgery in the Cornell University Medical College Complex on Oct 21, 1954. The patient returned four months later for removal of the metal plate.

On Oct 11, 1954, in a 1½-inch column on page 39, the *New York*

From the Department of Pathology, University of Kansas Medical Center, Kansas City. Reprint requests to University of Kansas Medical Center, Rainbow Blvd at 39th St, Kansas City, Kan 66103 (Dr. Nichols).

J. F. Kennedy Needs Surgery
Senator John F. Kennedy, Democrat of Massachusetts, disclosed last night that he would enter the Hospital for Special Surgery here today for a spinal operation to clear up a wartime injury. He said he expected to be in hospital, at 321 East Forty-second Street, about six weeks.

October 11, 1954

KENNEDY SURGERY TODAY
Bay State Senator Will Be Treated for Spine Injury
Senator John F. Kennedy, Democrat of Massachusetts, is scheduled to undergo surgery today in the Hospital for Special Surgery, 321 East Forty-second Street. He had suffered a spinal injury in action in the Solomon Islands when his PT boat was cut in two by a Japanese destroyer. Senator Kennedy underwent surgery in 1945, but his condition has progressively worsened, requiring him to use crutches. The new operation has been postponed three times in the last ten days for a series of medical tests. It is believed that Mr. Kennedy will be hospitalized for two months and will be able to return to Washington some time in February.

October 21, 1954

KENNEDY QUILTS HOSPITAL
Massachusetts Senator Flies to Florida to Recuperate
Senator John F. Kennedy, Democrat of Massachusetts, walked out of the Hospital for Special Surgery yesterday. Later he, his wife and his brother, Edward, a Harvard student, left Teterboro, N. J., Airport by private plane for Miami Beach. The Senator will convalesce there. A hospital bulletin said: "His condition is good and it is hoped that he will return to Washington at the end of March." Senator Kennedy underwent a spinal operation last October at the hospital for an injury received in action in the Navy in World War II. He went to Florida shortly before Christmas and reentered the hospital on Feb. 10. The next day a metal plate that was said to be slowing his recovery was removed.

February 26, 1955

New York Times report of President Kennedy's surgery. (Copyrighted 1954, 1955 by the *New York Times* Company. Reprinted by permission.)

Times reported that Senator John F. Kennedy entered the Hospital for Special Surgery for a spinal operation. Later, this same newspaper, in a 3½-inch column on page 17, announced that Senator Kennedy was operated on Oct 21, 1954. Again, four months later, Feb 26, 1955, the *Times* revealed that Senator Kennedy walked out of the hospital, having had a plate removed 15 days previously (Figure).

Comment

These facts were independently documented by the two separate disciplines of medicine and journalism prior to his candidacy for the presidency of the United States. It is most unlikely that two persons with the same age and clinical history of the late President would have undergone similar surgery in the same hospital on the same day and returned on exactly the same time four months later for removal of the plates. If so, Nicholas et al would have illustrated their paper with four cases instead of three. This writer believes the case cited by Nicholas et al is that of the late President and he accepts their clinical diagnosis of Addison's disease.


The diagnosis of Addison's disease could have been firmly established at autopsy and perhaps the

etiology determined. However, the autopsy protocol is curiously silent on this point as well as on details of the pituitary, of his vertebral column, and sacroiliac joints. The silence on these points may be due to (a) accidental or intentional failure to search and observe, or (b) suppression of autopsy findings and existing clinical records by relatives or federal officials or both. These conditions would not have prevailed if the autopsy had been done in the jurisdiction where death occurred. In any circumstance, the clinical diagnosis of Addison's disease may be strongly presumed by continued silence by the attending physicians, officials of the hospital, or others with direct knowledge.

The most unfortunate aspect is concealment of the diagnosis. Addison's disease, formerly fatal, is an honorable disease and is not a disease to be concealed. It has no stigmata to be avoided. Patients with Addison's disease can now be maintained under perfect control, whereas diabetes still may follow an erratic, hazardous, and fulminating course even with the best of medical therapy. The fact that President Kennedy was continuously engaged in strenuous mental and physical activity, tolerated extensive surgical trauma, and became father of four children, all without decrease in life expectancy, is noteworthy.

References

1. Humes, J.J.; Boswell, J.T.; and Finck, P.A.: *Autopsy Report and Supplemental Report* (Commission Exhibit No. 387), The President's Commission on the Assassination of President Kennedy Report, US Government Printing Office, 1964, pp 538-545.
2. Official Autopsy Report on President Kennedy, LETTERS, editorial comment, *JAMA* 192:63 (April 5) 1965.
3. Heaton, L.D., et al: President Eisenhower's Operation for Regional Enteritis: A Footnote to History, *Ann Surg* 159:661-666 (May) 1964.
4. Professional Secrecy, editorial, *Brit Med J* 1:1313-1314 (May 28) 1966.
5. Nicholas, A., et al: Management of Adrenocortical Insufficiency During Surgery, *Arch Surg* 71:737-742 (Nov) 1955.



FRACASTORO, PHYSICIAN OF ITALIAN RENAISSANCE.—Giroloamo Fracastoro (1478-1553), physician of the Italian Renaissance, described syphilis and gave the disease its name through the medium of poetry. Prior to that, the disease was called the "love pestilence."

Hieronymus Fracastorius, known today as Giroloamo Fracastoro, was born in Verona, Italy, and studied at the nearby University of Padua. He entered into the practice of medicine in his native city. Syphilis and tuberculosis were widespread and he turned his attention to those diseases.

In 1525, he published his poem, *Syphilis sive Morbus Gallicus*, with a revision five years later. His *De Contagione*, which appeared in 1546, is a more scientific discourse on that disease and tuberculosis. This also had a chapter on the treatment of the venereal disease. (Fracastorius, the Poet of Syphilis, editorial, *JAMA* 186:593-594 [Nov 9] 1963.)

Fracastoro retired from the active practice of medicine shortly after that and devoted his time to the materia medica and botany. He rediscovered some of the herbs used in olden times, wrote of the movements of the planets, became interested in geology, showed a concept of the refraction of light, and was the first to refer to the magnetic poles of the earth. A stroke ended his life.

Italy in 1955 issued a 25 lire stamp bearing his portrait.—Mirt, J.A., "Medical Pathfinders on Postage Stamps."

First Medical disclosure that

JOHN F. KENNEDY had

suffered from ADDISON'S

DISEASE.

**NEW YORK TIMES
report of President
Kennedy's surgery.
(Copyrighted 1954,
1955 by the New
York Times Company.
Reprinted by permis-
sion.)**

President Kennedy's Adrenals

John Nichols, MD

While the late President Kennedy held public office, an aura of mystery prevailed regarding his endocrine status. During his campaign for, and brief tenure of, the presidency, rumors circulated that he suffered from chronic adrenocortical insufficiency (Addison's disease). Credence was given to these rumors by failure of his attending physicians to deny the allegations. Since his death, speculation continues partially related to failure of federal officials to release pertinent data.^{1,2} This is in marked contrast to the intimate details of President Eisenhower's several illnesses which were given wide dissemination in various news media. The moral and ethical issues were carefully considered by Lt Gen L. D. Heaton and his associates³ when they concluded the world had a right to know of the medical details of President Eisenhower's operation for regional enteritis. President Eisenhower agreed with this. This writer also agrees that the public is entitled to knowledge of the health of their chief executive and candidates for this office. Details of the final illnesses of other presidents who died or were assassinated while in office have been disclosed and extensively discussed in medical journals.

It may be argued that a breach of physician-patient relationship would result if physicians, with direct professional knowledge of President Kennedy's illness, made public comment without consent. Witness the furor which arose from Lord Moran's disclosure⁴ of Churchill's clinical condition. However, none of the foregoing considerations would apply if any other person (physician or lay) drew conclusions from previously published data.

Known Published Facts

In a discussion on management of adrenocortical insufficiency during surgery, Nicholas et al⁵ in 1955 reported three cases—the third, a man aged 37 whose Addison's disease was stated to be well controlled for seven years. After extensive endocrine study, lumbosacral and sacro-iliac fusion was performed in the Hospital for Special Surgery in the Cornell University Medical College Complex on Oct 21, 1954. The patient returned four months later for removal of the metal plate.

On Oct 11, 1954, in a 1½-inch column on page 39, the *New York*

From the Department of Pathology, University of Kansas Medical Center, Kansas City. Reprint requests to University of Kansas Medical Center, Rainbow Blvd at 39th St, Kansas City, Kan 66103 (Dr. Nichols).

Senator John F. Kennedy, Democrat of Massachusetts, disclosed last night that he would enter the Hospital for Special Surgery here today for a spinal operation to clear up a wartime injury. He said he expected to be in hospital, at 321 East Forty-second Street, about six weeks.

October 11, 1954

KENNEDY SURGERY TODAY

Bay State Senator Will Be Treated for Spine Injury

Senator John F. Kennedy, Democrat of Massachusetts, is scheduled to undergo surgery today in the Hospital for Special Surgery, 321 East Forty-second Street. He had suffered a spinal injury in action in the Solomon Islands when his PT boat was cut in two by a Japanese destroyer. Senator Kennedy underwent surgery in 1945, but his condition has progressively worsened, requiring him to use crutches. The new operation has been postponed three times in the last ten days for a series of medical tests. It is believed that Mr. Kennedy will be hospitalized for two months and will be able to return to Washington some time in February.

October 21, 1954

KENNEDY QUILTS HOSPITAL

Massachusetts Senator Flies to Florida to Recuperate

Senator John F. Kennedy, Democrat of Massachusetts, walked out of the Hospital for Special Surgery yesterday. Later he, his wife and his brother, Edward, a Harvard student, left Teterboro, N. J., Airport by private plane for Miami Beach. The Senator will convalesce there. A hospital bulletin said: "His condition is good and it is hoped that he will return to Washington at the end of March." Senator Kennedy underwent a spinal operation last October at the hospital for an injury received in action in the Navy in World War II. He went to Florida shortly before Christmas and reentered the hospital on Feb. 10. The next day a metal plate that was said to be slowing his recovery was removed.

February 26, 1955

New York Times report of President Kennedy's surgery. (Copyrighted 1954, 1955 by the New York Times Company. Reprinted by permission.)

Times reported that Senator John F. Kennedy entered the Hospital for Special Surgery for a spinal operation. Later, this same newspaper, in a 3½-inch column on page 17, announced that Senator Kennedy was operated on Oct 21, 1954. Again, four months later, Feb 26, 1955, the *Times* revealed that Senator Kennedy walked out of the hospital, having had a plate removed 15 days previously (Figure).

Comment

These facts were independently documented by the two separate disciplines of medicine and journalism prior to his candidacy for the presidency of the United States. It is most unlikely that two persons with the same age and clinical history of the late President would have undergone similar surgery in the same hospital on the same day and returned on exactly the same time four months later for removal of the plates. If so, Nicholas et al would have illustrated their paper with four cases instead of three. This writer believes the case cited by Nicholas et al is that of the late President and he accepts their clinical diagnosis of Addison's disease.

The diagnosis of Addison's disease could have been firmly established at autopsy and perhaps the

etiology determined. However, the autopsy protocol is curiously silent on this point as well as on details of the pituitary, of his vertebral column, and sacroiliac joints. The silence on these points may be due to (a) accidental or intentional failure to search and observe, or (b) suppression of autopsy findings and existing clinical records by relatives or federal officials or both. These conditions would not have prevailed if the autopsy had been done in the jurisdiction where death occurred. In any circumstance, the clinical diagnosis of Addison's disease may be strongly presumed by continued silence by the attending physicians, officials of the hospital, or others with direct knowledge.

The most unfortunate aspect is concealment of the diagnosis. Addison's disease, formerly fatal, is an honorable disease and is not a disease to be concealed. It has no stigmata to be avoided. Patients with Addison's disease can now be maintained under perfect control, whereas diabetes still may follow an erratic, hazardous, and fulminating course even with the best of medical therapy. The fact that President Kennedy was continuously engaged in strenuous mental and physical activity, tolerated extensive surgical trauma, and became father of four children, all without decrease in life expectancy, is noteworthy.

References

1. Humes, J.J.; Boswell, J.T.; and Finck, P.A.: *Autopsy Report and Supplemental Report* (Commission Exhibit No. 387), The President's Commission on the Assassination of President Kennedy Report, US Government Printing Office, 1964, pp 538-545.
2. Official Autopsy Report on President Kennedy, LETTERS, editorial comment, *JAMA* 192:63 (April 5) 1965.
3. Heaton, L.D., et al: President Eisenhower's Operation for

Regional Enteritis: A Footnote to History, *Ann Surg* 159:661-666 (May) 1964.

4. Professional Secrecy, editorial, *Brit Med J* 1:1313-1314 (May 28) 1966.

5. Nicholas, A., et al: Management of Adrenocortical Insufficiency During Surgery, *Arch Surg* 71:737-742 (Nov) 1955.



FRACASTORO, PHYSICIAN OF ITALIAN RENAISSANCE.—Girolamo Fracastoro (1478-1553), physician of the Italian Renaissance, described syphilis and gave the disease its name through the medium of poetry. Prior to that, the disease was called the "love pestilence."

Hieronymus Fracastorius, known today as Girolamo Fracastoro, was born in Verona, Italy, and studied at the nearby University of Padua. He entered into the practice of medicine in his native city. Syphilis and tuberculosis were widespread and he turned his attention to those diseases.

In 1525, he published his poem, *Syphilis sive Morbus Gallicus*, with a revision five years later. His *De Contagione*, which appeared in 1546, is a more scientific discourse on that disease and tuberculosis. This also had a chapter on the treatment of the venereal disease. (Fracastorius, the Poet of Syphilis, editorial, *JAMA* 186:593-594 [Nov 9] 1963.)

Fracastoro retired from the active practice of medicine shortly after that and devoted his time to the materia medica and botany. He rediscovered some of the herbs used in olden times, wrote of the movements of the planets, became interested in geology, showed a concept of the refraction of light, and was the first to refer to the magnetic poles of the earth. A stroke ended his life.

Italy in 1955 issued a 25 lire stamp bearing his portrait.—Mirt, J.A., "Medical Pathfinders on Postage Stamps."

Doc Thinks That JFK Had Gland Woes

By MARK BLOOM
Science Editor

Back in the dim, red dawn of time when John F. Kennedy was battling Lyndon B. Johnson for the 1960 Democratic Presidential nomination, the Johnson forces tried to make health an issue by contending that Kennedy suffered from Addison's disease.

A pathologist at the University of Kansas asserted in the Journal of the American Medical Association yesterday that Johnson was most likely right.

Dr. John Nichols said that Kennedy's operation at the Hospital for Special Surgery here Oct. 21, 1954, was performed to correct effects of the glandular disease.

The Kennedy Version

At the time, Kennedy said the operation was needed to alleviate back injuries he suffered during World War II. It was a spinal fusion procedure involving the insertion of a metal plate.

Nichols described an article written by a surgeon on the hospital staff in 1955 which described an operation for Addison's disease on an unidentified 37-year-old man on Oct. 21, 1954.

"It is most unlikely that two persons with the same age and clinical history of the late President would have undergone similar surgery on the same day and returned on exactly the same time four months later for removal of the plates," said Nichols.

Medical Coincidence

Kennedy returned to the hospital on Feb. 10, 1955, for removal of a steel plate. It was the same day that the man described in the article returned to the hospital for removal of a metal plate.

Addison's disease affects the adrenal glands, causing an insufficient adrenal excretion. It was once fatal, but has been easily treatable with cortisone and other steroid drugs for almost 50 years. In some cases, surgery may be required which could be similar to a back injury operation.

JULY 11, 1967

DAILY NEWS TUESDAY

REL
JULY 11
LAW
JOURNAL

by 'Ina' PEOPLE de ↓ setec a pphallo in stelo ← see if they

"There's something in you that craves expression, and it must come out," said Illinois Republican Senator Everett Dirksen, 71, explaining his late blooming career as a Capitol Records star. The Senator's first two LP exercises in throbbing recitative, *Gallant Men* and *Man Is Not Alone*, have sold 600,000 copies, and he has now finished cutting a third, in which he intones such golden oldies as *A Visit from St. Nicholas* and *Silent Night* while a 22-man orchestra and ten-man choir make moan in the background. As for that craving, it often finds outlet in his campaign to make the marigold the national flower, though Ev confessed that he had been nursing his thespian urgings for years, had in fact decided on a stage career when he was just a tad but "my mother wouldn't let me."

With a flick of one suety hip, the most sensational new *basquetbolista* in the hemisphere fainted his opponent out of his socks and drove in for the layup. Yes, fans, Fidel Castro, 39, has decided to add basketball to a list of athletic achievements that already includes a lifetime baseball batting average of 1.000. *El Artillero* (The Gunner, as he is called by any Havana paper with its wits about it) drilled in 40 points in his first try at *basquetbol*, graciously let it be known afterward that 1) no overall score was kept, and 2) his team won by seven points.

The maître d' at San Francisco's Trader Vic's restaurant was about to shut down for the night when somebody came up and said: "There's a little girl



DIRKSEN AMONG THE MARIGOLDS
A visit from St. Nicholas.


outside asking for something to eat." It was a pretty cute surprise when he went out and found British Prima Ballerina Margot Fonteyn, 48, along with Partner Rudolf Nureyev, 28, and seven friends, all clamoring for some rum and Chinese goodies after a performance of the touring Royal Ballet. Two hours later, the merrymakers danced off into the night—and now it was the San Francisco police department's turn to be surprised. At 3 a.m. cops answered a call to turn off a noisy hippie party at a pad in Haight-Ashbury, chased the gang up to the rooftops, and beheld Rudi lying prone among the hippies on one roof, Dame Margot tucked away on an adjoining rooftop. That sort of ended the party, except for a trip to the station house, where Rudi screamed "You are all children!" as the photographers came swarming around—then back to work the next night, dancing *Paradise Lost*.

Despite vigorous denials by the Kennedy family, medical detectives have long suspected that John F. Kennedy suffered from Addison's disease, a gradual atrophy of the adrenal glands that in its milder stages can be contained by cortisone (which Kennedy took), but in more advanced cases can result in low resistance to infection, chronic backache and kidney failure. Now a University of Kansas pathologist, Dr. John Nichols, 46, has concluded in the *A.M.A. Journal* that Kennedy did have it, that an infection stemming from it almost killed him after his spinal operation in 1954. Nichols bases his conclusion on an article he came across in the November 1955 *Archives of Surgery* in which J.F.K.'s surgeon, Dr. James A. Nicholas, describes his prep-


arations for an "Addisonian crisis" in an unnamed 37-year-old man who underwent spinal surgery at Manhattan's Hospital for Special Surgery on Oct. 21, 1954—the same day and the same hospital where 37-year-old John Kennedy underwent the same operation.

It started off as a name for Beazle George Harrison's hairdo, became a discothèque, and will now exfoliate as a business empire. At least Sybil Burton Christopher, 38, major stockholder and drawing card of Manhattan's bon-ton discothèque Arthur, is making an Arthur franchise available to anyone with \$50,000 and a suitably overcrowded location. Sybil expects to have spawned seven to ten little Arthurs within a year, will supply suggestions for layout and décor, publicity and the presence of such celebrities as herself and Friend Roddy McDowall at openings. No "small towns" need apply. Would-be Arthurians in Asbury Park, N.J. (pop. 17,800), and Buffalo (pop. 481,453) have already been turned down.

A veritable "enemy of Greek tourism," concluded Greece's ever-watchful military dictatorship when they heard some of the things Actress Melina Mercouri, 41, star of Broadway's *Illya Darling*, was saying about her homeland—like advising folks not to visit Greece until the soldiers go away. Therefore, Brigadier General Stylianos Patakos solemnly announced in Athens that the regime was stripping Melina of her Greek citizenship and all her property as well. "I was born a Greek and I will die a Greek," snorted Melina. "Patakos was born a fascist and will die a fascist. If he wants to make me a Joan of Arc, that is his privilege."



NUREYEV & FONTEYN IN "PARADISE LOST"
Night to remember.



MERCOURI IN "ILLYA"
Enemy of th

FOR AWA JOURNAL
for JULY (11), 1967

MUST get this

J. A. M. A. - OCTOBER 26, 1964

OFFICIAL AUTOPSY REPORT ON PRESIDENT KENNEDY

also SUPPLEMENTARY REPORT OF AUTOPSY NUMBER A63-272-
PRESIDENT JOHN F. KENNEDY
Pathological Examination Report No. A63-272

- with FINAL SUMMARY, Signed by J. J. Humes, CDR, MC, USN,
497831
6 December 1963

(Commanding Officer, U. S. Naval Medical School)

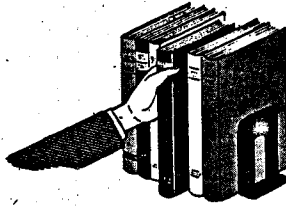
Addressed to: The White House Physician

Via: Commanding Officer, National Naval Medical Center

Appears in the "WARREN REPORT", Appendix IX, 1964, pp 538-546

The Clinical Summary introducing the Autopsy Report notes the first attention on arrival at Parkland Hospital in Dallas by Dr. Malcolm Perry. Telephone conversation with Dr. Perry on November 23, 1963 developed the "information relative to the observations made by Dr. Perry and procedures performed there prior to death."

However, there is no mention here of later disclosure that Dr. Perry had knowledge of President Kennedy's supposed Adrenocodical Insufficiency and that Dr. Perry had, therefore, made emergency injections of cortisone.



From Other Pages

Official Autopsy Report on President Kennedy

Clinical Summary

According to available information the deceased, President John F. Kennedy, was riding in an open car in a motorcade during an official visit to Dallas, Texas on Nov 22, 1963. The President was sitting in the right rear seat with Mrs. Kennedy seated on the same seat to his left. Sitting directly in front of the President was Governor John B. Connally of Texas and directly in front of Mrs. Kennedy sat Mrs. Connally. The vehicle was moving at a slow rate of speed down an incline into an underpass that leads to a freeway route to the Dallas Trade Mart where the President was to deliver an address.

Three shots were heard and the President fell forward bleeding from the head. (Governor Connally was seriously wounded by the same gunfire.) According to newspaper reports (*Washington Post* Nov 23, 1963) Bob Jackson, a Dallas *Times Herald* photographer, said he looked around as he heard the shots and saw a rifle barrel disappearing into a window on an upper floor of the nearby Texas School Book Depository Building.

Shortly following the wounding of the two men the car was driven to Parkland Hospital in Dallas. In the emergency room of that hospital the President was attended by Dr. Malcolm Perry. Telephone communication with Dr. Perry on Nov 23, 1963 develops the following information relative to the observations made by Dr. Perry and procedures performed there prior to death.

Dr. Perry noted the massive wound of the head and a second much smaller wound of the low anterior neck in approximately the midline. A tracheostomy was performed by extending the latter wound. At this point bloody air was noted bubbling from the wound and an injury to the right lateral wall of the trachea was observed. Incisions were made in the upper anterior chest wall bilaterally to combat possible subcutaneous emphysema. Intravenous infusions of blood and saline were begun and oxygen was administered. Despite these measures cardiac arrest occurred and closed chest cardiac massage failed to reestablish cardiac action. The President was pronounced dead approximately 30 to 40 minutes after receiving his wounds.

The remains were transported via the Presidential plane to Washington, DC and subsequently to the Naval Medical School, National Naval Medical Center, Bethesda, Md, for postmortem examination.

General Description of Body

The body is that of a muscular, well-developed and well-nourished adult Caucasian male measuring 72½ inches and weighing approximately 170 pounds. There is beginning rigor mortis, minimal dependent livor mortis of the dorsum, and early algor mortis. The hair is reddish brown and abundant, the eyes are blue, the right pupil measuring 8 mm in diameter, the left 4 mm. There is edema and ecchymosis of the inner canthus region of the left eyelid

measuring approximately 1.5 cm in greatest diameter. There is edema and ecchymosis diffusely over the right supra-orbital ridge with abnormal mobility of the underlying bone. (The remainder of the scalp will be described with the skull.) There is clotted blood on the external ears but otherwise the ears, nares, and mouth are essentially unremarkable. The teeth are in excellent repair and there is some pallor of the oral mucous membrane.

Situated on the upper right posterior thorax just above the upper border of the scapula there is 7×4 mm oval wound. This wound is measured to be 14 cm from the tip of the right acromion process and 14 cm below the tip of the right mastoid process.

Situated in the low anterior neck at approximately the level of the third and fourth tracheal rings is a 6.5 cm long transverse wound with widely gaping irregular edges. (The depth and character of these wounds will be further described below.)

Situated on the anterior chest wall in the nipple line are bilateral 2 cm long recent transverse surgical incisions into the subcutaneous tissue. The one on the left is situated 11 cm cephalad to the nipple and the one on the right 8 cm cephalad to the nipple. There is no hemorrhage or ecchymosis associated with these wounds. A similar clean wound measuring 2 cm in length is situated on the anterolateral aspect of the left midarm. Situated on the anterolateral aspect of each ankle is a recent 2 cm transverse incision into the subcutaneous tissue.

There is an old, well-healed 8 cm McBurney abdominal incision. Over the lumbar spine in the midline is an old, well-healed 15 cm scar. Situated on the upper anterolateral aspect of the right thigh is an old, well-healed 8 cm scar.

Missile Wounds

1. There is a large irregular defect of the scalp and skull on the right involving chiefly the parietal bone but extending somewhat into the temporal and occipital regions. In this region there is an actual absence of scalp and bone producing a defect which measures approximately 13 cm in greatest diameter.

From the irregular margins of the above scalp defect tears extend in stellate fashion into the more or less intact scalp as follows:

- a. From the right inferior temporoparietal margin anterior to the right ear to a point slightly above the tragus.
- b. From the anterior parietal margin anteriorly on the forehead to approximately 4 cm above the right orbital ridge.
- c. From the left margin of the main defect across the midline anterolaterally for a distance of approximately 8 cm.
- d. From the same starting point as c. 10 cm posterolaterally.

Situated in the posterior scalp approximately 2.5 cm laterally to the right and slightly above the external occipital protuberance is a lacerated wound measuring 15×6 mm. In the underlying bone is a corresponding wound through the skull which exhibits beveling of the margins of the bone when viewed from the inner aspect of the skull.

Clearly visible in the above described large skull defect and extending from it is lacerated brain tissue which on close inspection proves to represent the major portion of the right cerebral hemisphere. At this point it is noted that the falx cerebri is extensively lacerated with disruption of the superior sagittal sinus.

Upon reflecting the scalp multiple complete fracture lines are seen to radiate from both the large defect at the vertex

and the smaller wound at the occiput. These vary greatly in length and direction, the longest measuring approximately 19 cm. These result in the production of numerous fragments which vary in size from a few millimeters to 10 cm in greatest diameter.

The complexity of these fractures and the fragments thus produced tax satisfactory verbal description and are better appreciated in photographs and roentgenograms which are prepared.

The brain is removed and preserved for further study following formalin fixation.

Received as separate specimens from Dallas . . . are three fragments of skull bone which in aggregate roughly approximate the dimensions of the large defect described above. At one angle of the largest of these fragments is a portion of the perimeter of a roughly circular wound presumably of exit which exhibits beveling of the outer aspect of the bone and is estimated to measure approximately 2.5 to 3.0 cm in diameter. Roentgenograms of this fragment reveal minute particles of metal in the bone at this margin. Roentgenograms of the skull reveal multiple minute metallic fragments along a line corresponding with a line joining the above described small occipital wound and the right supraorbital ridge. From the surface of the disrupted right cerebral cortex two small irregularly shaped fragments of metal are recovered. These measure 7×2 mm and 3×1 mm. These are placed in the custody of Agents Francis X. O'Neill, Jr. and James W. Sibert, of the Federal Bureau of Investigation, who executed a receipt therefor (attached).

2. The second wound presumably of entry is that described above in the upper right posterior thorax. Beneath the skin there is ecchymosis of subcutaneous tissue and musculature. The missile path through the fascia and musculature cannot be easily probed. The wound presumably of exit was that described by Dr. Malcolm Perry of Dallas in the low anterior cervical region. When observed by Dr. Perry the wound measured "a few millimeters in diameter," however it was extended as a tracheostomy incision and thus its character is distorted at the time of autopsy. However, there is considerable ecchymosis of the strap muscles of the right side of the neck and of the fascia about the trachea adjacent to the line of the tracheostomy wound. The third point of reference in connecting these two wounds is in the apex (supraclavicular portion) of the right pleural cavity. In this region there is contusion of the parietal pleura and of the extreme apical portion of the right upper lobe of the lung. In both instances the diameter of contusion and ecchymosis at the point of maximal involvement measures 5 cm. Both the visceral and parietal pleura are intact overlying these areas of trauma.

Incisions

The scalp wounds are extended in the coronal plane to examine the cranial content and the customary (Y) shaped incision is used to examine the body cavities.

Thoracic Cavity

The bony cage is unremarkable. The thoracic organs are in their normal positions and relationships and there is no increase in free pleural fluid. The above described area of contusion in the apical portion of the right pleural cavity is noted.

Lungs

The lungs are of essentially similar appearance the right weighing 320 gm, the left 290 gm. The lungs are well aerated with smooth glistening pleural surfaces and gray-pink color. A 5 cm diameter area of purplish red discolora-

tion and increased firmness to palpation is situated in the apical portion of the right upper lobe. This corresponds to the similar area described in the overlying parietal pleura. Incision in this region reveals recent hemorrhage into pulmonary parenchyma.

Heart

The pericardial cavity is smooth walled and contains approximately 10 cc of straw-colored fluid. The heart is of essentially normal external contour and weighs 350 gm. The pulmonary artery is opened in situ and no abnormalities are noted. The cardiac chambers contain moderate amounts of postmortem clotted blood. There are no gross abnormalities of the leaflets of any of the cardiac valves. The following are the circumferences of the cardiac valves: aortic 7.5 cm, pulmonic 7 cm, tricuspid 12 cm, and mitral 11 cm. The myocardium is firm and reddish brown. The left ventricular myocardium averages 1.2 cm in thickness, the right ventricular myocardium 0.4 cm. The coronary arteries are dissected and are of normal distribution and smooth walled and elastic throughout.

Abdominal Cavity

The abdominal organs are in their normal positions and relationships and there is no increase in free peritoneal fluid. The vermiform appendix is surgically absent and there are a few adhesions joining the region of the cecum to the ventral abdominal wall at the above described old abdominal incisional scar.

Skeletal System

Aside from the above described skull wounds there are no significant gross skeletal abnormalities.

Photography

Black and white and color photographs depicting significant findings are exposed but not developed. These photographs were placed in the custody of Agent Roy H. Kellerman of the US Secret Service, who executed a receipt therefor (attached).

Roentgenograms

Roentgenograms are made of the entire body and of the separately submitted three fragments of skull bone. These are developed and were placed in the custody of Agent Roy H. Kellerman of the US Secret Service, who executed a receipt therefor (attached).

Summary

Based on the above observations it is our opinion that the deceased died as a result of two perforating gunshot wounds inflicted by high velocity projectiles fired by a person or persons unknown. The projectiles were fired from a point behind and somewhat above the level of the deceased. The observations and available information do not permit a satisfactory estimate as to the sequence of the two wounds. The fatal missile entered the skull above and to the right of the external occipital protuberance. A portion of the projectile traversed the cranial cavity in a posterior-anterior direction (see lateral skull roentgenograms) depositing minute particles along its path. A portion of the projectile made its exit through the parietal bone on the right carrying with it portions of cerebrum, skull, and scalp. The two wounds of the skull combined with the force of the missile produced extensive fragmentation of the skull, laceration of the superior sagittal sinus, and of the right cerebral hemisphere. The other missile entered the right superior posterior thorax above the scapula and traversed the soft tissues of the suprascapular and the supraclavicular portions of the

base of the right side of the neck. This missile produced contusions of the right apical parietal pleura and of the apical portion of the right upper lobe of the lung. The missile contused the strap muscles of the right side of the neck, damaged the trachea and made its exit through the anterior surface of the neck. As far as can be ascertained this missile struck no bony structures in its path through the body.

In addition, it is our opinion that the wound of the skull produced such extensive damage to the brain as to preclude the possibility of the deceased surviving this injury.

A supplementary report will be submitted following more detailed examination of the brain and of microscopic sections. However, it is not anticipated that these examinations will materially alter the findings.

/s/ J. J. HUMES "J" THORNTON BOSWELL PIERRE A. FINCK
 CDR, MC, USN CDR, MC, USN Lt Col, MC, USA
 (497831) (489878) (04-043-322)

**SUPPLEMENTARY REPORT OF AUTOPSY
 NUMBER A63-272—PRESIDENT JOHN F. KENNEDY
 PATHOLOGICAL EXAMINATION REPORT No. A63-272**

Gross Description of Brain

Following formalin fixation the brain weighs 1500 gm. The right cerebral hemisphere is found to be markedly disrupted. There is a longitudinal laceration of the right hemisphere which is parasagittal in position approximately 2.5 cm to the right of the midline which extends from the tip of the occipital lobe posteriorly to the tip of the frontal lobe anteriorly. The base of the laceration is situated approximately 4.5 cm below the vertex in the white matter. There is considerable loss of cortical substance above the base of the laceration, particularly in the parietal lobe. The margins of this laceration are at all points jagged and irregular, with additional lacerations extending in varying directions and for varying distances from the main laceration. In addition, there is a laceration of the corpus callosum extending from the genu to the tail. Exposed in this latter laceration are the interiors of the right lateral and third ventricles.

When viewed from the vertex the left cerebral hemisphere is intact. There is marked engorgement of meningeal blood vessels of the left temporal and frontal regions with considerable associated subarachnoid hemorrhage. The gyri and sulci over the left hemisphere are of essentially normal size and distribution. Those on the right are too fragmented and distorted for satisfactory description.

When viewed from the basilar aspect the disruption of the right cortex is again obvious. There is a longitudinal laceration of the midbrain through the floor of the third ventricle just behind the optic chiasm and the mammillary bodies. This laceration partially communicates with an oblique 1.5 cm tear through the left cerebral peduncle. There are irregular superficial lacerations over the basilar aspects of the left temporal and frontal lobes.

In the interest of preserving the specimen coronal sections are not made. The following sections are taken for microscopic examination:

- From the margin of the laceration in the right parietal lobe.
- From the margin of the laceration in the corpus callosum.
- From the anterior portion of the laceration in the right

frontal lobe.

d. From the contused left frontoparietal cortex.

e. From the line of transection of the spinal cord.

f. From the right cerebellar cortex.

g. From the superficial laceration of the basilar aspect of the left temporal lobe.

During the course of this examination seven black and white and six color 4x5 inch negatives are exposed but not developed (the cassettes containing these negatives have been delivered by hand to Rear Admiral George W. Burkley, MC, USN, White House Physician).

Microscopic Examination

Brain.—Multiple sections from representative areas as noted above are examined. All sections are essentially similar and show extensive disruption of brain tissue with associated hemorrhage. In none of the sections examined are there significant abnormalities other than those directly related to the recent trauma.

Heart.—Sections show a moderate amount of subpericardial fat. The coronary arteries, myocardial fibers, and endocardium are unremarkable.

Lungs.—Sections through the grossly described area of contusion in the right upper lobe exhibit disruption of alveolar walls and recent hemorrhage into alveoli. Sections are otherwise essentially unremarkable.

Liver.—Sections show the normal hepatic architecture to be well preserved. The parenchymal cells exhibit markedly granular cytoplasm indicating high glycogen content which is characteristic of the "liver biopsy pattern" of sudden death.

Spleen.—Sections show no significant abnormalities.

Kidneys.—Sections show no significant abnormalities aside from dilatation and engorgement of blood vessels of all calibers.

Skin Wounds.—Section through the wounds in the occipital and upper right posterior thoracic regions are essentially similar. In each there is loss of continuity of the epidermis with coagulation necrosis of the tissues at the wound margins. The scalp wound exhibits several small fragments of bone at its margins in the subcutaneous tissue.

Final Summary

This supplementary report covers in more detail the extensive degree of cerebral trauma in this case. However neither this portion of the examination nor the microscopic examinations alter the previously submitted report or add significant details to the cause of death.

/s/
 J. J. HUMES, CDR, MC, USN, 497831
 6 December 1963

From: Commanding Officer, US Naval Medical School

To: The White House Physician

Via: Commanding Officer, National Naval Medical Center

Subj: Supplementary report of Naval Medical School autopsy No. A63-272, John F. Kennedy.

/s/
 J. H. STOVER, JR.

—Report of the President's Commission on the Assassination of President John F. Kennedy, Appendix IX: "Autopsy Report and Supplemental Report." Washington, DC: US Government Printing Office, 1964, pp 538-546.

J. A. M. A. - April 5, 1965

EDITOR of the JOURNAL OF THE AMERICAN MEDICAL ASSOCIATION discloses in a footnote having followed a letter-request for further information on President Kennedy's Adrenals (re "Addison's Disease" reports) that he wrote for the Autopsy findings to the chief of the Bureau of Medicine and Surgery, U. S. Navy on November 10, 1964.

Although the request was forwarded to the White House physician, no answer was received.

Letters

Carbarsones Toxicity

To the Editor:—It is interesting to have the report of carbarsones toxicity from Drs. H. J. Schwartz and H. Y. Donnenfeld (LETTERS, JAMA 191:678 [Feb 22] 1965). Toxic reactions to carbarsones have fortunately been few, in spite of the long-continued use of carbarsones for the treatment of amebiasis.

It would appear that the cases reported by Schwartz and Donnenfeld were clearly due to overdosage. When we introduced carbarsones for the treatment of amebiasis (JAMA 99:195-199 [Jan 16] 1932), we recommended that the dosage be 75 mg/kg of body weight in divided amounts over at least a ten-day period. We said: "Practically, this dosage amounts in the average adult to 0.25 gm twice daily for ten days." We cautioned specifically against using carbarsones in amoebic hepatitis, or in amounts that might cause symptoms or arsenic toxicity. We reported the minimal single lethal doses of carbarsones administered orally to be 150 mg/kg in guinea pigs, 200 mg/kg in rabbits, and from 200 to 250 mg/kg in cats. On repeated oral administration of carbarsones in a wide series of animals, including monkeys, 50 mg/kg daily for ten days caused no toxic symptoms, and there was no evidence of tissue injury on microscopic examination of the animals killed at this time.

We had cautioned about the possibility of carbarsones producing injury to the optic tract, since Young and Loevenhart had observed such injury in hexavalent arsenicals containing an amino group or substituted amino group in para position to the arsenic atom (J Pharmacol Exp Ther 23:107, 1924). It is interesting that no significant reports have appeared on injury to the optic tract as a result of using carbarsones for the treatment of amebiasis.

It should also be pointed out that in one of the cases reported by Schwartz and Donnenfeld, emetine had been used in addition to carbarsones. Emetine is a relatively toxic alkylid, and is slowly excreted with resulting accumulation. There is experimental and clinical

evidence of injury to the heart from therapeutic doses of emetine, but there is no evidence that emetine can cause serious cerebral disorder.

The comment by the editor in connection with the letter of Schwartz and Donnenfeld is important in calling attention to the weight factor in the patients reported. Certainly in both reported cases, the amount of carbarsones administered was greatly in excess of what had been clearly recommended on the basis of solid experimental and clinical evidence a third of a century ago.

CHAUNCEY D. LEAKE, PhD
San Francisco

Medical Typists' Course

To the Editor:—Would you like to have a secretary who—

Thinks like a man,
Acts like a lady,
Looks like a model,
But works like a dog?

This anonymous motto has been adopted by the Medical Typists' Course, a program designed to give physicians better-trained medical secretaries. The lengthy transitional period from general secretary to qualified medical secretary is unfair to both employer and employee. Let's do something about it!

This problem is with us for a very good reason: Who is training the medical secretary? Almost no one. People within the medical profession are too busy to lend a hand here; people outside the medical profession don't know how. The responsibility actually lies with business teachers, but very few want to attempt material for which they themselves had no training.

On May 15 an educational forum on "Teaching the Medical Typists' Course" will be held at the Medical College of Georgia. Educators from vocational schools, large high schools, YWCA's, business schools, colleges, and hospitals are invited to attend. This forum will be followed up by a one-week teacher-training program in the summer.

The Medical Typists' Course includes all the subjects that seem necessary to turn out a finished product in this field: medical terminology, medical typing, speed typing, dictating machine transcription, and business English, etiquette, and dress. This course is the result of eight years of experimentation between Augusta Vocational School and the medical profession in the Savannah River Area. The

Medical Association of Georgia has appointed a committee to assist in piloting this course in other schools in Georgia next September.

If you would like the course set up in a school near you, contact the administrator in that school and ask him to bring a prospective teacher to the forum. If your own secretary needs further training but has no time for classroom instruction, her needs can be met by the correspondence course. For further information, write P.O. Box 3716, Augusta, Ga.

(Mrs.) FRANCES W. EDMONDSON
Author, Medical Typists' Course
Augusta, Ga

Official Autopsy Report on President Kennedy

To the Editor:—I read with dismay in the Feb 15, issue of THE JOURNAL, and subsequently in our free press, that officials have not disclosed any information about President Kennedy's adrenals (LETTERS, JAMA 191:402). Can the "officials," whoever they are, deny the right of the electorate to know whether the adrenals significantly altered the President's health or the nation's history? It is my belief that the complete findings at postmortem of a martyred president are public property.

We hear much today from Washington about "managed news" and "planted news." Now we have "no news," and this is worse, because we are left with nothing in history from which to make a start in understanding the problem. We should at least have the right to know who the undiscloseders are.


MD, New Jersey

On Nov 10, 1964, an inquiry was addressed to R Adm E. C. Kenney, Chief, Bureau of Medicine and Surgery, US Navy, asking for "any information as to the autopsy findings on the adrenal glands and, if possible, a complete protocol of the autopsy findings for future reference."

The request was forwarded to the White House Physician, R Adm George G. Burkley, MC, USN, to whom complete protocol had been submitted by the Navy pathologists and from whose office the official report, lacking mention of the adrenals, had been released to the nation. THE JOURNAL waited three months for pertinent information regarding the adrenals; received none.—Ed.

ADDISON STAIRS
JAMA

FIRST CLASS



Mr. Arthur Price
Pennsylvania General Paper Corp.
225 West 34 Street
New York, N. Y. 10001

Mr. Harold Weisberg
Coq d'Or Press
Route 7
Frederick, Maryland 21701

FIRST CLASS