


Observations Based on
A Review of the Autopsy Photographs,
X-Rays, and Related Materials
of the Late



President John F. Kennedy

John K. Lattimer, M.D., Sc.D.

College of Physicians and Surgeons, Columbia University, New York, N.Y.

Autopsy Findings on John F. Kennedy

□ On 22 November 1963, President John F. Kennedy was fatally shot in Dallas, Texas at 12:31 p.m., towards the end of a pre-election motorcade.

Probably the last coherent words he heard before his life was snuffed out were from a

This article is copyrighted 1972 by Resident and Staff Physician and Medical Times, Port Washington, N.Y. This may not be reproduced, quoted, or paraphrased in whole or in substantial part without the written permission of the copyright owners. Such permission will be granted to qualified publications.

relieved Mrs. Connally, the Texas governor's wife, who had turned to him from her seat ahead of Mrs. Kennedy in the automobile to say, "Mr. President, you can't say now that Dallas doesn't love you."¹ Seconds later he was shot through the neck, and then through the brain.

The President was declared dead at 1:00 p.m., after valiant, vigorous but hopeless attempts at resuscitation, which have been de-

WHY WAS DR. LATTIMER, A UROLOGIST, GIVEN THE FIRST NON-GOVERNMENT LOOK AT

This question is asked so often that it seems worthy of comment. The following factors may have influenced the decision by Mr. Burke Marshall whom Dr. Lattimer has never met. (Neither does he know the Kennedy family.)

The fact that he is a urologist is irrelevant. The detailed ballistic experiments that he, his sons and his staff have done over the years, to investigate some of the questions raised about the Kennedy assassination, are relevant. These experiments have been written up for the scientific literature at intervals since the President's death,^{10, 11} in addition to several historical studies^{4, 27, 28, 29} relating the analogies between Presidents Lincoln and Kennedy, as valuable teaching materials.

Dr. Lattimer is also the director of a large medical research organization at the Columbia-Presbyterian Medical Center in New York. His department has its own highly specialized x-ray department and its own pathology department, large enough to own and operate three electron microscopes, for example.

During the eight years he has worked on this problem, *Dr. Lattimer has accumulated one of the world's largest archives of original materials pertinent to the Lincoln and Kennedy assassinations.* For instance, he owns Oswald's rifle score

book from the Marine Corps (Fig. 10) and a large number of the actual letters and exhibits from both the Lincoln and Kennedy investigations. Thus, he does not have to depend on hearsay about the contents of these items.

In World War II, Dr. Lattimer was a military surgeon in the ETO and had experience with military missile wounds of all types, almost always using x-rays for their localization. He served as a firearms range officer and also did experimental work on the wounding capabilities of various missiles on human tissues.

He has firing facilities available on a family farm, where he and his sons could conduct their experiments^{10, 11} in an unhurried manner. Mrs. Lattimer helped with the illustrative work.

While serving as a visiting professor at Southwestern Medical School in Dallas, he sat on a box in the actual window from which Oswald was said to have fired. This made him realize from personal experience how relatively easy a shot it was. The storm of criticism against the Warren Report on this and other points still open to experimentation, surprised him and stimulated him to investigate many of these points by trying them himself. For example, when the ammunition was said to be unreliable, he procured and tested

*Crabtree to make
 a drawing of the neck wound
 from the Warren Commission
 report. The drawing is a
 courtesy of the
 National Archives.*




FIGURE 1

FIGURE 1 (Above): THE "OFFICIAL" DIAGRAM OF THE NECK WOUND, FROM THE WARREN COMMISSION REPORT—Done from verbal descriptions only, this diagram shows the neck wound to be less steeply downward than the actual photographs of the body showed it to be. (Courtesy National Archives.)

FIGURE 2 (Right): REVISED DIAGRAM OF THE NECK WOUND—This is still only a diagrammatic representation of the neck wound of President Kennedy. It is based on observations of the photographs and x-rays, but it is not a tracing. The National Archives requested that no tracings be made, so it is not precise. Its purpose is to clarify the relative positions of the wounds in the neck, and the various findings which, taken together, indicated that all were consistent with the entry of a bullet into the upper back, which ranged downward and medially through the base of the neck and exited low on the trachea in the midline, just below the

collar button, causing a "nick" on the knot of the necktie. These findings were as follows:

A. BULLET HOLE IN BACK OF SUIT-COAT AND SHIRT—The President's coat and shirt were probably "humped-up" on the back of his neck (see Fig. 4) when the first bullet struck him. The FBI found a "punched-in" round hole in the back of the coat consistent with a 6.5 mm bullet, with the broken cloth fibres bent inward, indicating that this was a wound of entry. The cloth fibres of the shirt were also bent inward in the same manner. Traces of copper from a bullet such as Oswald used, were found on the margins of this hole in the coat by the FBI, again indicating that it was a wound of entrance.

B. BULLET HOLE IN BACK—The bullet hole in the President's upper back, about two inches below the crease of his neck, and about two inches to the right of the midline, was slightly oval.

C. HALO AROUND BULLET HOLE—It had around it a faint but definite "halo," or circumferential

scribed in great detail elsewhere.² Remembering the attempt of Lincoln's assassins to kill his entire official family,^{3, 4} including Vice-President Andrew Johnson, the Presidential advisors removed his body in haste from the Parkland Hospital in Dallas at about 2:00 p.m., and placed it aboard the Presidential airplane to be returned to Washington with the Presidential group, including the new President and Mrs. Lyndon Johnson and Mrs. Kennedy.

The body was removed despite the vigorous protests of the highly competent Dallas medical examiner, Dr. Earl F. Rose.

Mrs. Kennedy, because of the President's love of, and service in the Navy, chose the Bethesda Navy Medical Center for the autopsy,⁵ which was begun at about 8:00 p.m. on the same day, after x-rays and photographs of the body had been taken. It was completed by 11:00 p.m. by Commander James J.

THE RESTRICTED KENNEDY MATERIAL?

500 rounds of the exact lots used by Oswald. (The FBI had tested 100 rounds.) When the rifle was said to be inaccurate or incapable of a high rate of fire, he tested several himself, and published the results.^{10, 11} *He has probably fired more Oswald-type cartridges in Oswald-type rifles at Oswald-type mock-ups than any other person, including Oswald.*

He had the capability to acquire and test four rifles and telescopes exactly like Oswald's (which he had examined in detail at the National Archives). He has published the results of his experiments to show that the so-called "pristine" bullet (exhibit 399) that the Warren Commission thought penetrated both President Kennedy and Governor Connally was not "pristine" at all, and that the four fragments in Governor Connally (plus the two now known to be present in President Kennedy) are by no means too many to be accounted for by the two grains of weight lost by this bullet. Dr. Lattimer was able to make 41 such fragments out of the two-grain sample of bullet in question.¹⁰ These experiments were conducted and published with the advice and help of pathologist Myron Tannenbaum and roentgenologists William Seaman and Joshua Becker at Columbia. The author also turns without hesitation

to his mentor, N. Y. Medical Examiner Milton Helpert, for expert advice and help. Whether the author's work with adrenal gland disorders was considered as a factor in the selection of a reviewer, is not known.

Incidentally, it should be remembered that three of the country's top forensic pathologists had already reviewed this material (in 1968), along with a top roentgenologist, and they had already published a technical report about it.⁹

Dr. Lattimer still had doubts about some of the contentions of the Warren Commission (as brought out in the text) which he hoped could be settled by viewing these autopsy photographs and x-rays. Otherwise, he says, he would not have gone to the trouble and personal expense of applying, corresponding and traveling to look into the matter further.

The fact that every controversial question or suspicious finding which the author has undertaken to investigate to date, has turned out to reveal no important discrepancy with the contentions in the Warren Report, in no way implies that Dr. Lattimer would not quickly publish any contrary findings, if they were discovered.

CHARLES A. RAGAN, JR., M.D.
Editor-in-Chief

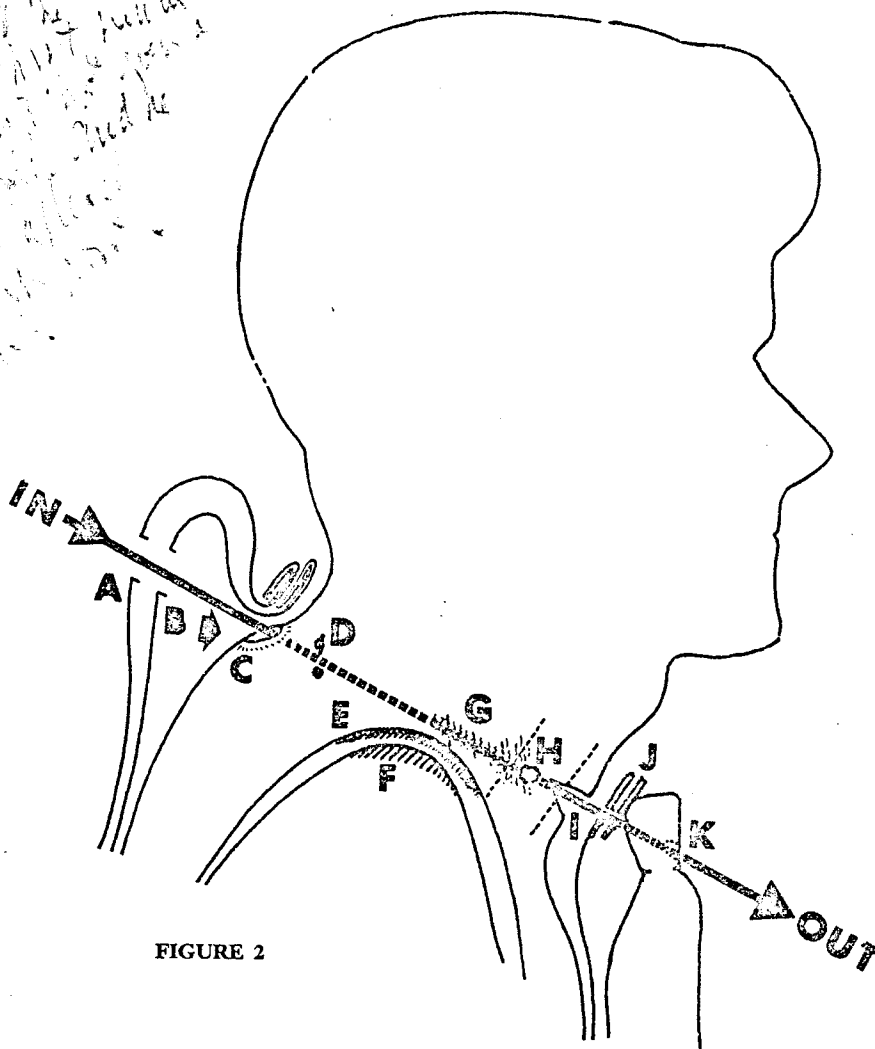


FIGURE 2

bruise, typical of a "wound of entry" from a high-speed bullet.

D. BULLET FRAGMENTS IN NECK—Two tiny 2 and 4 mm slivers of metal could be seen in the upper (rear) area of the bullet track, on the A-P x-ray film of the right shoulder and neck area. Since no lateral x-ray film was taken of this area, it was possible to determine only that they lay near the high (rear) end of the bullet track, but not the exact distance they lay from the surface. They were near the tip of the transverse process of the seventh cervical vertebra which the bullet may have grazed. They are represented diagrammatically only.

E. & F. PLEURA AND LUNG BRUISED—The autopsy report described a 5 cm bruise on the dome of the right pleura and also on the upper tip of the right lung (but no perforation of either), compatible with the passage of a high-speed bullet close above this point.

G. AIR IN TISSUES—There were tiny traces of

air, visible in the x-rays, in the tissues along the bullet track, near the hole in the trachea.

H. HOLE IN TRACHEA—There was a ragged hole in the right side of the trachea, seen by the surgeons at Parkland.

I. TRACHEOSTOMY—There was a gaping, 6.5 mm transverse tracheostomy incision low on the neck, where the Dallas surgeon, Dr. Perry, had enlarged the bullet hole in order to insert a tracheostomy tube.

J. HOLES ON FRONT OF SHIRT—There were 1 cm vertical slits in both sides of the overlapping portion of the shirt, immediately below the collar band, and touching it, just below the collar button.

K. NICK IN NECKTIE—There was a "nick" or "crease" through only the outer layer of fabric of the lower left side of the knot of his necktie, compatible with the passage of a spinning 6.5 mm bullet at high speed. A "blood stain" extended downward from this "nick."

Autopsy Findings on John F. Kennedy




FIGURE 3 (Above): FLATTENED BULLET (WC 399) THAT PIERCED THE PRESIDENT'S NECK, ACCORDING TO THE WARREN COMMISSION'S THESIS—This is the so-called "pristine" bullet, which in reality is far from pristine. (Courtesy National Archives.)

FIGURE 4 (Right): EXPLANATION FOR THE LOW LOCATION OF THE BULLET HOLE IN THE BACK OF THE SUIT-COAT—A photograph of President Kennedy taken a few minutes before he was shot, showing his suit-coat "humped-up" behind his neck. If his coat and shirt were in this configuration when he was hit, probably due to his waving, which he appears to have been doing, this could account for the fact that the bullet holes in his coat and shirt were farther down from his collar than was the corresponding bullet hole in his back (a point about which there has been some confusion and argument). (Photograph courtesy of Dallas Times Herald, Dallas, Texas).

Humes, M.C., U.S. Navy, Commander J. Thornton Boswell, with Lt. Colonel Pierre Finck, U.S. Army, in consultation. Dr. John H. Ebersole was also present and helped take the x-rays. The body had a bullet hole in the upper back at the base of the neck (Fig. 2), a recent tracheostomy wound, and a massive head wound, plus incisions for intravenous and chest tubes, which had been started as part of the resuscitative efforts. The doctors performing the autopsy in Bethesda at first had no way to

know that there had been a bullet hole in the front of the neck at the site of the tracheostomy and that a tracheostomy tube had been inserted through this opening at Dallas, after its transverse surgical enlargement by Dr. Malcolm Perry, until they talked to Dr. Perry on the telephone early the following morning.⁶ Since the President's body had never been turned over during the desperate attempts to resuscitate him at Dallas, and since the body had been removed so quickly, the doctors at

From 627, 628, 629, 630, 631, 632, 633, 634, 635, 636, 637, 638, 639, 640, 641, 642, 643, 644, 645, 646, 647, 648, 649, 650, 651, 652, 653, 654, 655, 656, 657, 658, 659, 660, 661, 662, 663, 664, 665, 666, 667, 668, 669, 670, 671, 672, 673, 674, 675, 676, 677, 678, 679, 680, 681, 682, 683, 684, 685, 686, 687, 688, 689, 690, 691, 692, 693, 694, 695, 696, 697, 698, 699, 700, 701, 702, 703, 704, 705, 706, 707, 708, 709, 710, 711, 712, 713, 714, 715, 716, 717, 718, 719, 720, 721, 722, 723, 724, 725, 726, 727, 728, 729, 730, 731, 732, 733, 734, 735, 736, 737, 738, 739, 740, 741, 742, 743, 744, 745, 746, 747, 748, 749, 750, 751, 752, 753, 754, 755, 756, 757, 758, 759, 760, 761, 762, 763, 764, 765, 766, 767, 768, 769, 770, 771, 772, 773, 774, 775, 776, 777, 778, 779, 780, 781, 782, 783, 784, 785, 786, 787, 788, 789, 790, 791, 792, 793, 794, 795, 796, 797, 798, 799, 800, 801, 802, 803, 804, 805, 806, 807, 808, 809, 810, 811, 812, 813, 814, 815, 816, 817, 818, 819, 820, 821, 822, 823, 824, 825, 826, 827, 828, 829, 830, 831, 832, 833, 834, 835, 836, 837, 838, 839, 840, 841, 842, 843, 844, 845, 846, 847, 848, 849, 850, 851, 852, 853, 854, 855, 856, 857, 858, 859, 860, 861, 862, 863, 864, 865, 866, 867, 868, 869, 870, 871, 872, 873, 874, 875, 876, 877, 878, 879, 880, 881, 882, 883, 884, 885, 886, 887, 888, 889, 890, 891, 892, 893, 894, 895, 896, 897, 898, 899, 900, 901, 902, 903, 904, 905, 906, 907, 908, 909, 910, 911, 912, 913, 914, 915, 916, 917, 918, 919, 920, 921, 922, 923, 924, 925, 926, 927, 928, 929, 930, 931, 932, 933, 934, 935, 936, 937, 938, 939, 940, 941, 942, 943, 944, 945, 946, 947, 948, 949, 950, 951, 952, 953, 954, 955, 956, 957, 958, 959, 960, 961, 962, 963, 964, 965, 966, 967, 968, 969, 970, 971, 972, 973, 974, 975, 976, 977, 978, 979, 980, 981, 982, 983, 984, 985, 986, 987, 988, 989, 990, 991, 992, 993, 994, 995, 996, 997, 998, 999, 1000

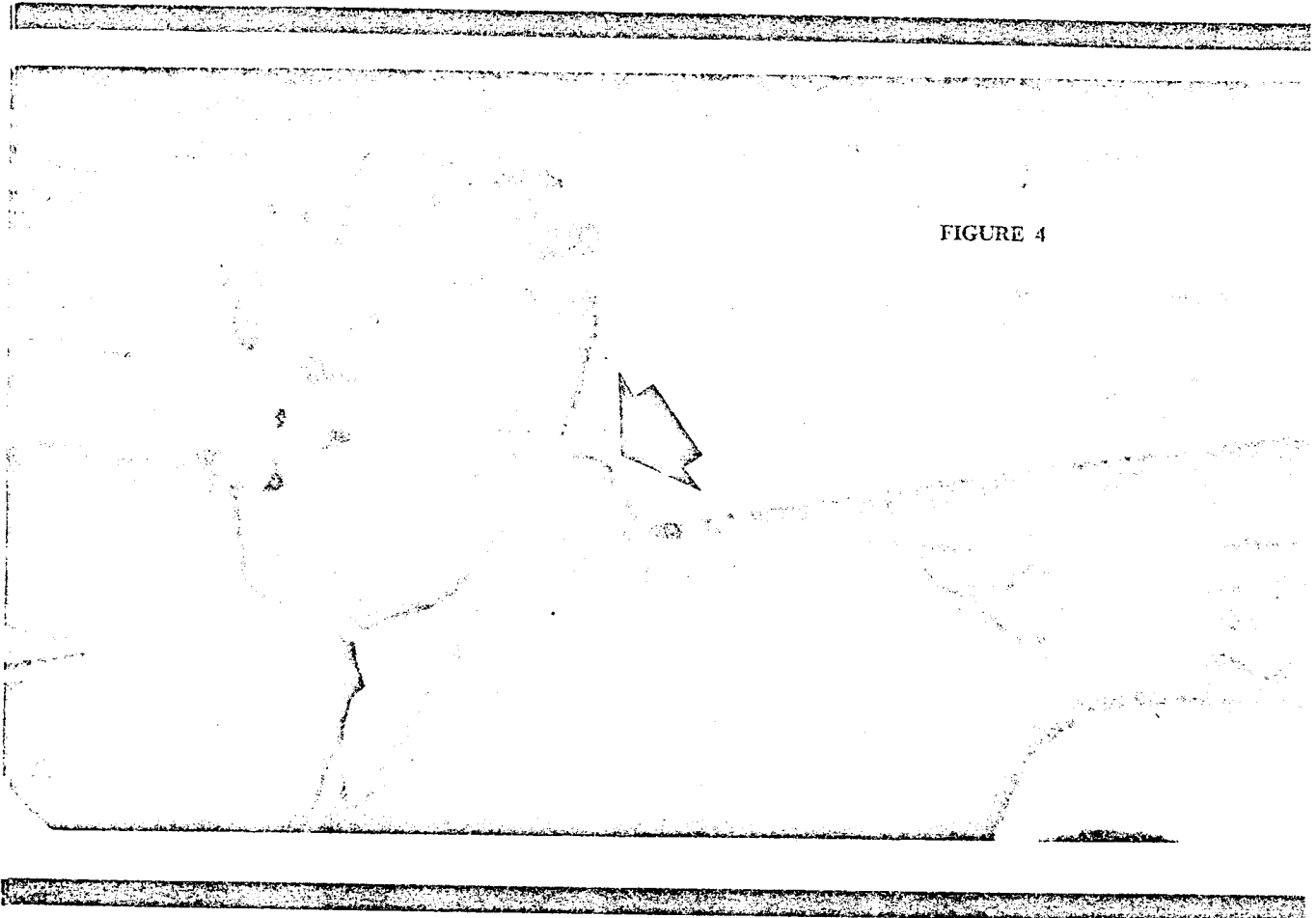


FIGURE 4

Dallas, in turn, had not known that there was another bullet hole in the upper back. This had led people in Dallas to speculate that the wound in the front of the neck, because it was small, might have been a wound of entrance.

It was some time before all of this information could be sifted out by long distance telephone calls between the two groups of doctors. Meanwhile, their speculations were overheard and quoted, leading to many erroneous rumors, just as in the case of President Lin-

coln, where it was at first rumored that the bullet came from the opposite direction.²⁹ During the course of the autopsy, three fragments of skull (Fig. 7) arrived from Dallas, which had been picked up in the street. The largest of these was triangular, approximately 6.5 x 7.5 x 9 cm. Another was about 2.5 cm square and the third about 1.5 cm square. The largest fragment bore about a dozen very tiny metallic fragments at one corner, around a semi-circular "bevelled" defect, and the 9 cm

7

Autopsy Findings on John F. Kennedy

dimension was irregular and meandering along its margin in a manner suggesting that it was a part of a "suture" line where two portions of the skull had joined. Whether this was from the sagittal suture or the one between the frontal and parietal bones, could not be determined. The aggregate area of these fragments accounted for a major part of the missing area of the skull and these appeared to be the fragments which could be seen going forward and upward away from President Kennedy's head in frame 313 of the Zapruder movie, at the moment the second bullet struck him.²⁵

Lt. Col. Pierre Finck, M.C., U.S. Army, who participated in the autopsy, has been quoted in 1968 in the newspapers⁷ as saying under interrogation in New Orleans, that the autopsy would not qualify as a "complete" autopsy by the standards of the American Board of Pathology because of certain restrictions which were imposed.⁷ Here again was a similarity to President Lincoln's autopsy, wherein only the head was examined.²⁹ Col. Finck alleged that one of these restrictions was a request that the doctors should not dissect out the entire bullet track through the base of the neck on the right side.

The adrenal glands were not mentioned in the autopsy report⁸ and no comment has appeared about them prior to this writing.

Why the Pictures Were Not Shown

The large 8 x 10 color prints, transparencies, and black and white prints of the photographs taken of the President's head and shoulders from every reasonable angle, just before the start of the autopsy, and of his brain and brain case, as the examination progressed, were recognized as being so potentially shocking to the family, and to persons not accustomed to viewing such things, that they were not even shown to the Warren Commission

members, since all official exhibits automatically would have become part of the published report. The undeveloped negatives and the developed x-rays, which the doctors had taken for the purpose of reference, in anticipation of using them in preparing an accurate and detailed autopsy report, were ordered turned over to the FBI before development. These photographs were not seen, even by the men who did the autopsy and took the pictures, until three years later. They were kept in privacy by the family until 1966, when they were turned over to the National Archives with a strict contractual-type agreement, stating that they should never be permitted to be on public display and that only after five additional years should specified qualified medical experts be permitted to study them. Even then, additional restrictions and reservations were stipulated.

While the Warren Commission itself did not view these exhibits, because of the above factors, properly authorized government officials were to be permitted to see the photos and x-rays and did so on two occasions, once in 1966, when the physicians who performed the autopsy authenticated the pictures, and once again in 1968 when a panel of three of the country's top forensic pathologists, Dr. Russell S. Fisher, Dr. William H. Carnes and Dr. Alan Moritz, together with a top roentgenologist, Dr. Russell H. Morgan, reviewed them for the then Attorney General Ramsey Clark and issued a technical report about them, couched in proper medical terms and widely reproduced in the newspapers.⁹ The author wishes to fully acknowledge this report by forensic experts.

Since the publication of the Warren Commission Report and the disbanding of the Commission, critics have raised many questions, both old and new, about the assassination. The interest in President Kennedy's death has remained keen, even in foreign countries,

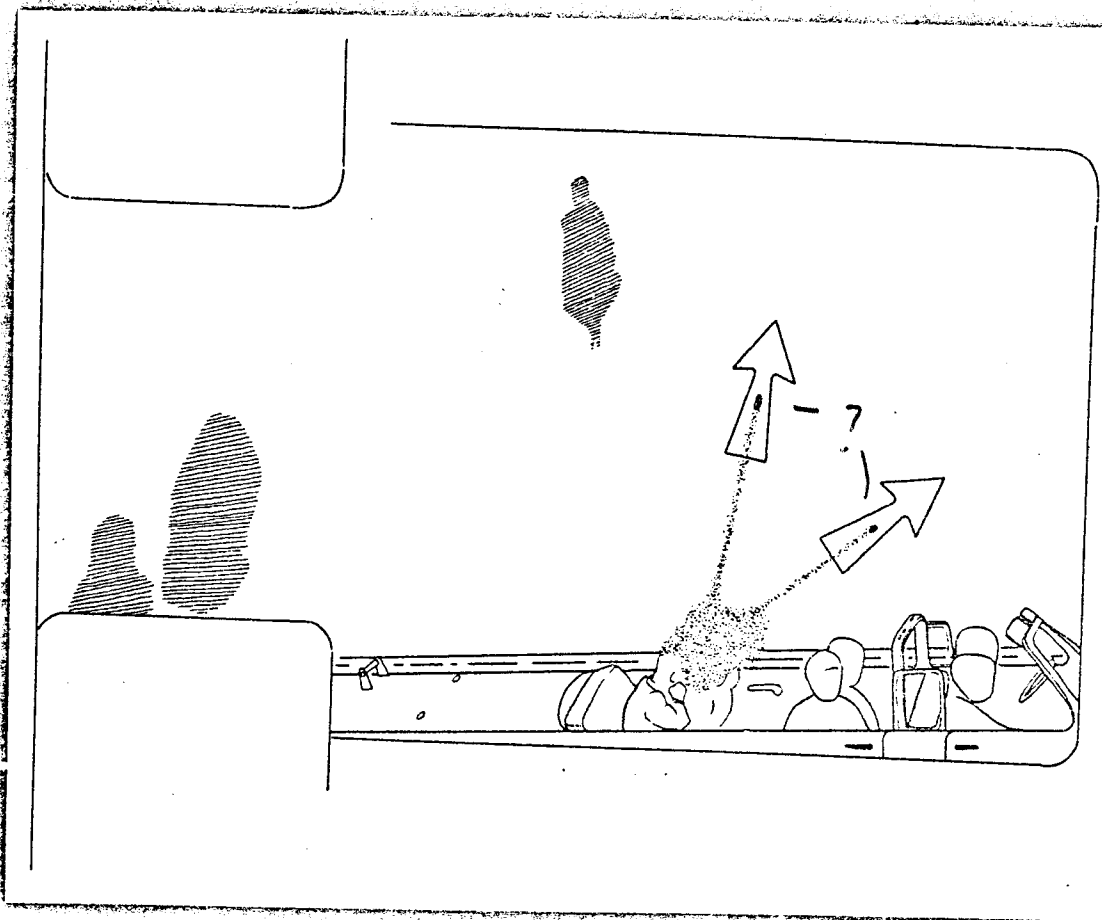


FIGURE 5: SECOND BULLET STRIKES PRESIDENT'S HEAD—This drawing from frame 313 of the Zapruder movie shows the exact moment of impact of the second bullet to strike President Kennedy (in the back of the head). Fragments of his skull and a cloud of brain tissue can be seen being driven forward and upward, away from his head, by the impact of the bullet. It seems probable that among these were the three pieces of skull picked up in the street later and shown in Fig. 7.

The pieces can be seen going six or eight feet in the air, so it is not surprising that the motorcycle police escort, just behind the car, rode forward into this cloud of "exploded" brain tissue and were spattered on their fronts by it, as it descended. Governor and Mrs. Connally both commented in their testimony, about being spattered with President Kennedy's brain tissue, in fragments as large as their fingers. (Drawing permitted, courtesy of Life Magazine and the National Archives).



FIGURE 6

FIGURE 6 (Above): "OFFICIAL" DIAGRAM OF THE HEAD WOUND, FROM THE WARREN COMMISSION REPORT—Admittedly done from hearsay, this drawing shows the wound of entrance in the back of the head to be about 3 inches lower than the photographs and x-rays show it to be and the head wound of exit to be much less shattering than the x-rays showed it to be. The exit wound in the head had to be even worse than this diagram if it was from a rifle like Oswald's. (Courtesy National Archives.)

FIGURE 7 (Right): REVISED SCHEMATIC DIAGRAM OF THE HEAD WOUND—Here again, this is only a diagrammatic representation of the head wound of President Kennedy, not a tracing. Its purpose is to clarify the relative sizes and positions of the various components of the wound, the locations and approximate sizes of the bullet fragments in the tissues and the magnitude of the damage, in order to show that the extent of the damage to the head was appropriate to the great power of the weapon the Warren Commission alleged was used (by Oswald). The components are as follows:

A. THE WOUND OF ENTRY—The ovoid "wound of entry" was fairly high up on the back of the

skull, well above the hairline, where the skull was starting to curve forward, and about 10 cm above the occipital tuberosity. (Oswald came within a few centimeters of missing the President.) The bone at the lower margin of the hole was depressed slightly and the wound in the inner table was characteristically larger than the wound in the outer table (cone shaped), exactly as one would expect from a "wound of entrance" into the back of the skull.

B. BULLET FRAGMENT SHAVED OFF BY SKULL EDGE—A (6.5 mm diameter) fragment of the bullet had been sheared off by the sharp edge of the thick bone of the skull and was embedded in the margin of the wound of entrance. Similar to the shaved-off fragment in President Lincoln's head (although a bit smaller), this fragment was the largest one left in President Kennedy's head.

C. LARGE WOUND OF EXIT IN TOP OF SKULL—A large, roughly pentangular area of the skull (about 15 cm x 13 cm) had been carried away by the force of exiting fragments of the disrupted bullet.

D. E. F. FRAGMENTS OF SKULL—Three fragments of skull picked up in the street at Dallas accounted for a majority of the area of bone that was missing, and were probably the fragments seen leaving the

10 cm =
3" ?

3"
 Not in Report

7

1.8 cm
show
occur?

Where is
bullet hole
at 52
Crown angle
2.5
53, " "

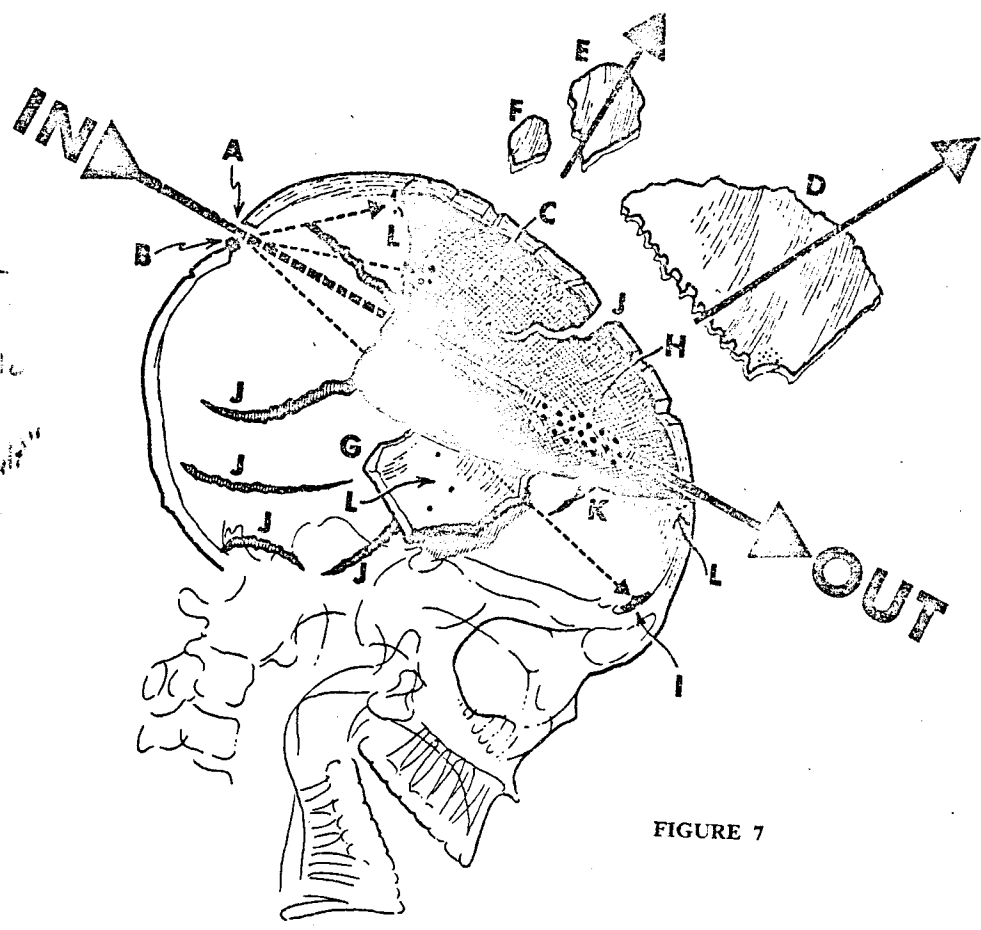


FIGURE 7

head in a forward-upward direction in frame 313 of the Zapruder movie of the shooting (see Fig. 5).

G. EVERTED FLAP OF SKULL AND SCALP—An additional flap of skull and scalp appeared to be everted and hanging down in front of and above the right ear but had not become detached. It had three tiny metallic fragments embedded in it, each about 1-2 mm in size.

H. CLUSTER OF FRAGMENTS—An elongated (4 cm) cluster of about 19 tiny metallic fragments in the front of the head was scattered along a line from the anterior edge of the large head wound of exit, back in the direction of the wound of entrance. Four or five similar tiny metallic fragments were embedded in the bone near the anterior edge of the wound of exit and a half-round 1 cm notch in the corner of the largest loose fragment of skull also had a crescent of tiny metallic particles arranged around it.

I. BULLET FRAGMENT IN FRONT OF BRAIN—The second largest metallic fragment (7 mm x 3 mm but crescentic) had come to rest in the front margin of the brain just above the top of the frontal sinus on the right.

Several other tiny fragments were scattered between the wound of entry and the wound of exit. There were *no* metallic fragments in the left side of the brain case.

All the metallic fragments on the right side were above a line between the wound of entry and the top of the frontal sinus, and the majority were in front and top of the brain case.

J. HUGE SKULL FRACTURE LINES—Multiple huge fracture lines extended from the margins of the large wound of exit, and smaller ones from the wound of entrance as well. These were compatible with the great force exerted by a heavy (160 grain) high-speed (2200 feet per second) military bullet on a thick part of the skull, and to have *not* found them would have raised doubts that he might have been shot with some other (less powerful) type of weapon. These multiple, devastating fractures in the base of the skull were very much in keeping with the type of weapon used by Oswald.

K. NOTCH IN FRONT OF SKULL WOUND

L. TINY BULLET FRAGMENTS SCATTERED THROUGH HEAD

Covers
F&CG
in 20p.

!!
?
?

Autopsy Findings on John F. Kennedy

where there was a great feeling of empathy for the late President.

No official mechanism for further investigation of these questions now exists, and the restrictions on viewing the autopsy evidence naturally added some impetus to the doubts of people who were impressed by the intensity of some of the criticism and the lack of rebuttal, plus the lack of information about some portions of the autopsy findings.

Doubts About the Warren Commission

Some of the criticisms and doubts about the Warren Commission allegations dealt with questions of fact, such as "Were the rifle and ammunition competent to do what was alleged, or not?" Such questions were still open to experimentation by uninvolved investigators, although no governmental or other funds were available to re-check these or any other points.

The author had been surprised to hear it stated so many times that it was an "impossible shot" for Oswald to have accomplished, whereas it did not seem that difficult to him, once the author had visited Dallas and sat in the actual window used by Oswald. The author and his two young sons thereafter undertook a series of lengthy, unhurried, careful experiments to determine whether the shooting was indeed feasible, as alleged by the Warren Commission. These experiments have been reported in detail elsewhere,^{10, 11} and indicated that it should have been quite easy to accomplish.

While none of these experiments turned up any discrepancies on the particular points of fact which were investigated concerning the contentions of the Warren Commission Report, there were still certain questions in the mind of the author, such as, "Why the lack of sufficient downward angulation in the official Warren Commission diagram of the neck wounds?" (if Oswald had been the shooter), "Exactly what

was their direction," and was there any evidence at all of another missile in the body, which might have entered either from the back or from any other direction? Furthermore, the magnitude of the head wound, as shown in the diagram, did not match the expectations of the author as to the severity to be anticipated, if Oswald had been the shooter. The differences between the diagrams in the Warren Commission Report (Figs. 1 and 6) and the descriptions of the wounds in the testimony⁶ before the Commission and in the 1968 "panel" report⁹ seemed to require clarification. The author therefore applied for permission to study the autopsy x-rays and photographs in 1966 and again in 1968, this time under the mistaken assumption that the five-year restriction ran from the date of President Kennedy's death in 1963, rather than from 1966, when they were turned over to the National Archives. He was instructed to re-apply in 1971, which he did, submitting as references, reprints of his ballistic and other experiments, as published in the scientific literature, relevant to President Kennedy's assassination and also several of his publications on Lincoln's death.^{4, 10, 11, 27, 28}

He received a letter from Dr. James B. Rhoads, Archivist of the United States, dated 4 January 1972, stating that he had been granted permission to examine the autopsy photographs and x-rays, by Mr. Burke Marshall, Deputy Dean of the Yale Law School, who had been designated by the Kennedy family to decide which applicants would be granted permission to study the evidence. Dr. Rhoads invited him to make an appointment for the examination of these materials, and he conducted this examination throughout the entire day of 7 January 1972 under security conditions, at the National Archives. The only restriction imposed was that he should not trace or photograph any of the items.

O.K. to handle under contract?

Mr. n n & ball so for mulation - it's all right

not out - it's all right

not in time alone was stated - the what if he didn't
 just the U.S. by present day
 & he was wrong
 couple

what did Oswald have to do with "secretly" in a "secretly" "secretly"

not listed 14 June

Students of the Warren Commission Report have repeatedly raised certain questions, so that some of the queries in the author's mind as he approached this material were:

- Was the evidence actually persuasive, for or against the thesis that the wounds in the back and the front of the neck were indeed connected, as from a "through-and-through" bullet wound?

- Was there indeed evidence visible on the photographs or x-rays, to indicate which wounds might be "wounds of entry" or "exit," and possibly which direction the bullet was traveling, in each case?

- Was the downward angle of the alleged bullet track through the neck (which the Warren Commission contended was from "back-to-front") steep enough to be compatible with Oswald's high perch, or was it more "parallel-with-the-ground," as shown in the official schematic diagram¹³ in the Warren Commission Report? (Fig. 1)

- Was it possible that the above neck wounds could have been inflicted from in front, or from either side?

- Were the positions of the bullet holes in the back of the body and in the back of the coat (and shirt) so far apart as to be irreconcilable?

- Was there any evidence, such as wounds, deformations or tracks of metal fragments running in any direction other than "back to front" in President Kennedy's head or body, such as from either side, or from the front, to indicate that a third bullet might have struck him? If so, might it have come from the "grassy knoll" on his right, from the infield of Dealey Plaza on the left, or from the railroad overpass to his front?

- Were the extent and character of the scalp and skull "wounds-of-exit" severe enough to be compatible with those expected to be

caused by a high-powered military rifle bullet, as described in the testimony of Dr. Humes? Or were they relatively moderate, as depicted in the official diagrams¹² in the Warren Commission Report? (Fig. 6)

- Were there any findings relevant to the question: "In what direction did President Kennedy's head move after it was struck?"

The Restricted Materials

The restricted materials viewed at this examination consisted of large color prints, plus black and white prints, and color transparencies thereof, as follows:

- The head viewed from above (10 prints).
- The head viewed from the right and above to include part of the face, neck, shoulder and upper chest (9 prints).
- The head and neck viewed from the left side (7 prints).
- The head viewed from behind (4 prints).
- The cranial cavity with brain removed (4 prints).
- The back of the body including neck (4 prints).
- The brain viewed from below after its removal (4 transparencies). The brain from above, three views. Black and white negatives of these same views of the brain were also present.

The quality of almost all of these photographs was good, and in the very few instances where one photograph was slightly out of focus, a similar view usually was in focus. The 4 x 5 color transparencies were the sharpest of all, and provided the clue as to the proper orientation of the photos of the empty brain case, which were otherwise confusing. There was also a roll of "120" film which had been spoiled by unrolling it in the light and a nota-

1 legit.

1 legit.

Same deliberate deception

1st part 1967 2nd part 1968

Do marks show in section?

side-blows possible?

if hit head?

what are wounds?

are there any marks on the back of the head?

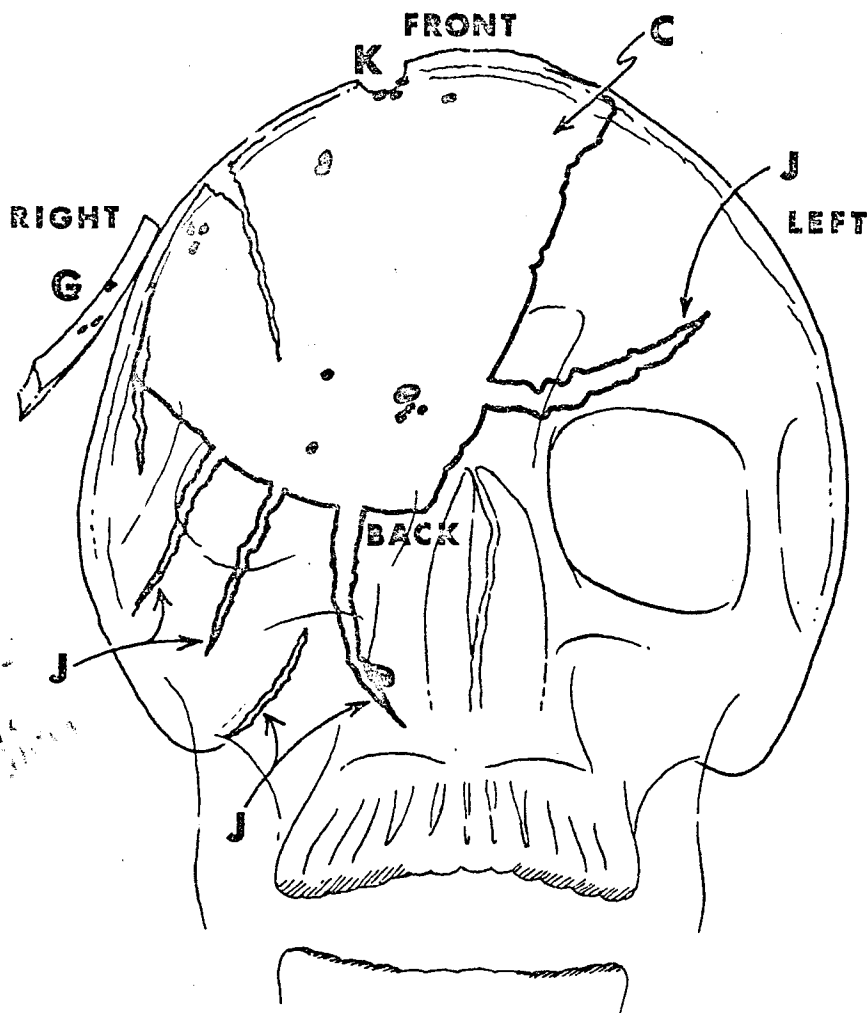
2nd part same defect 4 mm

In 1967/68 1968-1969

Why not left side? crown neck? there are more than one from head? last body? not to be in section? 4 views?

This is in... with... 120 film?

Autopsy Findings on John F. Kennedy



*Counties
entrance of
Cerebellum
w/ the skull
w/ the skull
w/ the skull
w/ the skull
w/ the skull
w/ the skull
w/ the skull
w/ the skull
w/ the skull
w/ the skull*

FIGURE 8: LOCATIONS OF THE BULLET FRAGMENTS IN THE PRESIDENT'S HEAD—This again is a diagrammatic sketch, not a tracing, from an AP x-ray of President Kennedy's head, to show that the locations of all the metallic fragments were confined to the right side of his brain case, and that there were no wounds not connected to the principal wound in the right side of the President's head. Letters identifying various components of the wound are correlated with the lettering in Figure 7.

auth

both
of
the
film
packs

both
of
the
film
packs
were
used

both
of
the
film
packs
were
used
for
the
x-rays

tion that this had been done deliberately by one of the agents present. There was no explanation of why the agent had done this, and one could only speculate that either the agent did not realize that photographs were being taken to assist in preparing an accurate autopsy report, or that he thought the photographer was not authorized to take such photographs.

There was also one 4 x 5 transparency which had been spoiled by overexposure, but with no clue as to what it was supposed to show. There was also one surplus film-pack of color film which appeared to be unexposed and unused.

In addition to the color and black and white prints there were the following x-rays, all of which bore the number 21296 and the name of the U. S. Naval Hospital, Bethesda, Maryland and the date 11-22-63:

- Film No. 1Skull, AP view
- Film No.'s 2, 3Skull, left lateral view
- Film No.'s 4, 5, 6Skull, three fragments of
- Film No.'s 7, 11Thoraco-lumbar region, AP view
- Film No. 8Right hemi-thorax, shoulder and upper arm, AP view
- Film No. 9Chest, AP view
- Film No. 10Left hemi-thorax, shoulder and upper arm, AP view
- Film No. 12Lower femurs and knees, AP view
- Film No. 13Pelvis, AP view
- Film No. 14Upper legs, AP view

X-ray film No. 1 had one 13 mm and one 7 mm scorch mark on it which did not affect its readability.

for what reading, police & forensic

X-ray film No. 2 had two diverging pencil lines on it which did not affect its readability.

The President's Clothing

The suit-coat, shirt, necktie and backbrace with its associated paddings and bandages, which he was wearing at the time he was shot, were examined in detail, along with close-up macro-photographs of the relevant segments of some of these.

The numbers of all of the materials inspected were checked against the list signed by the men who did the autopsy and also against the list signed by the members of the 1968 Forensic Panel and no omissions were detected, although there were some differences in labeling. The Forensic Panel had stated that their list conformed with the list in the document of transmittal from the Kennedy family in 1966. It was noted, however, that in none of the lists were there any photographs of the bruise on the pleura and apex of the right lung, even though photographs of the bruise on the lung and pleura were described by Commander Humes as having been taken.¹⁴ There was no way to know whether the spoiled roll of 120 film, or the spoiled transparency, had had this photograph on it, or what had happened to it. Since it was the only picture attempted of an interior, superior portion of the body cavity, it may well have been a problem in exposure and thus have been spoiled.

The bullets and bullet fragments, the Zapruder, Nix and Muchmore motion pictures, the rifle and other items had been carefully inspected many times previously, but were again examined in detail.

Relevant Facts Discernible in the Photographs

While exact measurements on a photograph or x-ray film could never be as accurate as measurements on the body itself, a few reason-

auth
both
of
the
film
packs

auth
both
of
the
film
packs

auth
both
of
the
film
packs

auth
both
of
the
film
packs

Autopsy Findings on John F. Kennedy

able approximations were possible and are used hereinafter. A few of the photographs showed a ruler laid against the wound areas.

By far the greatest benefit from the photographs and x-rays was the fact that one could see the relationships of the various wounds and fragments to each other and to other landmarks on the body.

On the upper back, just below the junction of neck and back, there was an ovoid penetrating wound estimated to be approximately 6 mm x 8 mm in size, with the longer axis transversely. It was compatible with a 6.5 mm bullet wound, and had a faint halo of discoloration around it, which was suggestive of a wound of entry from a high-speed bullet. The wound is estimated to lie about 5 cm to the right of the midline and approximately the same distance below the transverse double fold in the skin at the junction of the neck and back. This fold in the skin of the neck was very prominent, and may have been related to the thickening of the tissues of this area due to the cortisone derivative he is said to have taken. This bullet hole was recognizable as the wound described in the autopsy report as lying 14 cm medial to the tip of the right acromion process and 14 cm below the tip of the right mastoid process⁹ (Fig. 2).

There was a transverse tracheostomy wound about 6.5 cm in length and gaping open at least 1.5 cm at its widest (mid) portion. The tracheostomy wound in the front of the neck was at a lower level than the author had expected to see it. It was almost at the suprasternal notch, and its upper margin was seen to be far below the bottom of the transverse fold of skin of the neck, mentioned above, indicating that the (tracheostomy) wound of exit was substantially below the wound of entry on the back of the neck. The lower lip of the tracheostomy incision had a large crescentic indenta-

tion near its center, as if from the pressure of the "cuffed" tracheostomy tube inserted through it during the attempts at resuscitation. Dr. Malcolm Perry had indicated that he had created this wound by a transverse incision directly through a bullet hole in the front of the lower neck² at this location.

The 1968 panel of forensic pathologists stated in their report that they could detect, among the irregularities along the upper margin of this gaping tracheostomy incision, the semi-circular upper half of a "wound-of-exit" from a bullet. These photographs were not sharp enough nor close enough for the author to presume to join in this diagnosis of this particular point. However, the relative heights of the two wounds did make it quite obvious in the photographs that any bullet that might have exited through this hole had had a moderately but definitely more downward course through President Kennedy's neck than the course, relatively parallel with the ground, which had been depicted¹³ in the official schematic diagram (Fig. 1), made by an artist from verbal descriptions of the wounds rather than actual measurements, photographs, or a viewing of the body.¹⁵

Still another factor which made it difficult to describe the height of the wound on the back of President Kennedy's neck exactly, was the fact that the tissues at the back of his neck were more prominent than those of most people. This was possibly due partly to his manner of holding his shoulders very high, so that a "roll" of tissue was produced across the back of his neck and also perhaps because he was taking the cortisone derivative which may have caused a slightly greater-than-normal thickening of these tissues, as mentioned above. In any case, the actual photographs showed very clearly that the course of the bullet downward through President Kennedy's neck was a bit

not true. And
wound in location
about the same
location
This does not
appear to be
the same wound
as the one
described in
the autopsy
report
48

Should
have
been
more
downward
course
through
President
Kennedy's
neck
than
the
course,
relatively
parallel
with
the
ground,
which
had
been
depicted
in
the
official
schematic
diagram
(Fig. 1),
made
by
an
artist
from
verbal
descriptions
of
the
wounds
rather
than
actual
measurements,
photographs,
or
a
viewing
of
the
body.
In
any
case,
the
actual
photographs
showed
very
clearly
that
the
course
of
the
bullet
downward
through
President
Kennedy's
neck
was
a
bit




FIGURE 9: A REMNANT OF THE BULLET THAT PROBABLY CAUSED THE PRESIDENT'S HEAD WOUND (WARREN COMMISSION EXHIBIT NO. 569)—It is part of the deformed, empty copper jacket of a disrupted 6.5 mm bullet, found in the front seat area of the Presidential car, along with another fragment, Warren Commission Exhibit No. 567. (Courtesy National Archives.)

steeper than had been indicated by the Warren Commission's schematic drawing and that it was much more in accord with the possibility that the bullet was fired downward at President Kennedy (as it would have been if the shooter had been Oswald) from the sixth floor of the Book Depository Building. We realize that other references in the Warren Report indicate a steeper downward course than do the diagrams, but official "graphic" depictions have always commanded much attention.

The x-rays taken specifically of the area between these two bullet holes (which also included a hole in the trachea) showed tiny traces of air in the tissue planes (subcutaneous

emphysema) along the line between the two holes in the skin and trachea and also showed two tiny slivers of metal about 4 mm and 2 mm in length, along this same track, near its upper (rear) end. No gross fractures were visible, although a "graze" of the tip of the transverse process of the seventh cervical vertebra could not be excluded. It should be noted that in the autopsy report the dome (or apex) of the right parietal pleura was found to be ecchymotic and bruised, even though it had not been penetrated, and while the upper tip of the right lung was also slightly bruised, there was no evidence of any tear or "sucking" wound of the chest. The apex of the pleura would have

Autopsy Findings on John F. Kennedy

been immediately below the course of a track between these two holes in the neck. The "strap" muscles of the right side of the neck were reported in the autopsy description to be ecchymotic, even though there had been no ecchymosis or circular bruise recorded near the bullet hole, through which the tracheostomy wound had been made, on the front of the neck (Fig. 2).

Bullet Holes in Suit-Coat and Shirt

After viewing the photographs and x-rays of the bullet holes in President Kennedy's body, his suit-coat and shirt were examined. The coat was a light-weight, gray fabric which looked and felt like a "tropical worsted" in a "sack" weave. The collar, back and upper sleeves were stiff with a substance resembling dried blood. The sleeves had been slit open and the front panels had been cut across at the nipple line,¹⁹ as is common during emergency efforts at resuscitation.

The coat showed a roundish "punched-in" 8 mm hole in the back, compatible with the passage of a 6.5 mm bullet (Figs. 2 and 4) but with one-half of the circumference removed, along with an elongated area of the cloth, for analysis of the cloth fibres (which had shown traces of copper²¹ and also that these fibres had been bent inward, indicating that this was a wound of entry, according to the FBI laboratory tests).²¹ This hole was 13.3 cm below the upper edge of the collar and 4.5 cm to the right of the midline, in a position suggesting that it was somewhat lower than the wound of entry on the back of the neck. The jacket also had a second tiny penetrating hole just at the lower edge of the collar, through both jacket and lining, directly above the hole through which the bullet obviously entered. There was no such second hole in the back of the shirt at this higher location.

The back of the shirt had a single hole, about 6 mm long and 6 mm wide, about 14.5 cm below the upper edge of the collar and about 2.8 cm to the right of the midline. While the half of this hole that remained was still roundish and appeared indented in some parts of its circumference, the other half of the hole had also been removed, along with a 1 cm strip of adjacent cloth, for analysis (as for bending of the fibres or traces of metal, as described by the FBI laboratory expert, Robert Frazier.)²¹

Having seen these holes in the back of the coat and shirt, at their low locations, the author returned to his file of Kennedy photographs and found several of the President, taken shortly before he was shot, with his right elbow resting up on the edge of the automobile where he could wave more easily. This position caused his suit-coat to "hump-up" on the back of his neck (Fig. 4) so that it was easy to see that the bullet hole in the coat or shirt might well be at a lower point on either garment when the garment was laid out flat, in comparison to its position at the actual moment of impact, when President Kennedy was indeed waving to the crowds, with his right elbow elevated, as seen in the Zapruder movie.

Whether the higher "second" hole at the lower margin of the coat collar was a tangential wound of the cloth, due to a downward folding of this portion of the cloth, could not be determined, although this did at first seem possible. Why the shirt did not have a corresponding second hole, was not clear, however. On further inspection, it seemed probable that the second hole in the jacket was the site from which a "control" sample of cloth had been removed by FBI laboratory man Frazier, when the margins of the bullet hole in the coat were analyzed.²¹ In any case, it did not seem nearly so mysterious as has been implied, that the bullet holes in the back of the coat and shirt

were at lower positions than the bullet hole in the President's back, after seeing the actual photographs of the upward buckling of the cloth during the motorcade (Fig. 4).

The shirt was white with a thin triple gray stripe alternating with a thin triple brown stripe. The back, collar and upper arms were soaked with a dark, stiff substance resembling dried blood.¹⁸

It showed two vertical, slit-like penetrating "wounds" in the bloody area immediately below the collar band, and touching its lowest margin. The reason the fabric tore more in a vertical direction may have been that the bullet started to turn "nose-downward" as it left the skin of the neck at a downward angle, leaving "vertical" slits in the cloth. These had occurred in the area of overlap just below the button joining the two sides of the collar. The shirt was in "new" condition with strong fabric and strong thread holding the button on. It was not clear as to whether the margins of the two holes in the front of the shirt had been cut away to a minor extent for analysis. Even so, it was quite clear at this examination that no portion of either hole in the front of the shirt resembled the round "punched-in" holes usually seen with wounds of entry into clothing, whereas the remaining halves of the holes in the *back* of the coat and shirt still appeared "punched-in," despite their partial excision.

The Necktie

The necktie had been "nicked" on its outer layer only (but not penetrated) in a manner compatible with the tangential passage of a spinning slender bullet (Fig. 2) near the lower edge of the left side of the knot, as seen in the original photographs of the necktie.²⁰ The necktie was in an "untied" configuration when examined by the author, and in this configuration it could be seen that there was a smear of

some dried foreign material (resembling dried blood) extending at least 1 cm below this "nick," which should be analyzed for blood, if it has not already been so analyzed. It is possible that this stain was not readily visible when the necktie was in its original "tied" configuration. While it would not preclude the possibility that blood had merely dripped on the necktie from some other wound, the fact that it extended downward from the lower margin of the hole in the necktie was clear.

After examining the front of the shirt, one could conjecture that the reason the skin around the "wound-of-exit" in the front of the neck had not been more stretched out and ecchymotic, as if from an exiting bullet, was because the skin had been supported and kept from stretching, by the firm collar band, at that point. If the collar band had *not* been supporting it, the loose skin of the neck might have been stretched severely, ahead of the exiting bullet, thus producing more obvious tissue damage and ecchymosis, even though the actual wound of exit might still have appeared small, as the stretched skin snapped back into place. Thus, the confusion over the fact that the anterior neck wound was small enough to resemble a wound of entry to some extent, seemed more understandable. There was, moreover, no note of a "halo" or "bruise" either above or below the tracheostomy wound, which might have been still visible, despite the post-mortem tracheostomy, had such a bruise been present.

Question One

• Thus, to the question "*Was there evidence of a bullet track demonstrable between the wounds of the back and front of the neck?*" The answer was "Yes" but based on the circumstantial evidence that the metal fragments, the air in the tissues, the lack of visible frac-

Autopsy Findings on John F. Kennedy

tures, the report of a bruise on the apex of the pleura, and the hole in the trachea, all "lined-up" or "fitted-together" to indicate that a bullet had passed between the two holes in the back and front of the skin of the neck, even though any single one of these factors might not have been conclusive by itself. Any other course would have struck some bones solidly, causing gross fractures, which would have been visible in the x-rays. It *is* possible that the bullet grazed the tip of the transverse process of the last cervical vertebra without causing a visible fracture but leaving two tiny metallic fragments behind, and without turning the bullet.

• To the question: "*In which direction was the bullet going?*" The indications were strong and all pointed to a "back-to-front" direction. For example, the halo of discoloration around the wound in the back of the neck strongly indicated that site as a portal of entry.

The bullet hole in the anterior surface of the neck had been cut in two by the tracheostomy incision, so was not intact for study, but Dr. Malcolm Perry, who made that incision, had commented on the lack of distortion or discoloration around this wound, which might be explained by the fact that it was supported and contained by the strong collar band, as discussed above. Had it been a wound of entry, however, it would have almost surely had a "halo" or bruise around it, which Dr. Perry might have been expected to notice.

Previous analysis of the cloth around the bullet holes in the back of the suit-coat and shirt by the FBI had indicated that the bullet had entered from the rear.

More Questions

• To the question: "*Was the angle of the bullet track downward through the neck compatible with the high perch of alleged shooter Oswald?*" The answer was clearly "Yes," once

the photographs were seen.

• To the question: "*Was it possible that such a 'through-and-through' bullet wound in the neck could have been inflicted from the front?*" The photographs showed that to do this the shooter would have to have been squatting down very low inside the President's automobile, as if on the floor, in front of Governor Connally's position, in order to shoot upwards at the President's neck. This was clearly not so.

• To the question: "*Were the locations of the bullet holes in the back of the body and in the back of the coat and shirt so far apart as to be irreconcilable?*" The answer was that they were close enough so that the difference was compatible with the "humping-up" of the jacket and shirt on the back of the President's neck, when he waved. Numerous photographs were found which showed his jacket in this configuration in the period just before he was shot (Fig. 4).

The "Wound of Entry" in the Head

The head "wound-of-entry" could be clearly seen in four of the color photographs to consist of an ovoid penetrating wound of the back of the head about 7 x 15 mm in size, and about 2 cm to the right of the midline, high up above the hairline and where the calvarium was starting to curve forward. This accounted for its ovoid shape, since it was slightly tangential to the surface of the skull. The long axis of this ovoid wound ran in the anterior-posterior direction. It conformed in position to the hole in the back of the skull seen in lateral x-ray film No. 2. This position, clearly shown in the photographs, was considerably higher than that depicted in the schematic drawings of the head wounds in the Warren Report,¹²⁻²⁴ since it lay about 10 cm higher than the occipital tuberosity of the skull, rather than "just above

By business agencies by way of the book "The Assassination of President Kennedy".

it." It made it obvious that this bullet came within a few centimeters of missing the President's head altogether (Fig. 7).

The "Wound of Exit" from the Head

There was a very large, sanguineous, everting wound of the front half of the right side of the top of the head, with a very large segment of the top of the right half of the skull and scalp missing, from about the top margin of the frontal bone back for a distance of approximately 13 cm (5 inches). The defect extended roughly along the sagittal suture in the midline of the head, and must have taken away most of the right parietal bone. The area of this defect would have been mostly (but not entirely) matched by the area of the bone fragments retrieved later from the street, plus an everted skull flap which had not become detached, as nearly as one could tell from the photographs, and which appeared to be everted and hanging down immediately above and in front of the right ear. The anterior scalp appeared to have been greatly stretched by the force of the exiting bullet fragments and skull fragments, and then tore across the top of the front of the head in an irregular manner, with one long tear anterolaterally, about 2 cm above the frontal hairline and extending to the left of the midline. Another tear extended downward and outward to the right temple and then back above the right ear. Still other tears were described in the autopsy report, in more detail.⁸ The front edge of the scalp defect appeared to correspond approximately with the front edge of the large bony defect in the top of the skull and probably reflected the explosive outward force of the three large skull fragments, as the disrupted, powerful bullet fragments drove the skull segments forward and upward for a distance of 6 or 8 feet, as could be clearly seen in frame 313 of the "Zapruder" motion picture

(Fig. 5).²³ The eversion and then contraction of these flaps of expanded and everted scalp are visible for seven frames (frames 313 through 319) of the same movie. This is a familiar phenomenon with high-speed bullets which strike the head. The configuration and separation of these flaps of scalp could be caused only by skull fragments traveling upward, forward and slightly to the right, and in no other direction. Their magnitude was decidedly in keeping with the very powerful ammunition used in Oswald's rifle.

Confirmation From X-Rays

Another question in the mind of the author was why the official sketch of President Kennedy's head wound, placed in the Warren Commission Report,¹² contained no suggestion of the severe skull fracture lines which such a heavy, high-speed military rifle bullet would have been expected to create, not only in the calvarium, but also in the base of the skull. Seeing the actual x-rays revealed that the configuration and magnitude of such cracks were indeed such as one would expect from this high energy bullet. In fairness to Dr. Humes and Dr. Boswell (who did see the x-rays, but wrote up the autopsy under rushed, harassed and restricted conditions, without the help of the photographs they had ordered taken for reference purposes), their written autopsy description does mention these cracks.⁸ In his later, more detailed testimony before the Commission, Dr. Humes stated that these cracks were so many and so severe that the fragments of the skull came apart in his hands, so that little or no sawing of the calvarium was needed to remove the brain.¹⁶

• Thus, to the question: "*Were the extent, severity and character of the scalp and skull wounds compatible (severe enough) with those to be expected from a high-speed military rifle*

Autopsy Findings on John F. Kennedy

U. S. MARINE CORPS SCORE BOOK



for U. S. RIFLE, CALIBER .30, M1
and U. S. CARBINE, CALIBER .30, M1A1

Issued to

Rifle No.

Ronald L. A.
Organization

414015
Date issued

TV

NAVMC 42 P&P (Rev. 9-60)

16-00454-1

RIFLE

CARBINE

FIGURE 10: OSWALD'S MARINE CORPS SCORE BOOK—Pages show that on a Wednesday, Oswald scored 49 out of a possible 50, at rapid fire, from a sitting position, at 200 yards, with no telescopic sight. On the following Friday he scored 48 out of 50. Conclusion: Lee Harvey Oswald was very definitely marksman enough to have shot President Kennedy.

bullet?" The answer was "Yes" (Fig. 7).

The 1968 panel of forensic pathologists and a roentgenologist also had described the skull fractures in their report in even more detail.⁹ Here again, one might conjecture that perhaps the diagrams in the Warren Commission Report, while "official," were purposely made less revealing in an effort to make them less shocking to the public, and especially to the family of the President. It was here again ap-

parent and acknowledged¹⁵ that the artist drew them from hearsay instructions and without seeing the body, the photographs or the x-rays (Figs. 1 and 6).¹⁵

While the back of the calvarium retained its rounded contour, the x-rays revealed multiple cracks and a slight depression of the lower margin of the wound of entry in the skull. The wound of entry in the bone was "bevelled" into a typical "cone" shape, clearly indicating that

*Never solve
any of the
cases that
are in this
book. The
answers are
in the
back of the
book.*

200 YARDS RAPID

DATE	HIT	NO.	VALUE
ELEV. USED 6-0	5's		
CORRECT ELEV. 6	4's		
ZERO WIND 0	3's		
WIND VEL. 0	2's		
WIND DIRECTION 0	0's		
REMARKS	SCORE 78		

10-69454-1 (47)

200 YARDS RAPID

DATE	HIT	NO.	VALUE
ELEV. USED 6-0	5's		
CORRECT ELEV. 6	4's		
ZERO WIND 0	3's		
WIND VEL. 0	2's		
WIND DIRECTION 0	0's		
REMARKS	SCORE 41		

10-69454-1 (49)

Autopsy Findings on John F. Kennedy

the bullet entered from the rear of the skull. A similar, rounded "nick" in the upper border of the frontal bone, on the right, was also "bevelled" in a forward direction suggesting a wound of exit.

Radiating downward and outward from the margins of the large defect in the top portion of the skull there were several enormous cracks, some of which extended to the base of the skull, plus numerous others into the floor of the anterior and middle fossas on the right, plus another which extended outward into the left side of the calvarium from the margin of the major skull defect superiorly. It was undoubtedly these very large fracture lines which gave the "abnormal mobility of the underlying bones" of the frontal region which Dr. Humes mentioned in his handwritten autopsy report on page 33 of Volume XVII of the Hearings Before the Warren Commission. The configuration of these fracture lines again supported the thesis that the President was struck by a very high-powered rifle bullet (rather than some other less powerful type of bullet such as from a pistol) and that the bullet entered the skull from the rear and exited from the top front.

Bullet Fragments in the Head

The x-rays of the head taken before the start of the autopsy, revealed at least 35 small metal fragments, mostly less than 1 mm in diameter, scattered throughout the right side of the top of the head. The largest was a 6.5 mm rounded fragment stuck on the sharp margin of the bone at the wound of entry into the back of the skull. All of the metal fragments were confined to the right side of the brain area (Fig. 8) and all of the fragments were above an imaginary line drawn from the wound of entry through the top of the frontal sinus. This configuration was in keeping with the track of

a bullet entering at the rear of the right side of the back of the head, disrupting and exiting from the top front of the head on the right side. It was compatible with no other direction (Fig. 7).

There was one cluster of about 19 tiny metal fragments, each about the size of a grain of sand, which, while confined to the front third of the head, were arranged roughly in a line which, if extended posteriorly, would pass through the wound of entry in the one direction and through the lower (anterior) margin of the large skull defect in the anterior direction, if the line was extended forward. There were about six slightly larger metal fragments measuring 1-3 mm in diameter, in the region of the posterior margin of the large skull defect, and scattered through the tissues; there were three more tiny fragments about 1 mm in diameter which might have been embedded in the flap of skull which was hanging outward near the right ear. The second largest metal fragment of all, measuring about 7 mm in length by 3 mm in width and roughly crescentic in shape, had come to rest at the front margin of the brain, just above the superior margin of the right frontal sinus (Fig. 7). There was an additional cluster of about a dozen very tiny (1-2 mm) fragments of metal embedded in one corner of the largest fragment of skull, which was picked up from the street. There was a rounded "bevelled" defect in this same corner of this largest skull fragment, around which these dozen or so metal fragments were embedded. The margin of the frontal bone, at its right end, had a similar rounded, "bevelled notch" about 1 cm wide. While there was no immediate way to prove an association, these rounded "bevelled" defects or notches would have matched the approximate size of either the partial bullet jacket fragment, Exhibit No. 569,²² (Fig. 9) found

by the
medium
bullet - white
high
power

finding effect
single
bullet
not mentioned
in the report

at
front
= soft
bullet

frontal
bone

on the floor of the Presidential automobile along with some smaller particles,²³ or the partial bullet fragment, Exhibit No. 567, found on the front seat of the Presidential car.

The brain, when removed, showed a relatively intact-appearing left hemisphere, except for some surface hematoma over the frontal gyri adjacent to the main wound. From the right side of the brain, however, it appeared that approximately 70 percent of the right cerebral hemisphere was missing, with only a torn and flattened portion of the base of the right hemisphere remaining. This was compatible with the huge cavities which can be demonstrated to form in soft tissues such as the brain, in the high-speed photographs taken of bullets passing through soft tissues, by the Armed Forces Medical Research Teams. The cerebellum appeared to be intact despite rumors to the effect that cerebellar tissue was seen on the stretcher at the Parkland Hospital. There appeared to be lacerations of the base of the brain, as confirmed by the testimony of Dr. Humes.¹⁷

• Questions and doubts which had been in our mind prior to examining these x-ray films had been as follows: (1) *"Were there any holes, deformations, bullets, or tracks of metal fragments coursing transversely through the head, to indicate that a third bullet might have struck the President, or that a bullet might have hit him from the side, as from the 'grassy knoll' on the right side of the car, or from the 'infield' of Dealey Plaza, or from the railroad overpass to his front?"* After the study of the x-ray films and photographs, the answer was clearly "NO." No fragments, bullet holes or deformities could be seen to suggest any course of a bullet other than from "back to front" in either of the head wounds (Fig. 8). Certainly neither wound could have been made from the so called "grassy knoll" area on the right side

of the car. The flap of skull and scalp which had turned outward and downward, above the right ear, certainly could not have been caused by a bullet coming from the President's right side.

X-rays of the Remainder of the Body

• Still another question was: *"Was there any sign of a bullet, a missile wound or missile track in any part of the body other than the head and neck?"* The x-rays were again examined after the photographs, with this in mind. Again, the answer was "NO."

Examination of the x-rays which had been taken of the remainder of the body of President Kennedy (with the exception of the lower arms, lower legs, hands and feet) did not reveal any traces of other bullets or bullet fragments. No suggestive wounds or deformities of the hands or feet had been recorded by the expert civilian medical teams which had inserted intravenous needles for infusions and transfusions into three of the four extremities during the efforts at resuscitation, nor by the surgeons who started to put in the two chest tubes, nor by the men who did the autopsy. The likelihood that an intact bullet or large bullet fragment would travel down one of the limbs into a hand or foot, from the nearest point of entry, such as that in the neck, seemed unlikely, in view of the fact that there were no other signs such as ecchymoses, fractures, deformities, or any other evidences to suggest this. It appeared that this possibility was negligible. There was no fracture, hole or bullet track to suggest that a fragment of either bullet or bone had exited through the floor of the brain case, in the direction of the wound low on the front of the neck.

The adrenal gland areas were well visualized on the x-rays of the mid-portion of the body and no abnormal calcifications could be

Autopsy Findings on John F. Kennedy




FIGURE 11: DR. LATTIMER TESTS THE RIFLE—The author has conducted extensive tests with Mannlicher-Carcano rifles, simulating Oswald's presumed elevation, body position, range, etc. Dr. Lattimer has probably fired more Oswald-type cartridges, in Oswald-type rifles, at Oswald-type mock-ups than any other person . . . including Oswald. (Photo—I. E. Lattimer)

From the ...
of ...
"belief"

seen in these areas to suggest tuberculosis or hemorrhage of the adrenals. It is the author's firm belief that the President suffered from bilateral adrenal atrophy.

There were no calcifications in the lungs, kidneys, mesentery, spleen or prostate areas. The costal cartilages were calcified considerably more than usual. There was an irregular, slightly globular soft tissue density some 10 cm in diameter overlying the LUQ, near the midline. The nature of this was not clear, but it could have been gastric or intestinal in its location. The autopsy report described no pathology in these areas, however. It did not resemble an adrenal tumor. There was no abnormal density of the detrusor, as from any vesical neck contracture.

The AP x-ray of the lumbosacral area showed that in the bodies of the last lumbar vertebra and the first sacral segment there was some loss of bony detail, although the posterior spines and transverse processes of all the lumbar vertebrae were still visible. The joint space at L5-S1 was not visible in this projection and may have been fused. There was one tiny, elongated, crescentic 3 mm metallic density over the left side of the body of the first sacral segment, about 4 cm from the midline. This was denser and more sharply defined than the irregular metallic fragments in the head. It seemed likely that this represented a tiny residue from the fixation devices for the type of vitallium Wilson plate which was said to have been used during his operation for spinal fusion and removed at a later operation.²⁶ There was a second round shadow of lower density, about 4 mm in diameter, which resembled a droplet of contrast medium more than it did a nylon insert, overlying the right side of the body of the first sacral segment, about 1.5 cm from the midline. While it was the correct diameter for a lead shot, it did not appear dense

enough for this. Neither of these items should have caused any problems and could have been from any one of the three operations he is said to have had through the same scar, the last for the removal of complex fixation devices from scarred or infected tissues. The author is indebted to orthopedist, Dr. Frank Stinchfield, for consultation on these points. The joint space between L5 and S1 was not visible on the single (AP) x-ray of this area, and since there were no lateral, oblique or other x-ray views of this area, it was impossible to make any further observations. Certainly none of these findings suggested a rifle or pistol bullet wound.

In addition to the x-ray findings, there were other evidences (midline lumbar scar and donor site on the skin of the right thigh) of old operations for the stabilizing of L5 and S1. Also, the President was wearing a special canvas brace with metal stays, to support his lumbosacral area. The brace contained, in a pocket in its back, a thick, stiff, ovoid pad with laces over it, presumably to give the added pressure over the lumbosacral area which many sufferers from this condition find helpful. On this occasion, the President had bound this area of himself even more firmly, with a 6 inch "Ace"-type bandage, and extra padding, in addition to the usual laces and straps. It might be conjectured that this added rigidity kept his body from crumpling downward as did that of Governor Connally, after the first wound, where he might have been out of the view of Oswald's telescopic rifle sight. Instead, the President's torso remained upright while Oswald "zeroed-in" on the back of his sagging head.

Motion of the President's Body as it Was Hit

Critics of the Warren Commission Report have brought up the fact that frames 313 to 320 of the Zapruder movie²⁵ show that a frac-

Autopsy Findings on John F. Kennedy

So much was forced that there
 force of bullet & probably
 over turning that...
 force? It would seem impos-
 sible. See 63

tion of a second after the second bullet hit him at frame 313 and destroyed the right side of his brain, the President's body, which had already tilted to his left, with his head hanging downward and forward, moved slightly forward at the moment of impact, but then stiffened and lurched completely over to his left, onto the rear seat of the automobile, from which Mrs. Kennedy then rose and pivoted, to allow him to lie down on the seat. In falling to his left, the President's now practically "decerebrate" body also fell slightly backwards against the rear seat cushion. This abrupt continuation of his fall to the left, with its slight backward component, has been questioned as a possible sign that a bullet might also have hit him from the front or right front (as from the "grassy knoll" to the right of the automobile). Because of this question, a particular search for any evidence of a wound or bullet residue indicating a bullet from the right side, the left side or from the front, was made, but none could be found.

In fact, as stated previously, the flaps of scalp and bone which everted to the right (Figs. 7 & 8), could not have been caused by a bullet coming from the President's right side. The "forward" splash of hair, scalp and brain substance, clearly seen in frame 313 of the Zapruder movie (Fig. 5) at the moment of impact, could only have come from a bullet striking the President from the rear.

In view of the lack of signs of any bullet wounds or fragments in the body from any other direction (Fig. 8) and in view of the mass of evidence that two very powerful rifle bullets struck the President from the rear, some other explanation seemed more likely for the President's major sideways lurch to the left, with its slight backward component. It seemed to the author, after consultation with neurosurgeon Kemp Clark, who had declared the Presi-

dent dead, that the prime speculative possibility would be the opisthotonos-like reaction of the body, often seen immediately after acute, severe cerebral injuries, because of the massive downward discharge of nerve impulses. We know that the base of the brain was severely lacerated at that moment, in addition to the loss of the right cerebral hemisphere.¹⁷ Whether the automobile also accelerated briefly at about that instant, (as the driver, agent Greer, estimated)²¹ is not known, although agent Clinton Hill, who was reaching for the rear bumper-step and hand grip at about that time, said it did, causing him to lose his first foothold²² and run a few more steps before he could climb up on the step on the back of the automobile. This extra running by agent Hill can be clearly seen in the "Muchmore" motion pictures of the shooting.

A deliberate and specific search for any indication of a bullet wound or bullet residue which might indicate that the President was struck from any other angle than from the rear, revealed no such evidence. Frame 313 of the Zapruder movie left no doubt that the President's brain was destroyed at that moment, by a missile which drove his skull fragments distinctly forward. In any case, it was only after this cerebral destruction that he continued his slump to his left.

Suggestions

The author would like to propose:

- 1) That the x-rays be made easily available to qualified researchers, since they are impersonal in appearance.
- 2) That, for the benefit of other sufferers from adrenal insufficiency, Dr. Boswell or Dr. Humes be authorized to describe the President's adrenal glands, to demonstrate that even the pressures of the Presidency could be overcome by a man with this condition. The

False - death
 hit
 how possible?
 incredible!

whom direction

impossible, but
 all false

Die + "seen" +
 after explosion,
 pieces of...
 all... (text)

What was...
 how...
 along...
 body...
 seen?

Deliberate
 search
 for
 any
 evidence
 of
 a
 bullet
 wound
 or
 bullet
 residue
 which
 might
 indicate
 that
 the
 President
 was
 struck
 from
 any
 other
 angle
 than
 from
 the
 rear
 revealed
 no
 such
 evidence
 Frame
 313
 of
 the
 Zapruder
 movie
 left
 no
 doubt
 that
 the
 President's
 brain
 was
 destroyed
 at
 that
 moment
 by
 a
 missile
 which
 drove
 his
 skull
 fragments
 distinctly
 forward
 In
 any
 case
 it
 was
 only
 after
 this
 cerebral
 destruction
 that
 he
 continued
 his
 slump
 to
 his
 left

question of whether any steroids being taken by the President would have interfered with the healing of his tracheal wound, is a matter for conjecture.

3) That we support the principle that more and still-better-funded medical examiners are needed, who could and should be called upon in connection with any and all problem autopsies. (It is of interest that Dr. Boswell and Dr. Humes are in favor of this concept.) The author in no way wishes to presume upon the area of expertise of the forensic pathologists so ably represented in the 1968 review, by Dr. William Carnes, Dr. Russell Fisher and Dr. Alan Moritz nor the area of roentgenologic competence so well represented by Dr. Russell Morgan, in their report, nor of the superb crime laboratories of the FBI.

4) He would like to propose that a continuing office or commission be established by the government, or by a foundation, or jointly, to investigate and still further catalogue and reconcile the huge mass of historical material about this event which is stored in the National Archives, and to look into any new questions which might arise, before any more of the participants pass from the scene. The world interest in this matter is so intense as to merit this move, as demonstrated by the wave of sentiment and nostalgia which accompanies any new bulletin about the late President. This interest extends even behind the "iron-curtain," as our flood of newspaper clippings demonstrates.

It should be noted that the author's findings did not disagree with the basic findings of either the pathologists who did the autopsy, nor of the 1968 panel, although the panel went further in its interpretation than did the author and differed as to the labeling of a few items and perspectives, including three of the photographs, and upper margin of the tracheostomy

scar. None of these items was of any great consequence, however. The higher location of the wound-of-entry in the back of the head was apparent when the photographs and x-rays were finally made available to the pathologists.

5) Replacement of the purely schematic diagrams in the Warren Report (Figs. 1 and 6) by more accurate and detailed diagrams is suggested, using the same artist.

6) An analysis of the stain on the necktie should be done, to see if it is indeed dried blood, since it is relevant to the question of which direction the bullet traveled.

The fact that the x-rays were not available to the Warren Commission experimenters who did ballistic tests on simulated skulls, might have led to erroneous conclusions, since the point of aim on the simulated skulls was much too low. As it turned out, the results obtained were still not much different from the wounds of the President, except that they were lower and more lateral, as a consequence.³³

Summary

As an "uninvolved" observer, the author has studied the autopsy photographs and x-rays, the clothing, the bullets and bullet fragments, the rifle and the motion pictures of President Kennedy's assassination, in detail. He has observed to his own satisfaction, that the wounds of President Kennedy were compatible with his being struck by two fully-jacketed, military-type 6.5 mm bullets (Figs. 3 & 9) from the Mannlicher-Carcano carbine of Lee Harvey Oswald. Multiple items were seen which indicated that the first bullet struck the President in the upper back (Fig. 2), near the right side of the base of his neck, while the President's right arm was elevated waving to the crowds, thus causing his coat and shirt to "hump-up" on the back of his neck, as clearly shown in photographs taken at the time (Fig. 4). This

Autopsy Findings on John F. Kennedy

bullet (Fig. 3) may have grazed the tip of the transverse process of the seventh cervical vertebra. It then ranged downward, medially and forward, through the soft tissues of the right side of his neck and emerged very low on his trachea, near the lower edge of his necktie knot. It made two holes in the overlapping strips of his shirt immediately below the collar button, at the lower margin of the collar band, near the midline, plus a "nick" or "crease" in the side of his necktie knot. The autopsy photographs showed the angle of this bullet path to be slightly but definitely more downward than indicated in the schematic drawings in the Warren Commission Report (Fig. 1). The downward angle (Fig. 2) was enough so that it would have been impossible for anyone to shoot President Kennedy from the front, in this way, without being down inside the car, perhaps in front of Governor Connally, if the bullet followed this track. The circumferential halo visible around the posterior end of this bullet track, the presence of the visible metal fragments and of air in the proposed bullet track, the bruise of the pleura (seen at the autopsy) and the ragged hole in the trachea (seen by the surgeons) all combined to indicate that it was a single bullet track connecting the holes in the back and front of the neck, with the direction of entry from the rear (Fig. 2). The FBI laboratory (Mr. Frazier) had previously also found the cloth fibres on the margin of the bullet hole in the back of the jacket bent inward, with traces of copper on them, indicating a wound of entry on the back of the jacket.²¹ A stain, which could well be dried blood, extended downward below the hole in the necktie knot.

These observations, made possible by actually seeing the autopsy photographs and the clothing, (and added to the previous laboratory and autopsy findings) have answered some

of the questions that were in the mind of the author and have revealed no incompatibilities with the concept that two high-speed rifle bullets hit the President, both fired downward and from the rear, as from the sixth floor of the Book Depository Building. Also, that the severity of the skin, scalp and skull wounds were indeed compatible with the type of very powerful ammunition used by Oswald (Fig. 7). There were no signs of bullets or bullet wounds or bullet fragment tracks through the President's body running in any other location or direction, such as transversely, or from the front, to indicate bullet "hits" from any of these directions upon the President's head, body or limbs.

The arrangement of the metal fragments (Figs. 7 & 8) and wounds in the scalp and skull were all compatible with a powerful rifle bullet fired from the rear and above, and from no other direction.

These facts, as seen in the photographs and x-rays, satisfied the author that the alleged position of Oswald was certainly tenable. The photographs and x-rays of the head, plus the Zapruder movie film, all indicated that the President was struck in the back of the head by a second high-speed missile, while his head was bowing forward and his torso already tilting to the left, following the (first) bullet wound through his neck. This second bullet (Fig. 9) entered the back of his skull just to the right of the midline, through a thick area of the skull, and obviously disrupted upon entry, with the edge of the skull shaving off a fragment of the bullet, which remained in or near the margin of the "wound-of-entry," just as with President Lincoln. The bullet fragments separated and traversed the top of the brain and drove detached skull fragments forward and upward (clearly seen in Fig. 5, from the Zapruder movie) ahead of them as they exited

Handwritten notes:
 This is a schematic drawing of the bullet path through the neck and head of the President. It shows the bullet entering from the rear and above, passing through the necktie knot, and exiting through the trachea. The drawing is a simplified representation of the actual findings.

Handwritten notes:
 This is a schematic drawing of the bullet path through the neck and head of the President. It shows the bullet entering from the rear and above, passing through the necktie knot, and exiting through the trachea. The drawing is a simplified representation of the actual findings.

Handwritten notes:
 This is a schematic drawing of the bullet path through the neck and head of the President. It shows the bullet entering from the rear and above, passing through the necktie knot, and exiting through the trachea. The drawing is a simplified representation of the actual findings.

Handwritten notes:
 This is a schematic drawing of the bullet path through the neck and head of the President. It shows the bullet entering from the rear and above, passing through the necktie knot, and exiting through the trachea. The drawing is a simplified representation of the actual findings.

Handwritten notes:
 This is a schematic drawing of the bullet path through the neck and head of the President. It shows the bullet entering from the rear and above, passing through the necktie knot, and exiting through the trachea. The drawing is a simplified representation of the actual findings.

Handwritten notes:
 This is a schematic drawing of the bullet path through the neck and head of the President. It shows the bullet entering from the rear and above, passing through the necktie knot, and exiting through the trachea. The drawing is a simplified representation of the actual findings.

in an "explosive" manner (to quote the 1968 panel) through the top part of the right side of the front of his head. These fragments of skull stretched and then tore the scalp along its front and right lateral margins as they traveled upward and forward. Sandlike fragments of this bullet were scattered throughout the right side of the upper and forward parts of the brain case, on the right (and only on the right) side. Another skull fragment appeared to be turned outward to the right but did not detach. The bones of the base of the skull were severely fractured, with huge, long fracture lines extending deeply into the basilar portions of the skull, especially on the right, and causing the abnormal mobility of the bones of the skull commented upon by Drs. Boswell, Finck and Humes, who did the autopsy.⁹ Only after the fragments of his skull flew forward and upward, did the stricken President continue his fall to his left, with a spastic lurch.

There was an unusual amount of calcification of the costal cartilages. On these x-ray films, there were no abnormal calcifications or masses in the regions of the adrenal glands to suggest tuberculosis, hemorrhage or tumor. It is the author's belief that the President had bilateral adrenal atrophy.

The President was wearing a special lumbosacral back brace, tightly laced over a semi-rigid pad, but in addition, tightly bound to him

with a wide, knitted elastic bandage, with much padding. Whether this extraordinary support helped to keep his torso upright, rather than permitting him to crumple down out of sight, as did Governor Connally, after the first bullet, can only be conjectured. In any case, he remained upright after being hit by the first bullet, while Oswald appears to have zeroed in on the back of his head for the second and fatal wound.

Previous research by the author had shown that the technical details of the shooting, such as the ammunition, the rifle, and the capability of the shooter had all proved compatible with the version advanced by the Warren Commission, as demonstrated in actual experimentation by the author, and his two sons, Jon and Gary.^{10, 11}

The study of the autopsy photographs and x-rays has helped to answer most of the questions of fact which had remained in the author's mind about the direction and effects of the two bullets which were known to have hit President Kennedy.

This unhurried study of these materials made it possible for the author to take more measurements, and to add a few details and reconciliations, as did the 1968 panel, but it has brought to light no basic discrepancies in the concepts put forth in the Warren Commission Report. □ □

Bibliography on following page

"Concepts" of facts are not
 in same. Elsewhere
 he said that it is not included
 in the report.

cannot
 be done
 the bullet is
 in the back
 of the head
 on
 crutch

this is
 100% not
 true & some
 were released

had own
 computer
 success in
 it was

with less
 than 100%
 side just
 printed
 looked at
 nothing
 else?

They don't
 know that
 he was
 wearing the
 brace
 they saw
 the debris
 but not

15 Compare with text in my m wound.
16 Why out of sequence? Editing on p. 50? of what?

Bibliography

1. Testimony of Mrs. John Connally; Hearings Before the President's Commission on the Assassination of President Kennedy. U.S. Government Printing Office, Wash., D.C., Vol. IV, pp. 146-149, 1964.
2. Three Patients at Parkland; Texas State J. of Medicine, Vol. 60, pp. 60-74, January 1964.
3. Security Arrangements at Parkland Hospital; Report of the President's Commission on the Assassination of President Kennedy, U.S. Government Printing Office, Wash., D.C., pp. 57-58, 1964.
4. Lattimer, John K.: The Stabbing of Lincoln's Secretary of State on the Night the President Was Shot. J. of the Amer. Med. Assoc., Vol. 192, pp. 99-106, April 12, 1965.
5. Bethesda, Mrs. Kennedy's Choice; Report of the President's Commission on the Assassination of President Kennedy. U.S. Government Printing Office, Wash., D.C., p. 59, 1964.
6. Testimony of Commander Humes; Hearings Before the President's Commission on the Assassination of President Kennedy. U.S. Government Printing Office, Wash., D.C., Vol. II, p. 367, 1964.
7. Finck, Lt. Col. Pierre. New York Times, p. 18:2, February 25, 1969.
8. Autopsy Report and Supplemental Autopsy Report. Report of the President's Commission on the Assassination of President Kennedy. U.S. Government Printing Office, Wash., D.C., pp. 538-546, 1964.
9. Report of the Panel of Forensic Pathologists, Dr. William H. Carnes, Dr. Russell S. Fisher, Dr. Russell H. Morgan (Radiologist) and Dr. Alan R. Moritz. New York Times, January 17, 1969.
10. Lattimer, John K. and Lattimer, Jon: The Kennedy-Connally Single Bullet Theory: A feasibility study. International Surgery, Chicago, Ill., Vol. 50, No. 6, pp. 524-532, December 1968.
11. Lattimer, John K., Lattimer, Jon and Lattimer, Gary: Could Oswald Have Shot President Kennedy: Further Ballistic Studies. Bulletin of the N.Y. Academy of Medicine, New York City, Vol. 48, No. 3, pp. 513-524, April 1972.
12. Diagram of Head Wound of President Kennedy, Exhibit 388. Hearings Before the President's Commission on the Assassination of President Kennedy. U.S. Government Printing Office, Wash., D.C., Vol. XVI, p. 984, 1964.
13. Diagram of Bullet Wound Through Neck of President Kennedy, Exhibit 385 *ibid*, Vol. XVI, p. 977.
14. Testimony of Commander Humes concerning photograph of pleura, *ibid*, Vol. II, p. 363.
15. Hearsay basis for schematic drawings in Warren Report. Testimony of Commander Humes, *ibid*, Vol. II, p. 350.
16. Severity of skull fractures. Testimony of Commander Humes, *ibid*, Vol. II, p. 354.
17. Brain base lacerated. Testimony of Commander Humes, *ibid*, Vol. II, p. 356.
18. Blood-stained shirt of President Kennedy, Exhibit 394, *ibid*, Vol. XVII, pp. 25-26.
19. Blood-stained suit-coat of President Kennedy. Exhibit 393, *ibid*, Vol. XVII, pp. 23-24.
20. Necktie of President Kennedy, Exhibit 395, *ibid*, Vol. XVII, p. 27.
21. Testimony of Robert A. Frazier, FBI Laboratories, re Analysis Margins of Bullet Holes, *ibid*, Vol. V, pp. 58-62.
22. Bullet jacket found on floor of Kennedy limousine by front seat, Exhibit 569, *ibid*, Vol. XVII, p. 257.
23. Three lead particles found on floor of Presidential limousine under jump seat. Warren Commission Exhibits, *ibid*, Vol. XVII, p. 840.
24. Schematic diagram of both head and neck wounds of President Kennedy, Exhibit 386, *ibid*, Vol. XVI, p. 977.
25. Zapruder movie of shooting—frames 313-320, *ibid*, Vol. XVIII, p. 70.
26. Nicholas, J., Burstein, C., Umberger, C. and Wilson, P.: Management of adrenal cortical insufficiency during surgery. Annals of Surgery, Chicago, Ill., Vol. 71, p. 739, 1955.
27. Lattimer, J. K.: The wound that killed Lincoln. JAMA, Vol. 187, pp. 480-489, Feb., 15, 1964.
28. Lattimer, J. K.: Similarities in the fatal wounds of John Wilkes Booth and Lee Harvey Oswald. N.Y. State J. Med., Vol. 66:13, pp. 1782-1794, July 1, 1966.
29. Lattimer, J. K.: Factors in the death of President Kennedy. JAMA, Vol. 198:4, pp. 327-333, October 24, 1966.
30. Nichols, J. M.: President Kennedy's adrenals. JAMA, Vol. 201:2 pp. 129-130, July 10, 1967.
31. Greer, William R. (agent and driver); Hearings Before the President's Commission on the Assassination of President Kennedy. Vol. II, p. 119, 1964.
32. Hill, Clinton (agent); *ibid*. Vol. II, P. 138 and 139, 1964.
33. Olivier, Alfred G.: Experimental Wounds on the Skull, *ibid*, Vol. V, p. 89.