

copy to = H. WEISBERG - "KENNEDY ASSASSINATION CHRONICLES" - Summer, 1992

THE THIRD WOUND

file
By Millicent Cranor

INTRODUCTION

This report is about a constellation of statements suggesting the possibility of an unacknowledged *third* wound in John Kennedy's body, high in the back of the neck (or very low in the skull) - within the hairline.

Newly released documents combined with mysterious remarks buried in the Warren Commission Hearings suggest this additional wound was created by the same bullet that produced the throat wound - either on the way in, or on the way out.

The conclusions stated below cannot be verified - but neither can the conclusions of the prosecutors who performed Kennedy's autopsy, James Humes, J. Thornton Boswell, and Pierre Finck. Actually, the conclusions (two shots fired from slightly above and behind) seemed pre-determined, and not by the prosecutors. Their job was to document the specifics - whether existent or not - that support the conclusions.

Reports of the specifics changed again and again over the years, as different doctors decided different specifics were needed to support the same conclusions.

It is one thing to revise an interpretation, and quite another to revise an objective fact.

The doctors contradicted themselves, they contradicted each other, they contradicted other principal players, they contradicted what little remains of the physical evidence. The brain has been "lost"; bone fragments found in various places have been "lost"; tissue slides have been "lost"; photographs have been "lost"; x-rays have been "lost"; and memories have been lost.

In view of this constant revision of objective data, it is reasonable to consider - without making conclusions - certain alternative claims.

The location of this hypothetical third wound is indicated in photographs by an amorphous white shape in an otherwise clean area where the hair is combed. It is below the EOP (external occipital protuberance). It was dismissed by the HSCA as nothing but brain adhering to hair.¹

All three prosecutors (autopsy doctors) and the radiologist on call insisted to the HSCA that in fact there was a wound under the hair in that location - only they presented it as the *second and last* wound, the entrance into the head.^{1,2}

In the autopsy report and in testimony before the Warren Commission, the entrance into the head was said to be higher: "slightly above" the EOP.^{3,4}

Available skull x-rays apparently show no wound either above or below the EOP, but their authenticity is doubted by many researchers for several reasons. Those x-rays do not show the entrance wound in the official 1964 location, nor do they show the tremendous damage to the back of the head described by so many witnesses in Texas and at the autopsy.

Jerrold Custer, the technician who took all the x-rays of Kennedy that night, claims he took an A-P view (front to back) of the neck alone - and it showed many metal fragments in the third-fourth cervical vertebra.⁵

If a bullet entered near the hairline in the back, and proceeded to exit from the *throat* in the front, this would mean that a different bullet

created the head damage. This was one bullet too many. Sometime on the night of November 22, 1963, or the following morning, the prosecutors probably learned that only three shots were supposed to have been fired - but not all of them struck Kennedy. Yet, they may have had three separate entrance wounds (if not more).

Theory:

1. A back wound that seemingly went nowhere.
2. A head wound that seemingly went everywhere.
3. A high neck wound that connected with the throat.

If the doctors were under pressure to find that Kennedy was struck by only two bullets, this is how they might have revised their earlier findings:

1. Disconnect the low head/high neck wound from the throat - and connect it with the head damage.
2. Connect the back wound with the throat wound.

If this is what happened, this may explain why the neck was not dissected, or if it was, why they would be reluctant to discuss their findings. A neck dissection would either prove or disprove the alleged connection between the wound in the throat and the wound in the shoulder.

THE THROAT WOUND

Commander Humes claimed they had no idea the throat wound was anything other than a tracheotomy incision until the next morning when it was too late to dissect the neck.⁶ So they never proved conclusively the existence of a connection between the wounds in the shoulder and throat. But there are several indications that they did indeed know about the throat wound:

J. Thornton Boswell, M.D.

Saw "part of the perimeter of a bullet wound in the anterior neck."⁷

Thought "a bullet may have fallen out the neck wound...prior to the time when they began to feel there was a very real possibility of an exit wound in the anterior neck."⁸

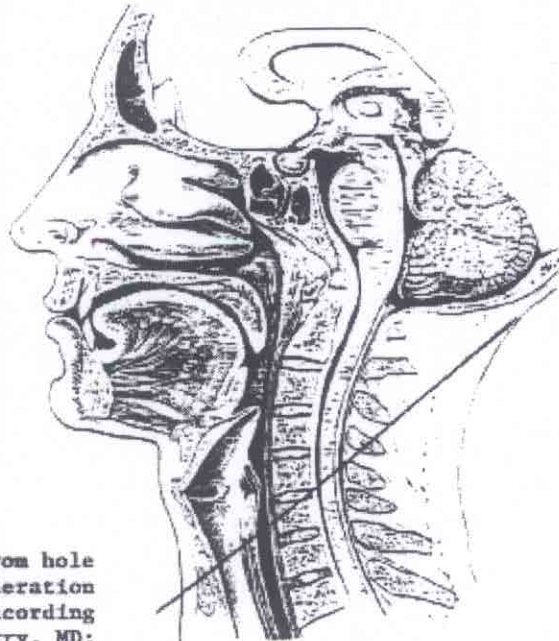
Said anterior neck damage was caused by tracheotomy, and "in the later courses of the autopsy thought it may have included the exit wound of a bullet."⁹

Did you reach the conclusion that there had been a *transit wound* through the neck during the course of the autopsy itself? Oh, yes.⁹

[O]ur conclusions had been that night and then reinforced the next day that it was a tracheostomy *through a bullet wound*.¹⁰

John H. Ebersole, M.D.

Dr. Ebersole, a Commander in the Navy, and Acting Chief of Radiology at the time, was not aware that an exit wound in the front was suspected, and spoke as if Dallas had first informed the pathologists of the bullet wound in front. But what is important is *when* he said

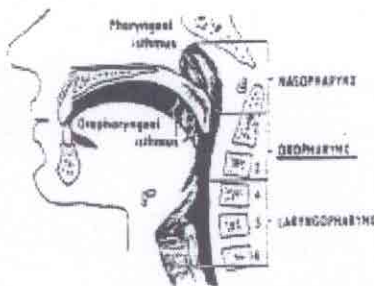


Trajectory, from hole in skin to laceration in trachea, according to Malcolm Perry, MD: upward

Autopsy doctors sometimes say: Wound was below the EOP.

Missing X-ray of neck: many metal fragments at C3-4

Blood in throat was from oropharynx, per W. Kemp Clark, MD, which is adjacent to C3-4. See Diagram at left.



the information from Dallas was obtained: 10:30 to 11:00p.m., or thereabouts.

I believe by ten or ten thirty approximately a communication had been established with Dallas and it was learned that there had been a wound of exit in the lower neck that had been surgically repaired. I don't know if this was premortem or postmortem but at that point the confusion as far as we were concerned stopped.¹¹

I would say in the range of ten to eleven p.m. Dr. Humes had determined that a procedure had been carried out in the anterior neck covering the wound of exit. Subsequent to that the fragments arrived.¹²

And it is your impression that before the autopsy was finished at ten thirty at night contact had been made between Dr. Humes and —

I must say these times are approximate but I would say in the range of ten to eleven p.m. Dr. Humes had determined that a procedure had been carried out in the anterior neck covering the wound of exit...¹²

The taking of the X-rays again were stopped... once we had

communication with Dallas and Dr. Humes had determined that there was a wound of exit in the lower neck anterior ... once that fact had been established... my part in the proceedings was finished.¹³

The information was that there had been a wound of exit there, a tracheotomy and a suturing done.¹⁴

John T. Stringer

Stringer, the photographer, said the doctors knew a bullet has passed through the throat and put their fingers in it, "by feeling, to see if there was anything sharp."¹⁵ In addition, he said they placed a probe in the wound from the *front*, but did not see where it exited in the back.

The probe was inserted in the throat wound in the front of the neck...[it went] straight in... I saw it in. I don't know whether it went up, down... sideways, or what."¹⁵

MISSING X-RAY: FRAGMENTS AROUND C3-4

A neck dissection may also have demonstrated Jerrol Custer's amazing statement that he took an x-ray of Kennedy's neck that revealed many metal fragments in the C3-4 area (third-fourth cervical vertebra). This x-ray, an A-P view (front-to-back) of the neck, is not among the x-rays available, nor is it listed.

A fragmentation of a shell was in and around that circular exit — that area. Let me rephrase that. I don't want to say "exit," because I don't know whether it was exit or entrance in that area — that opening.⁵

If a bullet entered the area indicated by the blob in the hairline and continued *downward* toward the throat, it would pass the C3-4 area.

According to the microscopic analysis in the autopsy report, all sample slices taken of the brain showed damage "directly related" to the bullet. Included on the list was "the line of transection of the spinal cord."⁵ It may be that in the case of this one specimen, the damage was indirect. But, taken literally, this means the spinal cord was directly damaged by the bullet, possibly even transected by the bullet.

CONNECTING THROAT AND HEAD WOUNDS

William Kemp Clark, M.D., former Chairman of the Department of Neurosurgery at Parkland, recorded the following observation in his hospital notes:

Doctors Perry, Baxter, and McClelland began a tracheostomy, as considerable quantities of blood were present from the President's oral pharynx (AKA "oropharynx").⁶

The oropharynx and C3-4 areas are adjacent. (See diagram.)

It is not even clear whether or not this was Clark's own observation or that of a colleague, but no one else mentioned it in the records. It is also unclear if it was an observation or an assumption, but it is certainly not stated as an assumption. The oropharynx would not be a source of blood in a wound track from the lower third of the neck to the lower wound in the back. Clark's comment may be related to speculation that the bullet entered the throat and exited the *head*.

The head wound could have been either the exit wound *from the neck* or it could have been a tangential wound, as it was simply a large, gaping loss of tissue. (Emphasis added.)¹⁷

Connecting the Dots

The above conjecture could have been based on merely two facts: a small wound in the throat, and a large wound in the head — and no knowledge of any other connection and no knowledge of any back wound. The connection of two dots. However, Dr. Clark seemed to have observed a third dot, the oropharynx.

Humes et al said the bruise on top of the lung connected the throat and back wound.³ Why should we assume the Bethesda set of three dots connect any better than Dr. Clark's? The neck was not dissected at Parkland — or at Bethesda (or so they say). Could the bullet that caused the hypothetical third wound have caused the bruise on the lung? It is well known that, through cavitation (tissue exploding radially away from the path of the bullet), a bullet can cause damage at a distance. But was there such damage? Some believe the blood seen there came from elsewhere. Still, it should be noted that a microscopic exam of the lung revealed "disruption of alveolar walls and recent hemorrhage into alveoli."³ But why is all material documenting damage to the lung tissue missing? Where are the slides showing the actual damage? Where is the photo of the interior thorax which principals at the autopsy swore was taken?^{18, 19, 20}

UPWARD FROM THE THROAT

Malcolm Perry said the trajectory from the wound in the skin to the hole in the trachea, was *upward*. Arlen Specter apparently wanted Perry to say the trajectory was upward from (1) the wound in skin, to (2) the wound in the back, but such a trajectory would have been *downward*. Perry does not point this out.

Based upon a point of entrance...14cm below the tip of the right mastoid process and coupling that with your observation of the neck wound, would that provide sufficient basis for you to form an opinion as to the path of the bullet, as to whether it was level, up or down?

Yes, it would. In view of the fact there was an injury to the right lateral portion of the trachea and a wound in the neck if one were to extend a line roughly between *these two*, it would be going slightly superiorly, that is cephalad toward the head, from anterior to posterior, which would indicate that the missile entered from slightly above and behind. (Emphasis added.)²¹

(The trajectory suggested in this report is more than slightly upward, but less than implied by the diagram; the steepness of the bullet path is partly an illusion due to viewpoint.)

LT. RICHARD LIPSEY: THREE WOUNDS

Richard Lipsey described the entrance of three bullets, and their presumed course, based on what he saw, and what he heard the doctors say, for he "listened to their conclusions:"²²

- (1) one bullet entered the back of the head and exited resulting in part of the face and head being blown away;
- (2) another bullet entered at the *top of the neck (rear) which exited in the front portion of the neck*; (emphasis added) and
- (3) another bullet entered at the bottom of the neck (rear) or high in the back which did not exit.

Other significant comments:

He also added that no real entrance in the rear of the head existed; he feels that one bullet blasted away an entire portion (entrance and exit).²²

Lipsey stated that he cannot recall the doctors specifically saying that the wound in the throat was caused by a bullet but he does feel the doctors were convinced that a bullet exited from the front of the neck.²²

Lipsey said that the doctors were using the angle from the entrance in the rear of the head to the throat to look for the other bullet that entered high in the back. He said that both entrances looked the same.²²

Lipsey states he definitely remembers the doctors... were "absolutely, unequivocally" convinced that he had been shot three times.²²

Lipsey also identified the entrance in the lower head as being *just inside the hairline*. (Emphasis added.)²²

Researcher Vern Pascal sums up the prosecutors' predicament before it became even more complicated:

Lipsey adds confirmation to the autopsists having been "advised" at the outset that three shots had been fired from the rear, and that's what they found, three separate wounds. They couldn't have known about the Tague wounding nor the resultant SBT.²³

PROBES THROUGH THE BODY

Numerous reports of probes going all the way through the body suggest, at the very least, the bullet wound in the throat was known the night of the autopsy. And some of these reports suggest the probes connected that wound with one at the base of the head, or high neck. Dr. Boswell denied that any probes went all the way through the body. He said that only an eight inch probe was used, and it only went in about three inches.²⁴ However, while denying a probe ever transited the body, he made a statement about the path it would make:

The wound came through and downward just above the thoracic cavity and out at about the *thyroid cartilage*. So if you put a probe in this and got it back through like this, that would come out right at the base of the neck. (Emphasis added.)²⁵

A probe entering the wound in the back (as seen in the one photo of this wound), grazing the top of the lung, would indeed exit the thyroid cartilage, or higher. But the wound in the front of the neck was lower.

Robert F. Karnei, Jr., M.D.

Dr. Karnei said that he remembered repeated instances, during the

numerous attempts to probe the back wound, when photographs were taken of a probe in the President's body (at approximately 9:00pm), and seemed more certain of this recollection than of any other during his ARRB interview.²⁶

Tom Robinson

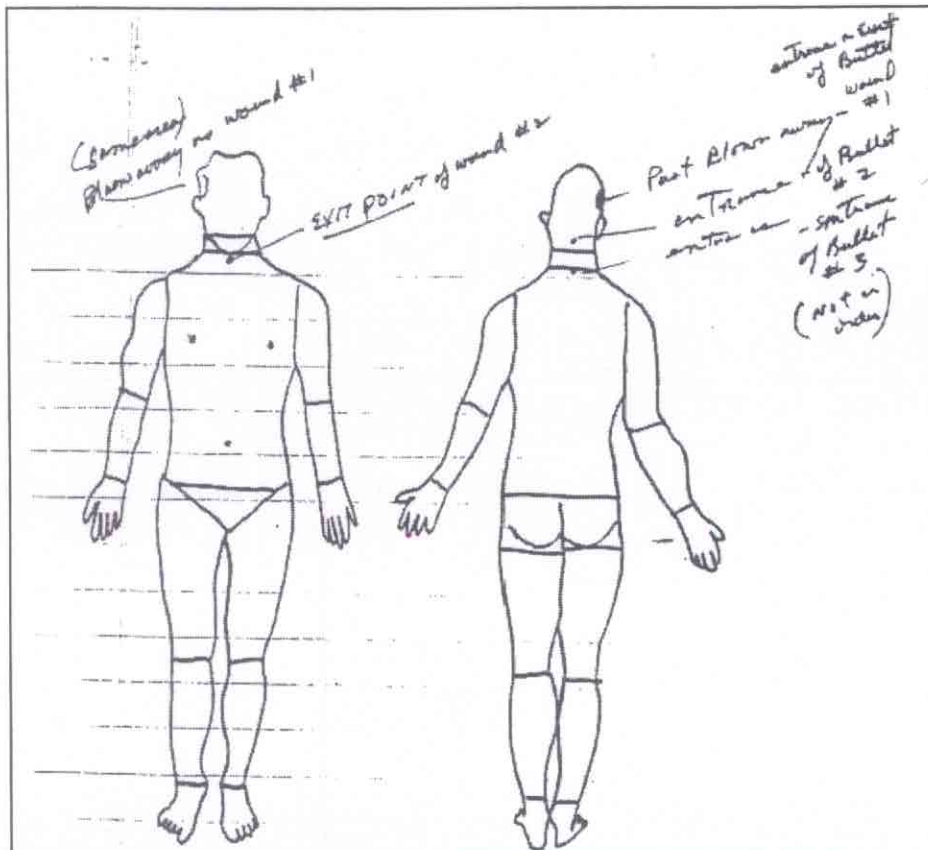
Robinson, one of the embalmers who, according to his supervisor Joe Hagen, "had the most to do with the reconstruction of President Kennedy's head" said — in 1996 — he saw a probe inserted near the base of the brain which came out of the throat.

His most vivid recollection of the probe is seeing it inserted near the base of the brain in the back of the head (after removal of the brain), and seeing the tip of the probe come out of the tracheotomy incision in the anterior neck. He was adamant about this recollection.²⁷

In 1977, he indicated the probe may have been placed slightly lower:

Do you feel they probed the head or they probed the neck?

It was at the base of the head where most of the damage was done, the things that we had to worry about. So it all runs together in my mind.²⁸



Marking and captions made in 1978, by Richard A. Lipsey, former aide to General Wehle, Commanding General of the Military District of Washington, U.S. Army — the office responsible for ceremonial military functions in Washington, D.C. and JFK's funeral. Lipsey attended the president's autopsy.

Robert L. Knudsen

The family of photographer Robert L. Knudsen said he photographed the body with three probes perforating it: two in the thorax/neck, and one in the head.²⁹ He may have discussed it with his family when it was still fresh in his mind. In 1978, he told the HSCA he "thought" he saw a black and white negative that showed "the body erect with two probes through it."³⁰ He thought it was about 24 inches long, and 3/8 inch in diameter, a right profile³⁰ (Earl McDonald, former medical photographer at Bethesda, confirmed the possibility of seeing such a thing on a negative; he said that metal probes "were always the most prominent—the darkest — portions of a B & W negative."³¹)

Joe O'Donnell

O'Donnell, a "government photographer, employed by USIA... frequently detailed to the White House," who had a "close professional relationship with Robert Knudsen, said that on two occasions right after the autopsy, Knudsen showed him some black and white photographs:

First Viewing... remembers a photograph of a gaping wound in the

back of the head...big enough to put a fist through... another image showed small round hole above the President's right eye... [elsewhere described as 3/8 inch diameter]³² [Tom Robinson said a hole in the skull was in this location, but he thought (or was told) it was created by shrapnel.]

Second Viewing:... hole above the right eye was no longer visible... back of the head now looked completely intact... hair "wet, clean, and freshly combed....[attributed] the differences to the restorative work of the embalmers.³²

Unfortunately, the photograph most relevant to this report got the least attention, but it is still one more description of a probe emerging in the front of the body:

Another photograph he remembers showed President Kennedy lying on his back, with an aluminum probe emerging from his stomach or right side (details were vague).³²

John T. Stringer

As mentioned earlier, John Stringer also saw a probe in Kennedy's throat, only it was being inserted from the front.³²

James J. Humes, M.D.

Incredibly, Humes, himself, allegedly described an X-ray in which a probe went all the way through, only it entered at a lower location, allegedly the throat and shoulder wounds.

Jim Snyder of the CBS bureau in D.C. told me today he is personally acquainted with Dr. Humes. They go to the same church and are personally friendly. Snyder also knows Humes' boss in Bethesda; he is a neighbor across the street from Snyder. Because of personal relationships Snyder said he would not want any of the following to be traced back to him; nor would he feel he could be a middleman in any CBS efforts to deal with Hume [sic]...

Humes said one X-ray... would answer many questions that have been raised about the path of the bullet going from Kennedy's back through his throat. Humes said FBI agents were not in the autopsy room during the autopsy; they were kept in an anteroom, and their report is simply wrong. Although initially in the autopsy procedure the back wound could only be penetrated to finger length, a probe later was made — when no FBI men were present — that traced the path of the bullet from the back going downwards, then upwards slightly, then downwards again exiting at the throat.³³

This is a remarkable specimen of damage control, regardless of whether the author was Humes, Humes' boss, or Jim Snyder himself.

OMISSIONS AND REVISIONS

The Official Head Entry

The least credible revision in objective data concerned the location of the officially acknowledged entrance wound in the head. And the excuses made by Michael Baden, M.D., Head of the HSCA Medical Panel, accentuate the problem. From his book, *Unnatural Death: Confessions of a Medical Examiner*:

Perhaps the most egregious error was the four-inch miscalculation. The head is only five inches long from crown to neck, but Humes was confused by a little piece of brain tissue that had adhered to the scalp. He placed the head wound four inches lower than it actually was, near the neck instead of the cowlick.³⁴

Baden neglects to mention that Humes told him "the wound on

the skull precisely coincided with" the piece of tissue adhering to the scalp.³⁵ He implies the pathologists never lifted up the scalp to examine the bone beneath, an absurdity comparable to not removing a victim's clothing during an autopsy. He implies that only one pathologist was involved, instead of three: Humes, Boswell and Finck. He implies that a calculation (more opportunity for error) instead of a simple direct measurement resulted in this monumental discrepancy. And, finally, Baden implies that Humes did not know the top of the head from the bottom.

Four inches is quite a chunk of real estate on the human head. Property disputes have been based on less. No matter how inexperienced the prosecutors were, it is hard to believe they could make such a mistake. It is easier to believe the wound was revised because, on hindsight, it seemed inconsistent with a shot from the sixth floor of the Depository building

When X-rays Are Seen

Another excuse made for the prosecutors' "mistake" in the wound's location is the claim that they never examined the x-rays, or that they did not closely examine them. Humes, himself, seemed to think the script called for his not having seen them:

[T]he photographs and the X-rays were exposed in the morgue...and they were not developed, neither the X-rays or the photographs. They were submitted to the...Federal Bureau of Investigation.³⁶

Soon after, during the same interview, he gave quite a different story:

In further evaluation this head wound, I will refer back to the X-rays ...These had disclosed to us multiple minute fragments of radio opaque material traversing a line from the wound in the occiput to just above the right eye, with a rather sizable fragment visible by X-ray just above the right eye. These tiny fragments that were seen dispersed through the substance of the brain in between were, in fact, just that extremely minute, less than 1 mm. in size for the most part.³⁷

...we examined carefully the bony structures in this vicinity as well as the X-rays... and we saw no such evidence, that is no fracture of the bones of the shoulder girdle, or of the vertical column, and no metallic fragments were detectable by X-ray.³⁸

What The X-rays Showed

The location of the entrance wound was not only revised in 1968, but, as if by magic, a round metal fragment appeared that had not been described before, a fragment that just happened to be 6.5mm the exact diameter of the Carcano bullet. This fragment shows through the right eye of the skull in the x-ray, and is as obvious as a candle in a pumpkin. Yet, there is no mention of it anywhere in testimony or in the autopsy report, which reports two small fragments in the front of the head:

Roentgenograms of the skull reveal multiple minute metallic fragments...From the surface of the disrupted right cerebral cortex, two small...fragments of metal are recovered. These measure 7 x 2 mm and 3 x 1 mm.³

The Perimeter of the Defect

One of the most spectacular contradictions in this case was described by David Lifton in his book, *Best Evidence*. Observe the photo on page 683 of his book, showing the perimeter of the great defect in the skull with a pronounced semi-circular notch in it, so very round and suggestive of a bullet hole.³⁹ In addition, it shows the outward beveling characteristic of an exit wound. (Tangential entrance

wounds are also beveled outward, but only on the side of the bullet's approach.) It is difficult to believe they would not see such an image, particularly in view of the fact that it seems to be the focus of the photograph. Yet, Commander Humes made this statement before the Warren Commission:

Having ascertained to our satisfaction and incidentally photographs illustrating this phenomenon from both the external surface of the skull and from the internal surface were prepared, we concluded that the large defect to the upper right side of the skull, in fact, would represent a wound of exit. A careful examination of the *margins of the large bone defect* at that point, however, *failed to disclose* a portion of the skull bearing a wound of — a point of impact on the skull [from the inside of the skull?] of this fragment of the missile, remember, of course, that this area was devoid of any scalp or skull at this present time. We did not have the bone. (Emphasis and parenthetical question added.)⁴⁰

Humes did not say the notch was hidden from view. Quite the contrary: no notch was visible even with the scalp pulled back. Colonel Finck, in his 1965 summary statement, never described a notch in the perimeter, and spoke only of separate *bone fragments* showing a pattern that established an exit wound. It is unclear whether the beveling he referred to was the shelving along the entire edges of the fragments, or to the rounded area created directly by a bullet. (The size he gives for the fragments is also puzzling since the largest was almost twice the dimension he gives.)

No exit wound is identifiable at this time in the skull, but close to midline, portions of cranial vault are received from Dallas, Texas...Two of the bone specimens, 50 mm in diameter, reveal beveling when viewed from the external aspect, thus indicating a wound of exit. Most probably, these bone specimens are part of the very large right skull wound, 130 mm in diameter and mentioned above. This right fronto-parieto-occipital wound is therefore an exit.⁴¹

All three prosecutors signed a statement acknowledging the notch in the defect, and its presence in photographs 17, 18, 44, 45. Its size was described specifically:

Photographs Nos. 44 and 45 also show that the point of exit of the missile was much larger than the point of entrance, being 30 mm. (1.18 inches) at its greatest diameter.⁴²

As mentioned earlier, it is difficult to believe they would not see this 30mm semi-circular indentation on the skull itself. The problem may have been that, as many researchers believe, this wound was in the *back* of the head. An exit wound in the wrong place could create obvious problems for doctors under pressure to find one in the opposite location.

There may have been yet another notch in the perimeter, representing half of the *entrance* wound, but one would not conclude this from the autopsy report³ or from Commander Humes testimony before the Warren Commission. He implied the hole was complete, but rather slyly described the hole in the *scalp*, referring indirectly to the hole in the bone as a "corresponding defect," which does not necessarily mean it was a complete hole.

The second wound was found in the right posterior portion of the scalp. This wound was situated approximately 2.5 centimeters to the right, and slightly above the external occipital protuberance.⁴³

[T]his wound... was in a portion of scalp which had remained intact. So, we could see that it was the measurement which I gave before...15 by 6 millimeters.

When one reflected the scalp away...there was a corresponding defect through both tables on the skull in this area.⁴⁴

But in 1978, Boswell said the entrance wound was only part of a hole, that a late-arriving fragment was used to complete it. (Humes was present, and apparently did not object.)⁴⁵ In 1996, Humes contradicted this claim:

Did the wound appear as something like a puncture in the bone, or was there a fragment of the bone that was missing and that there was an indentation.

No.

And the whole circumference of the entry wound was visible without any reconstruction of the skull?

Oh, yeah, sure.⁴⁶

In 1996, Boswell contradicted Humes:

Could you tell whether the entrance wound that you identified in the skull was something that appeared like a puncture in a bone with the remainder of the bone surrounding the hole? Or did the hole break off such that you would need other pieces of bone to be brought into place to show the entire periphery of the wound?

I believe there was an area of bone intact down here that we could attach this to.

[A]nd when you say "this," you're referring to the small fragment at the bottom of the page. Is that correct?

Yes.⁴⁷

Descriptions of the late-arriving bone fragments also varied. In 1964, Humes claimed that only one of the fragments had a part of a bullet hole in it, the *largest* one, which contained evidence of an exit wound.

[A]t the margin of *one* of them which was roughly pyramidal in shape was a portion of a circumference of what we interpreted as a missile wound. (Emphasis added.)⁴⁸

Of course, if the entrance wound was completed by the *smaller* bone fragment, that fragment also had to contain a "portion of a circumference."

For a more extensive treatment of this intriguing subject, please see the outstanding work of Gary L. Aguilar, M.D.⁴⁹

A Notable Omission: The Cerebellum

Nowhere in the autopsy report is there a description of the *gross* appearance of this organ. A slice of it was acknowledged in the supplementary report; it is on the list of tissues examined microscopically that were found to have "extensive disruption... directly related to the recent trauma."³ They omit describing the condition of this organ, made famous by claims that the wound in the back of the head was so low that cerebellum protruded from it, yet, they describe in great detail such things as the precise width of the heart valves.

Bone Fragments Not at the Autopsy

Two bone fragments were not found in time to be studied during the autopsy: the Harper fragment, a large piece of bone named after the young man who found it, William Harper, and another one found by Seymour Weitzman. The FBI turned both of them over to George Burkley, M.D. on November 25, 1963, who described only the Harper

fragment; he said it was 3.5 x 2.5 inches.⁵⁰

A.B. Cairns, a pathologist who examined the Harper fragment closely before it was turned over, said it was "lower occipital" based on the "suture and inner markings where blood vessels run around the base of the skull." It had a small area of "grayish discoloration," suggesting lead traces. He also said he thought the fragment came from an area near an entry wound because of the "way the tables were broken," but no part of a bullet hole was seen.⁵¹

An entering bullet would not likely detach a bone near the entrance and send it flying, but an additional shot from the front or side could have.

If the Harper fragment was occipital, then it came from the back of the head. But the HSCA Medical Panel, during an intense meeting with Humes, Boswell and various experts, decided the fragment was parietal, and came from the right front of the head.⁵²

The location of where the Harper fragment was found has been revised. Harper apparently told the FBI that he found it "25 feet south of the spot where President Kennedy was shot."⁵³ This author wrote to Mr. Harper asking him to indicate the exact spot on an enclosed map of Dealey Plaza. He marked a place near the underpass that was nearly 100 feet southwest of where Kennedy was shot in the head.⁵⁴ Even the circumstances in which the FBI came to possess the Harper fragment have been revised by Michael Baden.

According to FBI documents, Harper found the fragment one day after the assassination, and immediately took it to his uncle, Dr. Jack Harper who took it to Methodist Hospital where it was examined by the chief pathologist, A.B. Cairns, and photographed. Dr. Harper turned the fragment over to the FBI the following Monday, November 25, 1963.⁵⁵ Yet, this is how Michael Baden represented the episode in his book:

"The fourth [fragment]... was found a few days after the autopsy by a premed student... He took it home to his father, a doctor, who knew what it was and had it photographed. At a party, the photographer couldn't resist talking about it, and the story got back to the FBI. Agents swooped down on the premed student, who was saving the fragment as a souvenir."⁵⁶

THE THIRD WOUND

This amorphous white image in the "back of the head" photo appears just above the hairline in the back of the head. For good reasons, many researchers suspect the hair has been drawn in. It may be that the white image is also some sort of falsification, either in the photograph, or on the head itself. Since the hair in the rest of this area appears cleaned and combed, it is hard to believe the image represents dried brain left behind. It is tempting to suspect it is a tag of torn scalp pulled outward by an exiting bullet.

It is unclear whether it is in the skull or in the neck. The hairline extends below the skull level to include the muscles of the neck and, as can be seen in the diagram, a bullet entering just above the hairline could miss the skull if it courses downward.

A bullet striking very low in the skull would probably have killed Kennedy instantly. Since he was still breathing when brought in, the bullet probably entered or exited in the high neck, where Jerrol Custer claims to have seen signs of it.³

Stringer and the Lower Wound

John Stringer, the photographer, who saw the wounds up close and photographed them from the inside and the outside, pointed to the amorphous white blob near the hairline as "the" entrance into the head:

I think this was a piece of bone, but it was down near there — right about in there.

You're referring to what appears to be a piece of matter or something—

Yes

That is near the hairline?

Mm-hmm. But it was near there.

When asked if the "red spot... near the cowlick" was a wound, he insisted it was not. Asked again why he believed a wound was beneath the white blob near the hairline when the photographs do not definitely prove the white blob was a wound, he replied that his opinion was based on "having been there, and heard it and seen it..."⁵⁷

The Actual Body Versus Films

As mentioned earlier, the pathologists placed the location of "the" entrance wound in the head "slightly above" the EOP. The HSCA Medical Panel tried to convince these doctors the wound was four inches higher, based on low quality films. Instead of agreeing it was higher, they inexplicably claimed the location was even lower than their original placement.

(306) The panel was concerned about the apparent disparity between the localization of the wound in the photographs and X-rays and in the autopsy report, and sought to clarify this discrepancy by interviewing the three pathologists, Drs. Humes, Boswell, and Finck, and the radiologist, Dr. Ebersole. Each was asked individually to localize the wound of entrance within any one of several of the above-referenced photographs after reviewing the photographs, X-rays and autopsy report. In each instance, they identified the approximate location of the entrance wound on a human skull and within the photographs being in a position perceived by the panel to be below that described in the autopsy report. (See figs. 22 and 23, photographs of a human skull.) They also said it coincided with the rectangular white material interpreted by the panel as brain tissue present on top of the hair near the hairline. Each physician persisted in this localization, notwithstanding the apparent discrepancy between that localization and the wound characterized by the panel members as a typical entrance wound in the more superior "cowlick" area.¹

Finck Demonstrates His Expertise

Dr. Finck has pointed to a mass right at the junction of the hair with the neck. [Photograph #42]⁵⁸ [Discussion follows as to where he believes the EOP is.]

Dr. Finck... you described the wound of entrance as in the lower part of the head when you examined this photograph.

Just above the hairline.

... Is it your opinion that that object is below the external occipital protuberance?

I don't know.

Or above it?

I don't know. You don't see it, it is something you feel. As a matter of fact, you may have difficulty in finding it with your fingers. On a photograph I don't see it.

You stated earlier that it was slightly above the external occipital protuberance, is that correct?

From what I remember, correct. We have to refer to the report.

[...]

If you point that out on Dr. Davis here, where is that external occipital protuberance in relationship to the cerebellar hemispheres? Is it above or below? [Petty]

"I don't know."

[...]

Do you see any damage to the cerebellar hemispheres in these photographs that could have been caused by a missile?

I don't know.

[...]

I have pointed to color picture No. 43 at the point... that Dr. Finck is saying the entrance is and I am referring to the four color photographs of the brain in which I see no subarachnoid hemorrhage... My question is, if this is the point of entrance, isn't that at the level of the posterior cranial vault where the cerebellar hemispheres lie and would we not see subarachnoid hemorrhage if a slug had torn through there? [Loquvam]

Not necessarily, because you have wounds without subarachnoid hemorrhage.

You can have wounds in the brain without a missile track slug tearing through brain tissue?

I don't know. I cannot answer your question.⁵⁹

Another Revision

The HSCA Medical Panel apparently got one of the prosecutors to change his mind, at least for the moment:

Subsequently, however, in his testimony before the select committee, Dr. Humes agreed that the defect was in fact in the "cowlick" area and not in the area of the brain tissue.⁶⁰

More Revisions

When the three pathologists were interviewed by the Journal of the AMA, they all gave the original, 1963-4 location, "slightly above the EOP."⁶¹ Again, the reader is referred to the work of Dr. Gary Aguilar on this subject.⁴⁹

And in 1996, Boswell and Humes gave the original location. Boswell's understanding of Humes temporary acceptance of the HSCA's preferred location for an entrance - four inches *higher* in the cowlick area, is almost humorous:

Do you know whether Dr. Humes ever changed his position with respect to the location of the entry wound in the skull?

I've had a lot of people tell me that he did, before the House Committee that he agreed to lower this wound.

You're referring to the skull wound in the back of the head?

Yeah. But since I've talked with him... he denies that, and I think he now relies on his written report right here.⁶²

The Latest

When shown a photo of the back of the head with the white

image, Boswell's reaction was very different in 1996 than what it was in 1977:

I have seen that and worried and wondered about it for all these many years. Some people — many people have alleged that to be the wound. I don't think it is.⁶³

GEOMETRY AND BALLISTICS

If the throat wound was an entrance, the marksman had to be on the left side of the overpass. The external wound in the throat was about midline; the tracheal laceration was on the right; the alleged bruise was on the right lung, the hole in the hairline was in the right rear. Regardless of where Kennedy's head was turned, as long as his torso faced the front, a bullet from the right would have traversed his body on a leftward course. This is not to say that no shots were fired from the right. But an entrance in the throat would place one of the snipers on the left.

The throat wound as an exit seems equally viable. Anyone who requires proof that an exit wound can be small (though subtly different in appearance from an entrance) should consult the scientific literature on wounds created by non-tumbling jacketed bullets.⁶⁴⁻⁶⁸

If the small hole in the temple near the right eye described by some (and readily seen in at least one of the autopsy photos) was an entrance wound and not a hole caused by shrapnel, this bullet could also have come from the left. Kennedy was turned very much to his left, exposing part of the right side of his face to the left front. It is conceivable that a bullet entered this area, exited the right rear, and created the scar on the sidewalk. (And if - another big if - if there was a real hole in the windshield caused by a bullet from the front, this, too, would place a shooter on the left.) Anyone who doubts the existence of viable sniper nests left of the overpass should study photos taken in 1963; the place has since changed.

Many believe a bullet could not have come from Kennedy's right because, they say, it would have to exit the left side of the head. But this would depend on how far to the right the source of the shot was. A shot from the right, but not the far right (closer to the overpass), if tangential, could enter behind the right ear, and exit the right rear of the head, creating a rather shallow wound. It could explain a low head wound in the right rear in the absence of instant destruction to centers that control breathing. Such a trajectory would not explain all of the head damage, so this would have to be an additional head shot.

Since Kennedy was leaning so much to his left (left ear down, right ear up), a nearly horizontal shot from the extreme right could enter in front of the right ear, travel upward just beneath the skull, and exit the top of the head. (There was an excellent position for a sniper behind the Pergola, behind and just to the left of Zapruder's perch, obscured from anyone in the Bowers' tower by a tree.)

The HSCA turned to NASA's Tom Canning for help in analyzing the presumed trajectories, and got this response:

It has been emphasized that the present investigation should yield the range of possible and likely trajectories for each observed set of wounds. The *contrast* with the Warren Commission analyses, which centered on demonstrating the consistency of the observations with the hypothesis that all wounds were caused by bullets from the Depository window, is *very strong*.⁶⁹ (emphasis added)

Canning seems to be saying the "contrast" was "very strong" between the Warren Commission trajectories, which lead back to the Depository window, and the "likely trajectories," they found, which lead back to... somewhere else? This paper began with a report about the possibility of a third wound, and so the emphasis was not on trajectory, but on the *number* of shots. Here, again, the contrast between the official number of bullets that hit Kennedy and the number of bullets suggested by the testimony of several credible witnesses is

"very strong."

George Burkley, M.D., Kennedy's own physician, was with him during his emergency treatment and during his autopsy. When asked if he agreed with the Warren Report on *the number of bullets that struck Kennedy (two)*, he replied:

I would not care to be quoted on that.⁷⁰

CONCLUSION

We have no reliable information on the number, nature, or full extent of Kennedy's wounds, and no reason to believe in *any* of the official trajectories. The glaring omissions, selective vagueness, elastic language, and rampant revision infesting this case do not arise from a struggle to find the truth but, rather, from an evolving perception as to what supports the predetermined conclusions. Selected problems, not all of which were discussed in this report:

- Feigned ignorance of a bullet wound in the throat until it was too late to document its course.
- No mention in the autopsy report of the cerebellum's gross appearance.
- No mention in the autopsy report of the bullet holes (notches) in the skull, including a very prominent one.
- No mention in the autopsy report of the bullet hole (notch) in the smaller bone fragment.
- Radically different locations for the head entry.
- Radically different descriptions of the skull and brain damage.
- Radically different descriptions of the bullet fragments on x-ray.
- Radically different reporting on the number of metal fragments removed from the head (to be discussed in an upcoming paper).
- Different locations for the back wound.
- Missing: x-rays, photographs, skull fragments, the brain, tissue samples.

Was there something to hide? Could the witnesses quoted in this report have seen different aspects of it? Could it be the proposed third wound? If a bullet entered the throat, where did it exit? If a bullet exited the throat, where did it enter? If the back wound was as shallow as reported, then the third wound should be considered.

REFERENCES


1. Paragraph #299, 7 HSCA 206; "enhanced" photographs, viewed stereoscopically allegedly revealed "dried brain tissue adherent to hair"; this technology is limited, the images are open to interpretation, and the Medical Panel has shown strong bias on a number of issues, the Panel's head, Michael Baden, has shown more than bias, having made statements documented to have been false. For example, in his book, *Unnatural Death*, referenced below, he gave false dimensions of the scar of the entrance wound into Governor Corinally's body in order to promote the single bullet theory.
2. Finck, P., M.D. Testimony before HSCA Medical Panel, March 11, 1978, p97 [MD 30]
3. Autopsy Report, 16 WCH 978-983; 987-989
4. Humes, J. 2 WCH 351
5. Custer, J. ARRB Deposition, October 28, 1997 pp168-172:
6. Humes, J. 2 WCH 361
7. Boswell, J. T. HSCA Interview, August 17, 1977, p8 [MD 26]
8. Ibid, p12
9. Boswell, J.T. ARRB Deposition, February 26, 1996, p34
10. Ibid, p45
11. Ebersole, J. HSCA Testimony, March 11, 1978, p5 [MD 60]
12. Ibid, p20
13. Ibid, p51-2
14. Ibid, p64
15. Stringer, J.T. ARRB Deposition, July 16, 1996, pp191-2
16. Clark, William Kemp, M.D. CE 392, 17 WCH 2
17. News Conference of November 22, 1963, 3:16 PM [MD 41];
18. Humes, J. 1996, p96
19. Boswell, J. 1996, p76
20. Stringer, J.T. HSCA Interview, August 12, 1977, p12,16 [MD 19]
21. Perry, M. 3 WCH 374
22. Lipsey, R. HSCA Interview, January 18, 1978 [MD 87]
23. Pascal, Vern, September, 1998, personal communication
24. Boswell, J. 1996, p127
25. Ibid, p76
26. Karnei, R.F., ARRB Meeting Report, May 21, 1996, Call Report, March 10, 1997. [MD 178]; see also HSCA Interview, August 23, 1977 [MD 61]
27. Robinson, T. ARRB Interview with Tom Robinson, June 21, 1996. [MD 180]
28. Robinson, T. HSCA Interview, January 12, 1977 [MD 63]
29. Knudsen, G. Summary of meeting with ARRB and Gloria Knudsen and children, Terri and Bob, May 13, 1996. [MD 230]
30. Knudsen, R.L. HSCA Deposition, August 11, 1978 [MD 135]
31. McDonald, E. Meeting with ARRB, March 21, 1996. [MD 228]
32. O'Donnell, J. ARRB Telephone conversation with Joe O'Donnell, February 28, 1997; January 29, 1997. [MD 231]
33. Richter, B. Confidential memo from Bob Richter to Les Midgley, January 10, 1967 [MD 16]
34. Baden, M. *Unnatural Death: Confessions of a Medical Examiner*. New York: Random House, 1989, p16
35. Humes, J. 7 HSCA 251
36. Humes, J. 2 WCH 351
37. Ibid, p353
38. Ibid, p361
39. Lifton, D. *Best Evidence*, New York: Carroll & Graff, 1980, p 683
40. Humes, J. 2 WCH 353
41. Finck, P. Report from Lt Col. Finck to General Blumberg, February 1, 1965. [MD 28]
42. Review of Autopsy Materials by Humes, Boswell, and Finck, January 26, 1967. [MD 14]
43. Humes, J. 2 WCH 351
44. Humes, J. 2 WCH 352
45. Humes and Boswell, 7 HSCA 246
46. Humes, J. 1996, pp109-110
47. Boswell, J. 1996, p81
48. Humes, J. 2 WCH 354
49. Aguilar, G. Internet: <http://home.cynet/jfk/ag6.htm>. Gary L. Aguilar, M.D. is Chief, Division of Ophthalmology, St. Francis Memorial Hospital, San Francisco; Assistant Clinical Professor, Stanford University School of Medicine; Associate Clinical Professor, University of California at San Francisco, CA
50. Burkley, G. Receipt for Two Bone Fragments signed by George Burkley, November 27, 1963. [MD 30]
51. Memo to the File from Andy Purdy on "Search for missing autopsy materials," August 17, 1977, Cairns, A.B. [MD 19]
52. Harper Fragment, 7 HSCA 123
53. Harper Fragment. Commission Document 5, file #DL 89-43, November 26, 1963.
54. Letter to Milicent Cranor from William A. Harper, December 13, 1997
55. Harper, W., 7 HSCA 24
56. Baden, M. 1988, p52
57. Stringer, J. 1996, p196
58. Finck, P. 1978, p83
59. Ibid, p96-97

60. Humes, J. 7 HSCA 115
61. Breo, D.L. (1992) JFK's death — the plain truth from the MD's who did the autopsy. *Journal of the American Medical Association* 267, pp2794-2803]
62. Boswell, J. 1996, p62
63. Ibid, p151
64. Light, F.W., Jr. MD Gunshot wounds of entrance and exit in experimental animals. *J Trauma*; March, 1963:120-128 [Significance: throat wound could be an exit though small, and without shoring; depends on appearance of edges.]
65. Aguilar, J.C. Shored gunshot wound of exit. A phenomenon with identity crisis. *American Journal of Forensic Medicine and Pathology* 1983; 3:199-20 [Significance: when wounds are "shored" (skin held in place by strong material, so it does not bulge with bullet and develop long radiating lacerations) they must have abrasion collars; skin crushed between bullet and shoring material leaves skin residue on material. Personal, limited observation of M. Cranor: holes in shoring material seem to be the shape of the bullet, rather than slits; slits appear in unshored cloth.]
66. Butler, E.G., Pucket, W.O, Harvey, E.N., McMillen, J.H. Experiments on head wounding by high velocity missiles. *Journal of Neurosurgery* 1945; 2:358-363.
67. Owen-Smith, M. Chapter 5. High-velocity and military gunshot wounds. In: Ordog, Gary J. *Management of Gunshot Wounds*. New York: Elsevier, 1988, p70
68. DeMuth, Jr, W.E., Smith, J.M. High velocity wounds of muscle and bone: The basis of rational early treatment. *Journal of Trauma* 1966; 6(6):744-755. [Significance of ref #'s 62-64: jacketed bullets through empty skulls leave small exit wounds; it is oscillating brain that creates the large holes. Significance: if a bullet strikes an already exploded head, the damage can be much less than one may think.]
69. Canning, T.N. Letter to George Loquvam, March 2, 1978. JFK Collection, HSCA. (I thank Anna Marie Kuhns-Walko for sending me this remarkable document.)
70. Burkley, G. JFK Library Oral History Interview by William McHugh, October 17, 1967 [MD 67]

Kennedy Assassination Chronicles

Library Patrons

Please contact us to donate a Library Subscription.



Tippecanoe County Public Library, Lafayette, Indiana
Gallaudet University Library, Washington, D.C.

Brehm Prepreatory School, Carbondale, Illinois
Goodland High School, Goodland, Kansas
Johnson County Library, Overland Park, Kansas
Grand Prairie City Library, Grand Prairie, Texas
Dallas Public Library, Dallas, Texas
Greensburg Public Library, Greensburg, Pennsylvania
Cistercian Preparatory School, Irving, Texas
The State Historical Society of Wisconsin
University of Hartford Library, West Hartford, CT
Tulsa City-County Library, Tulsa, Oklahoma
Orange County Library, Lake Forest, California

Jerry Robertson
JFK Lancer, Ed Hoffman, and
Ron Freidrich
self-sponsored
Brad Parker
Project JFK, Mark Taylor
Hoffman Family/JFK Lancer
self-sponsored
Bob Schwartzmiller
Chris Marcellos
self-sponsored
George Michael Evica
Craig Roberts
Conway Family