

Department of Pathology and Oncology
University of Kansas Medical Center
Kansas City 12, Kansas

Copy No. 5

THE AUTOPSY

ARMED FORCES INSTITUTE OF PATHOLOGY

Handwritten: Harold: Keep this
JAL. see page 4, 5 etc 308 64

Washington, D. C.

1951

THE AUTOPSY

ARMED FORCES INSTITUTE OF PATHOLOGY

Washington, D. C.
1951


INTRODUCTION

The technique of the autopsy and the special bacteriological, chemical, and other methods that should be used to supplement morphological studies as described in the guide prepared by a Conference Group on Pathology of the National Research Council in 1942, and published in the Journal of Technical Methods and Bulletin No. XXIII of the International Association of Medical Museums, is hereby revised to meet the present requirements and regulations of the Armed Forces and the Veterans Administration.

Authority to revise and republish the original work was given to The Director, Armed Forces Institute of Pathology, by a letter, dated 7 February 1950, signed by the Secretary-Treasurer of the International Association of Medical Museums.

"All members of the Council of the International Association of Medical Museums approve the release of the copyright on Volume XXIII, Bulletin of the I. A. M. M., entitled 'Autopsy Technique' for use by the Armed Forces Institute of Pathology in the preparation of a new edition of a brochure of similar title."

New information, instructions, and quotations from regulations have been included under authority granted by The Surgeon General, Department of the Army, J. W. Kernohan, M. D., Mayo Clinic, and the Chief Medical Director, Veterans Administration, as appropriate and applicable.



ELBERT DeCOURSEY
Brigadier General, MC, USA
The Director
Armed Forces Institute of
Pathology

CONTENTS

| | | <u>Page</u> |
|------|---|-------------|
| I | Object and Scope | 1 |
| II | Permission | 1 |
| III | Armed Forces Governing Directives | 5 |
| IV | Equipment and Supplies | 9 |
| V | Abstract of Clinical History | 12 |
| VI | The Technique of the Autopsy | 13 |
| VII | Normal Weights and Measurements | 39 |
| VIII | The Descriptive Protocol | 41 |
| IX | Selection and Fixation of Blocks for Microscopic Study | 44 |
| X | The Selection and Fixation of Organs for Preservation as Museum Specimens | 46 |
| XI | Bacteriological Examination | 49 |
| XII | Special Studies of Viral Diseases | 57 |
| XIII | Immunological Examination | 58 |
| XIV | Toxicological and Chemical Examinations | 59 |
| XV | Special Evidentiary Objectives of the Medicolegal Autopsy | 65 |
| XVI | Restoration and Embalming of the Body | 75 |
| XVII | Collection of Data - Shipment of Specimens | 78 |

I. OBJECT AND SCOPE

The autopsy is a scientific inquiry, and should be regarded as constituting a post mortem examination of the body to determine the pathologic processes present in their relation to clinical phenomena and history; to determine the causes of the pathological processes; and to acquire information regarding the processes and nature of disease. The more effectively these ends are accomplished, the greater will be the contribution of the autopsy to the sum of knowledge concerning the disease from which the patient died, and thereby to clinical medicine, to public health, and to the interest of the family of the deceased. In the modern sense it includes a complete examination of the thorax, abdomen, head, spinal cord, bone marrow, and such other regions as are necessary or desirable. It should cover not only those structures which are the seat of obvious alteration, but all the organs of the body, because the normality of certain viscera is often quite as significant as the disease of others, and because organs that appear normal macroscopically are frequently abnormal microscopically. The gross examination should be amplified by microscopic studies, bacteriological and toxicological examinations, and such other investigations as may be indicated.

II. PERMISSION

In the United States the legal right to grant consent for the performance of an autopsy is based on common law, statutory laws of each of the 48 States, court decisions, and opinions of the legal counsels for the States, counties, and municipalities. The pathologist should familiarize himself with the laws governing autopsies in his State. The unauthorized performance of an autopsy is ground for a civil suit for damages, and in some States is a violation of the criminal code.

Property Rights in the Dead Human Body and Permission for Autopsy in Civilian Practice

The dead human body is property, but not in the usual legal sense in that it may not be bargained for, bartered, or sold. Property disposal is provided for in many States by law. The right of custody and the duty of legal disposal are concomitant. The right of custody of the body is generally in the surviving spouse, or, if there is not surviving spouse, in the next of kin in the order of their relationship to the decedent.

II. PERMISSION

Many state statutes permit autopsies under specified circumstances without the consent of the person entitled to custody of the body. Where the applicable statute would not so permit under the facts of the case, consent to an autopsy should be obtained from the surviving spouse or the next of kin.

The consent, usually in writing, need not be in any special form, but should include the following points: Date, name of grantor, relation of grantor to deceased, name of deceased, name of grantee, list of examinations allowed (trunk, neck, head, extremities, spinal cord), signature and address of grantor, signature of a witness (usually the physician who secured the consent), signature of the administrator of the hospital (indicating his approval), name of the funeral director to whom the body is to be released, and the hour when the funeral director has been told that the body will be available. Many pathologists prefer to add a sentence concerning the retention of organs. If this is desired on either civilian or military permits, the Conference Group recommends the following:

The pathologist is authorized to retain such organs or parts of organs as may be necessary for medicolegal investigations, further study, or the educational and research purposes of the laboratories.

Anatomical Acts

If the deceased has no known relatives or friends, common law places the responsibility for custody and burial on the owner or tenant of the building, or on the master or owner of the ship or on the administrator or superintendent of the hospital in which death occurred. In most States common law has been superseded by statutory laws for the Disposal of Dead Human Bodies at Public Expense or by Anatomical Acts.

These Anatomical Acts generally require that all dead human bodies unclaimed by relatives or friends shall come into the custody of an Anatomical Board. The following excerpts from the law in Missouri will serve to illustrate the basic principles. (From an Act Approved by the Legislature on June 14, 1939, Laws of Missouri, 1939; Pages 510-514; Revised Statutes of Missouri, 1939, Article 3, Chapter 59, Sections 9998 to 10004, inclusive.)

Section 4. Superintendents or wardens of penitentiaries,

II. PERMISSION

houses of correction and bridewells, hospitals, insane asylums and poor houses, and coroners, sheriffs, jailers, city and county undertakers, and all other State, county, town or city officers having the custody of the body of any deceased person required to be buried at public expense, shall be and hereby are required immediately to notify the secretary of the Board or the person duly designated by the Anatomical Board or by its secretary to receive such notice whenever any such body or bodies come into his or their custody, charge or control, and shall, without fee or reward, deliver, within a period not to exceed thirty-six (36) hours after death, except in cases within the jurisdiction of a coroner where retention for a longer time may be necessary, such body or bodies into the custody of the Board and permit the Board or its agent or agents to take and remove all such bodies, or otherwise dispose of them:....

Section 5. The secretary of the Board shall cause to be distributed the bodies aforesaid, to any of the educational institutions mentioned in section 2 hereof, upon the acceptance and compliance by said educational institution with the provisions of this article, in proportion to the number of students in attendance at said educational institutions where the subject of human anatomy is studied or investigated. The Board may employ a carrier or carriers for the conveyance of such bodies, which bodies shall be well enclosed within a suitable encasement, and carefully deposited free from public observation. Said carrier shall obtain a receipt from the officer or other person having custody of any dead body subject to the provisions of this act for each body received by said carrier, and said receipt shall set forth the name of the deceased, if known, and all other data that will aid in identifying such body, and shall deposit this receipt with the secretary of the Board.

Section 6. Bodies required to be buried at public expense shall be under the exclusive custody and control of the Board. It is hereby declared unlawful for any person or persons to hold any autopsy on any dead human body subject to the provisions of this article without first having obtained the consent of the secretary of the Board or his accredited agent. The consent of any person for an autopsy on his or her body shall not in any way present or affect the application of this article.

II. PERMISSION

The Coroner or Medical Examiner and the Dead Human Body

In many States there are laws which provide that certain types of death shall be the subject first of an investigation to determine the causes and circumstances thereof and second of a magisterial inquiry or inquest to determine what steps shall be taken in the interests of law enforcement. These duties devolve on the county coroner or on the medical examiner. The following statute in New Jersey will serve to illustrate the type of death that should come to the attention of law enforcement agencies:

When, in the county, any person shall die as a result of violence or by casualty or suicide, or suddenly when in apparent health, or when unattended by a physician, or within 24 hours after admission to a hospital or institution, or in prison, or in a suspicious or unusual manner, the superintendent or medical director of the institution in which he died, or the physician called in attendance, shall immediately notify the office of the chief medical examiner of the known facts concerning the time, place, manner, and circumstances of the death. Immediately upon receipt of such notification the chief medical examiner or an assistant medical examiner shall fully investigate the essential facts. If necessary, he shall go to the dead body and take charge thereof.

In most jurisdictions the authority to order the performance of an autopsy incident to the conduct of an official medicolegal inquiry rests with the coroner, with the prosecuting attorney, or with a coroner's jury.

III. ARMED FORCES GOVERNING DIRECTIVES

Regulations, statutes, and rendered opinions pertaining to autopsies are quoted for information and guidance.

'An Army aviation cadet and a civilian pilot instructor were killed in an airplane accident at a civilian air training school not owned by nor subject to the exclusive jurisdiction of the United States. The local authorities asked the Army to conduct an investigation in the nature of a coroner's inquest. Held: The request may not be granted. While the Army may

III. ARMED FORCES GOVERNING DIRECTIVES

investigate the deaths of military personnel, wherever they may occur, for purposes of military administration, an Army investigation in the nature of a coroner's inquest may only be conducted when death occurs on a military reservation subject to the exclusive jurisdiction of the United States. (A. W. 113.) SPJGA 013.35 (1942/3809), Aug. 21, 1942., Bull. JAG 166).'

'In cases involving sudden or violent death of military personnel occurring at places over which the United States does not have exclusive jurisdiction, it is customary for the military authorities to make such investigation as appear to be warranted by the particular needs of the military service. The military authorities have no power to hold inquests required in those cases by applicable state statutes, but may make only such investigations as are expressly or impliedly authorized or required by Federal laws or regulations. The coroner of the county in which the dead body of a member of the Military Establishment is found is not presently prohibited by Federal law or regulations from exercising his jurisdiction to conduct the inquest required by state law. However, in the interest of comity and the obvious need of safeguarding military information vital to the national defense, such inquests should be made in such a manner as will not interfere with the official duties of the military personnel in the conduct of their investigations and the safeguarding, removal or other disposition by them of any military equipment or material that may be involved. SPJGA 1943/4937, April 13, 1943.

Note: The statement in JAG 013.2, Aug. 28, 1918 (Dig. Op. JAG 1912-1940, sec. 471), 'that a county coroner should not take jurisdiction of the case and hold an inquest where the death of a person in military service occurs in the performance of a military duty, such as flying an aeroplane,' is to be considered in the light of the whole situation generally, and not as a limitation on the coroner's jurisdiction. II Bull. JAG 192, 193.'

The act of 4 June 1920 (41 Stat. 810), as amended (10 U.S.C. 1585; see pp. 453-454, MCM, 1941) provides:

"When at any post, fort, camp or other place garrisoned by the military forces of the United States and under the exclusive jurisdiction of the United States, any person shall have been found dead under circumstances which appear to

III. ARMED FORCES GOVERNING DIRECTIVES

require investigation, the commanding officer will designate and direct a summary court-martial to investigate the circumstances attending the death; and for this purpose, such summary court-martial shall have powers to summon witnesses and examine them upon oath or affirmation. He shall promptly transmit to the post or other commander a report of his investigation and of his findings as to the cause of death."

The term "any person" includes persons other than those subject to military law. The installation commander may order an autopsy when necessary to the satisfactory completion of the inquest. It is to be noted that under the mentioned act an inquest is not required in the case of every death but only those which occur "under circumstances which appear to require investigation." Further, even in those instances where an inquest is deemed necessary by the installation commander, an autopsy need not be ordered unless necessary to the satisfactory completion of the inquest. When such autopsy is deemed necessary by the installation commander, present Department of the Army policy requires the prior consent of the next of kin (Par. 11d (2), AR 40-610, 1 Dec. 1950). Such consent should be secured whenever possible. But in the last analysis when the installation commander has ordered an inquest under the mentioned act and in his sound discretion an autopsy is necessary to the satisfactory completion of the inquest, the installation commander may order the autopsy performed without the consent of the next of kin.

Although it may not be necessary legally, it is probably good policy to notify the coroner or police and obtain consent before proceeding with an autopsy in the case of a civilian death occurring on a military post under unusual circumstances. Further, consent should be obtained from the proper civilian authority before performing an autopsy on military personnel brought to a military hospital following death in unusual circumstances not on a military post.

Department of the Army, Circular No. 49, under date of 15 June 1951, announces Standard Form No. 523, "Authorization for Post-Mortem Examination".

AR 30-1820, 15 Nov. 1943, C 4, 18 June 1946 - Paragraph 8

Inspection of remains. - In order to verify that the contractor for the burial service fully complies with all provisions of his contract and to assure that when the remains arrive at their burial destination they are in an acceptable state of preservation, the purchasing and contracting officer or his representative with the surgeon

III. ARMED FORCES GOVERNING DIRECTIVES

or his representative together will inspect the remains both after they are embalmed and while they are nude, and after they are clothed and in the casket. Both the purchasing and contracting officer or his representative and the surgeon or his representative will, after completing the inspection, accomplish a certificate as prescribed on Preparation Room Report (WD AGO Form 10-15) and in TM 10-285 as to -

a. Whether the remains have been embalmed properly or, if embalming is impossible due to the condition of the remains, that adequate preservative measures have been taken to insure that the remains will be in good condition upon arrival at destination.

b. That the remains have been washed and shaved, unless this is impossible due to their condition.

c. That the casket and other supplies and materials furnished by the contractor are strictly in accordance with specifications.

d. That the remains are clothed in underwear and a proper uniform in a clean and serviceable condition. If the condition of the remains precludes this, the remains will be wrapped in a sheet or blanket and the uniform placed on top thereof in the casket.

e. That a flag in good condition has been furnished.

AR 40-610, 1 Dec. 1950 - Paragraph 11

c. (2) Inspection and record. - In cases of burials at Government expense, the commanding officer or his commissioned representative will inspect each body immediately after death, and again in the nude after embalming process to insure that embalming has been correctly and thoroughly accomplished. (See AR 30-1820.) The commanding officer or his representative will file in the medical treatment facility a signed record of the fact of compliance with the above requirement.

d. Autopsies.

(1) Deceased military personnel. - An autopsy will be performed upon the body of any person dying in the military service when the commanding officer or the surgeon of a station or command deems such procedure necessary in

III. ARMED FORCES GOVERNING DIRECTIVES

order to determine the true cause of death, and to secure information for the completion of military records.

- (2) Deceased civilians. - In the case of a civilian dying in a medical treatment facility or on a military installation inside the continental United States, when an autopsy is deemed necessary, written permission from the next of kin will be obtained before the autopsy is performed. If permission is unobtainable, and an autopsy is required to complete records of death in compliance with local, State or Federal law, report will be made to civil authorities for necessary action.
- (3) Prompt performance. - The performance of an autopsy will occasion minimum delay in delivering the remains to the mortician. Where possible, the autopsy surgeon will be available on call at all times to expedite performance of the examination. Autopsies will normally be completed without delay and the body made immediately available to the mortician. Technique employed will insure minimum interference with the embalming function, particularly disturbance of the circulatory system. Embalming may be performed prior to autopsy provided the autopsy surgeon is agreeable.
- (4) Records. - Complete records of autopsies performed will be filed in the medical treatment facility. Copies of autopsy protocols will be furnished in accordance with AR 30-1820, SR 40-410-10, and AR 600-550.

Manual of the Medical Department, USN, Par. 2918

In all cases of death occurring in the Navy under unnatural or suspicious circumstances, or where the cause of death is obscure or not apparent and a decision affecting pension or gratuity is involved, the medical officer shall recommend to the commanding officer such postmortem examination or autopsy as may be required in determining the exact cause of death. In all cases the autopsy must be performed in a manner requiring no more disfigurement of the body than is necessary to obtain the evidence necessary (Art. 1841 (5), N.R.). The results of all autopsies shall be fully recorded in the reports of death and health records.

III. ARMED FORCES GOVERNING DIRECTIVES

Navy Regulations, Art. 1841 (5).

Especial care shall be exercised that the evidence of autopsies shall not cause unnecessary distress to parents, and that the wounds so made shall be neatly closed, and that packings and dressings employed shall be clean and suitable material.

Other Directives

a. AR 40-410, BuMed Cir Ltr 50-8, AFR 160-38, 15 Feb. 50, "Armed Forces Institute of Pathology."

b. SR 40-410-10, BuMed Cir Ltr 50-50, AFR 160-55, 8 June 1950, and Changes 1, 10 November 1950, and 2, 12 February 1951, "Central Facilities Provided for Department of Defense by Armed Forces Institute of Pathology."

c. AR 600-550, 23 June 1947, and C 2, 26 Dec. 47, C 3, 1 Sep. 48, C 5, 3 Feb. 50, and C 6, 14 Nov. 50, "Deceased."

IV. EQUIPMENT AND SUPPLIES

The autopsy room should be so located that there is abundant, preferably north, light. If it is necessary to use artificial light, care should be taken that the colors are not misrendered. The floor and walls should be made of material that is easily cleaned and washed.

The following instruments are recommended for the proper performance of an autopsy (Figures 1, 2, 3, & 4):

Joint Army-Navy Medical Supply Catalogue

| | | |
|-----------|-------------------------------------|------|
| 9-493-425 | Postmortem Kit, complete | ea 1 |
| 9-124-125 | Case, Instruments, Postmortem Kit | ea 1 |
| 9-131-575 | Case, Postmortem Kit, Empty | ea 1 |
| 3-191-300 | Chisel, Bone, 18 mm. | ea 1 |
| 3-234-510 | Cutter, Cast, Stryker, 110 Volt, AC | ea 1 |
| 3-259-400 | Director, Grooved, Probe Point, 5½" | ea 1 |

IV. EQUIPMENT AND SUPPLIES

| | | |
|-----------|--|-------|
| 3-311-800 | Forceps, Bone Cutting, Straight Liston, 8-3/4" | ea 1 |
| 3-334-200 | Forceps, Dressing, Uterine Curved Buzeman, 10" | ea 1 |
| 3-347-100 | Forceps, Hemostatic, Straight Rankin 6 1/4" | ea 2 |
| 3-370-900 | Forceps, Tissue Spring 5 1/2" | ea 2 |
| 3-403-300 | Gouge, Bone 12 mm. | ea 1 |
| 3-435-800 | Knife, Amputating, Liston 6" | ea 1 |
| 3-437-100 | Knife, Cartilage, Postmortem 7" | ea 2 |
| 3-447-320 | Blade, Operating Knife, #21, 6s | pkg 2 |
| 3-447-820 | Handle, Operating Knife, #4 | ea 2 |
| 3-449-900 | Knife, Plaster, 5" | ea 1 |
| 3-468-400 | Mallet, Metal, Orthopedic | ea 1 |
| 3-522-300 | Needle, Suture, Postmortem, Half-curved, Cutting Edge 5" | ea 3 |
| 3-538-400 | Osteotome, Stille, 30 mm. | ea 1 |
| 3-569-500 | Probe, General Operating, Straight 10" | ea 1 |
| 3-631-100 | Saw, Amputating, Satterlee, 8" Blade | ea 1 |
| 3-642-100 | Scissors, Enterotomy, 8" | ea 1 |
| 3-650-640 | Scissors, Operating, Straight, Double Blunt, 7" | ea 2 |
| 3-680-280 | Sound, Urethral, Curved, Van Buren, 18 Fr | ea 1 |

Non-Standard Items

| | | |
|----------------|---|------|
| Non-Standard 3 | Clamp, calvarium, Bigelow, Aloe #37330 (For Autopsy Kit) | ea 1 |
| Non-Standard 3 | Chisel, Virchow, skull opening, Aloe #37260 (For Autopsy Kit) | ea 1 |
| Non-Standard 3 | Chisel, Brunetti, Precision, chrome plated, 275 mm. for right side, Aloe #37270 (For Autopsy Kit) | ea 1 |
| Non-Standard 3 | Chisel, Brunetti, precision, chrome plated, 275 mm. for left side, Aloe #37270 (For Autopsy Kit) | ea 1 |
| Non-Standard 3 | Saw, rachitomy, adjustable, chrome plated, Aloe #38340 (For Autopsy Kit) | ea 1 |

THE AUTOPSY




Figure 1




Figure 2

THE AUTOPSY




Figure 3

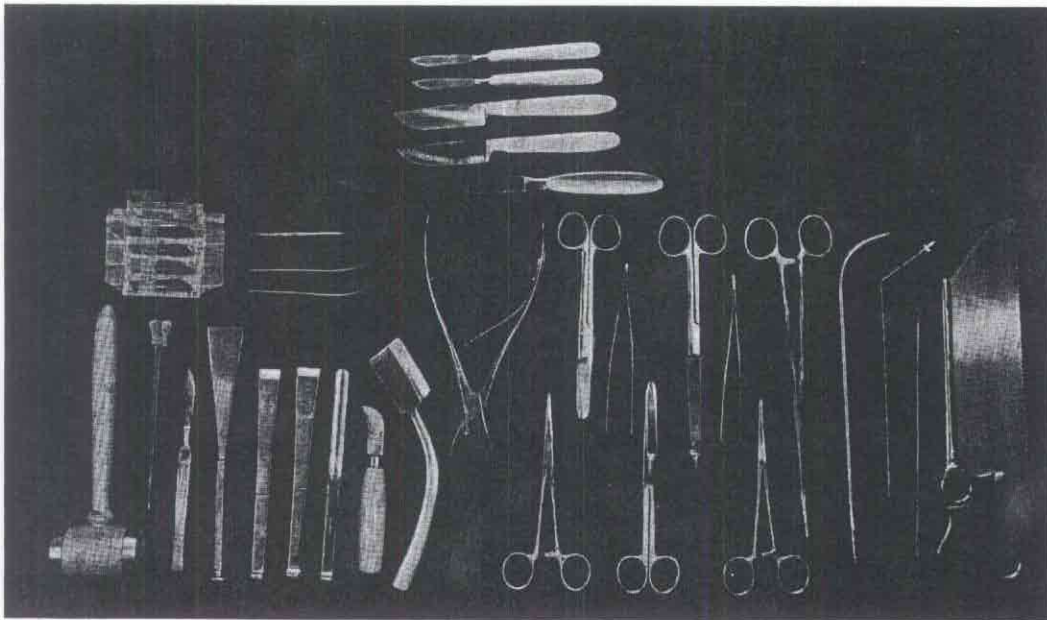


Figure 4

IV. EQUIPMENT AND SUPPLIES

Non-Standard 3 Knife, postmortem, full section, 18"
cutting edge, hollow ground,
Aloe #38000 (For Autopsy Kit) ea 1

Non-Standard 3 Saw, postmortem, Aloe precision,
Electric, Ser. #336889, Aloe
Stock #38370, complete as listed: ea 1
1 ea Drill, Bone
1 ea Blade, Circular Saw (Extra)

Non-Standard Councilman's Bone Cutting Forceps,
Box-lock ea 1

Fixatives

In so far as possible, the following fixatives for blocks for subsequent histological preparations should be prepared in advance.

Formalin. For general purposes, this is the usual fixative. It is prepared by mixing one volume commercial formalin with nine volumes of water. The 10% formalin should always be neutralized by the addition of precipitated calcium carbonate or finely divided marble, so that a layer 1 or 2 cm. deep lies at the bottom of the container.

Ethyl Alcohol. This should be used only for special purposes. For fixation of tissues for glycogen stains, use absolute or 95% alcohol. For certain cytological methods in the central nervous system, use 95% alcohol.

Zenker's Fluid. The formula is as follows:

Potassium bichromate..... 2.5 gm.
Mercuric chloride..... 5.0 gm.
Distilled water..... 100.0 cc.

At the time of use, add 5 cc. glacial acetic acid. If mercuric chloride is not available, 2.5 gm. zinc chloride may be substituted. For fixation of bone marrow, in which there are spicules of bone, add 10 cc. glacial acetic acid in order to decalcify.

IV. EQUIPMENT AND SUPPLIES

Bouin's Fluid. The formula is as follows:

Glacial acetic acid..... 5 cc.
Commercial formalin..... 25 cc.
Saturated aqueous picric acid..... 75 cc.

Regaud's Fluid. This fixative is recommended for all tissues in Rickettsial disease.

3% aqueous potassium bichromate..... 80 cc.
Commercial formalin..... 20 cc.
After fixation for 24 to 48 hours wash in running water and store in 70% alcohol.

V. ABSTRACT OF CLINICAL HISTORY

Before starting the autopsy, the pathologist should familiarize himself with the clinical history, clinical diagnosis, and the special points of interest to the clinician. It shall be the responsibility of the clinician to see that this information is in the hands of the pathologist before the scheduled time for the autopsy. The abstract should follow the general form outlined below.

CLINICAL ABSTRACT

Name: _____ Status: _____ Serial No.: _____

Date of Admission: _____

Complaints:

1. _____
2. _____
- etc.

Habits: Alcohol, tobacco, narcotics, etc.

Family History: List all information bearing on deaths, illnesses and hereditary tendencies.

Previous Personal History: Including all illnesses, operations, wounds, fractures, venereal infections and all personal history in general. List all services in Army or Navy.

V. ABSTRACT OF CLINICAL HISTORY

Present Illness: Onset of present illness with chronological abstract of illness.

Physical Examination: Weight, height, temperature, pulse, respiration and blood pressure. List all positive findings by systems.

Laboratory and X-Ray Findings:

Progress Notes: To include abstract of patient's illness and hospitalization with major therapeutic measures, etc.

Place, Date and Hour of Death:

Clinical Diagnosis:

VI. THE TECHNIQUE OF THE AUTOPSY

The performance of the autopsy includes both an art and a science. The reputation of the pathologist depends in part on the precision and neatness with which he conducts an autopsy. The decorum of the autopsy room reflects a deep respect for the dead human body. The procedures are carried out with efficiency and with dignity. The body, instruments and table are kept clean and orderly at all times.

Inspection

Inspection of the body is an integral part of the autopsy, and may yield valuable information. Both the anterior and posterior surfaces should be carefully scrutinized. The more important observations include signs of violence, fractures, recent or healed wounds and lacerations, identifying marks, as tattoo designs, edema of the legs, back, scrotum, or face, distension of the abdomen, jaundice, hemorrhage from the orifices of the body or into the subcutaneous tissues or cornea, decubital ulcers, abnormal pigmentation, tumors, anomalies, deformities, distribution of hair and subcutaneous fat, and the symmetry of the trunk and extremities. The oral and nasal cavities should be examined and the state of the mucosa noted. The number, character, and state of preservation of the teeth may be indicative of certain lesions or diseases. The eyelids should be elevated and the color, size, and shape of each pupil recorded, with

VI. THE TECHNIQUE OF THE AUTOPSY

other pertinent observations. The external genitalia should be carefully examined for scars, hernias and other lesions. The general state of development and nutrition should be evaluated.

Special attention should be given to lesions caused by water and air blasts, high velocity explosives, and crush injuries. In death from explosives, examine the track of the projectile and the tissues at a distance from it. The kidneys should be carefully examined both grossly and microscopically in crush injuries. Preserve the entire central nervous system in all types of injury incident to modern warfare, even if there is no gross pathologic change. Proper study of these lesions is urgently needed.

Primary Incision of Thorax and Abdomen

The best incision (Figures 5 and 6) for both men and women is the Y-shaped incision. This begins at a point near the acromial process of the clavicle, extends in a curve below the corresponding breast to the xyphoid process of the sternum, and thence in similar manner to the opposite acromial process. In order to prevent leakage after repair, this incision should not extend into the axilla. From the xyphoid process, the incision is extended downward in the midline to the symphysis pubis, passing to the left of the umbilicus and not entering the peritoneum. The peritoneum is carefully incised and the primary incision of the abdomen completed, using two fingers of the left hand as a director, so as to avoid injury to the intestines or other viscera. The attachments of the abdominal wall to the costal border are severed so as to lay open the abdominal cavity. If this is not sufficient, the rectus muscles are cut near their pubic attachment. The incision over the thorax should extend through the skin, subcutaneous fat, and muscle, so that these tissues can be dissected from the bony thoracic wall as far cephalad as 2 cm. above the sternoclavicular joint. Care should be taken that the skin is not punctured as the tissues are elevated.

Select an appropriate block from the pectoralis major muscle and breast for microscopic study.

Exposure and Inspection of the Thoracic Viscera

If a tension pneumothorax is suspected a needle attached to a syringe should be inserted into the pleural cavity through one of

THE AUTOPSY

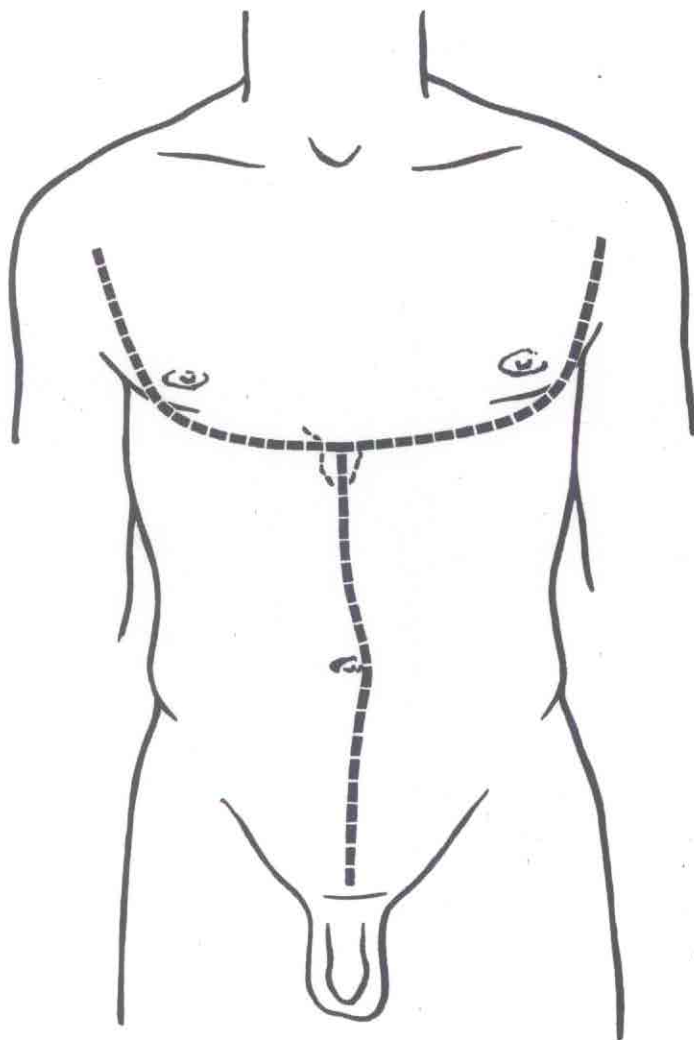


Figure 5

THE AUTOPSY

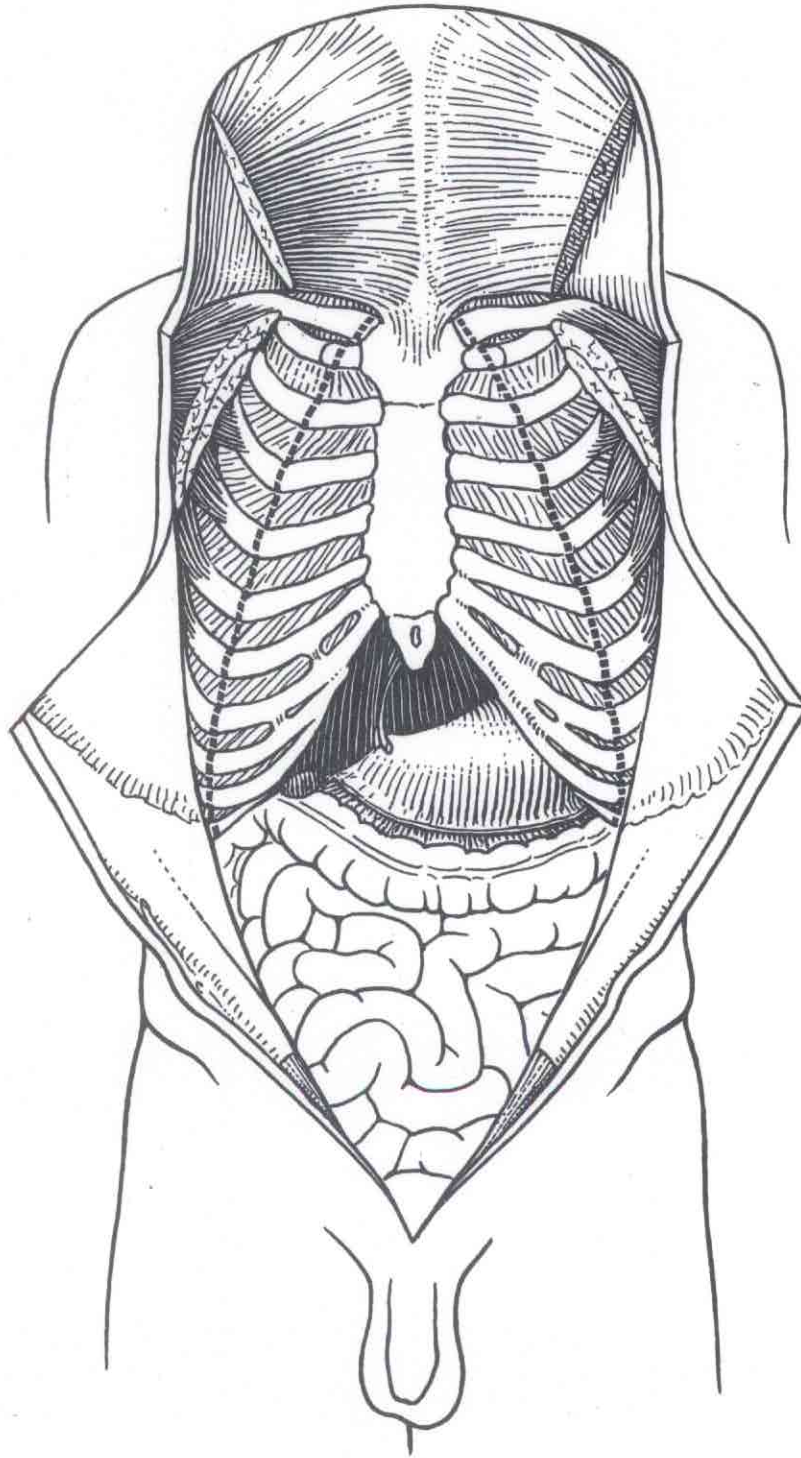


Figure 6

VI. THE TECHNIQUE OF THE AUTOPSY

the intercostal spaces at this point. The thorax is opened by cutting the costal cartilages just medial to the costochondral junction. A large, heavy cartilage knife should be used for this purpose, and the blade kept parallel with the surface of the body to prevent the point from entering the pleural cavity and puncturing the lung. If the cartilages are calcified a rib shears must be used. The sternoclavicular joint is disarticulated by cutting the capsular ligaments and the first rib is then severed with a rib shears. Starting on one side, the diaphragm is dissected free from the last rib, and the triangular "chest plate" is removed, thus exposing the heart, the superior mediastinum, and the pleural cavities. During removal the character of the tissue in the anterior mediastinum and the size and consistency of the lymph nodes in this region should be noted. It will be found desirable to place a hemostat on the internal mammary arteries and veins on each side as they turn from the sternum to enter the superior mediastinum. This will prevent the leakage of blood into the pleural cavities before they have been carefully inspected.

Pleural cavities. Pleural cavities should be inspected and the presence or absence of fluid and adhesions noted. If there are adhesions they should not be broken, but rather the parietal layer of the pleura elevated from the underlying intercostal muscles and ribs and taken with the lung. If the adhesions are broken the adjacent lung tissue is frequently torn.

Pericardial cavity. The pericardial cavity should be opened carefully and the amount of fluid, the condition of the surfaces, and the presence of adhesions noted. At this point a culture of the heart's blood should be taken according to the technique outlined in another section of this directive.

Superior mediastinum. The thymus should be dissected from the tissues of the superior mediastinum, weighed, measured, and examined. Fix all or part of the thymus for microscopic study. The innominate vein as it crosses high in the superior mediastinum should be doubly ligated and divided, so that the 3 major branches of the arch of the aorta may be fully visualized in a dry field. Any abnormalities in the lymph nodes or other structures of the superior mediastinum should be noted.

Neck Organs

The organs of the neck may be exposed by further elevation of

VI. THE TECHNIQUE OF THE AUTOPSY

the skin and subcutaneous tissues. The size and shape of the thyroid gland and pathological lesions in the trachea and larynx may then be fully visualized. If the neck organs are to be removed the skin should be elevated as far cephalad as the arch of the mandible. With a long knife, the floor of the mouth is penetrated, and all of the structures separated cleanly from the mandible. The posterior wall of the soft palate and the pharynx are divided and all contained structures separated from the vertebral column as far as the superior orifice of the thorax. It is necessary to leave the carotid arteries for proper embalming of the tissues of the face and head. Fix blocks of the thyroid, parathyroid, and other tissues as indicated for microscopic study.

Inspection of the Peritoneal Cavity and Abdominal Organs

The amount of fluid, the character of the surfaces, and the presence of adhesions should be noted. The size, the character, and the position of the omentum may yield information concerning focal lesions within the abdomen. The size and relative position of each of the viscera should be recorded in relation to fixed landmarks; for example, the liver might be recorded as extending so many centimeters below the costal margin in the mid-clavicular line.

Fluid in Serous Cavities

In any instance in which there is an increased amount of fluid in the serous cavities, save not less than 50 cc. in a clean dry vessel. Determine the specific gravity and the character of the cells in the centrifugalized sediment. Cultures and smears should be made if indicated (see section XI).

Calculi

All concretions and calculi should be saved in a clean dry vessel for subsequent chemical analysis.

Selection of Sections for Microscopic Study

In the following description of the technique of the autopsy the routine blocks to be selected for histological study are indicated.

VI. THE TECHNIQUE OF THE AUTOPSY

In all cases the prosector should use his judgment in the fixation of additional blocks to illustrate specific lesions (see section IX).

General Principles in the Dissection and Examination of the Viscera

The following two general considerations should be borne in mind in the dissection of the viscera:

1. The primary incisions in each organ should be so placed as to:
 - a. Expose the largest possible surface.
 - b. Open the structures that enter through the hilum.
 - c. Make visible the ductal and vascular systems.
 - d. Preserve the orientation and relations of the organ as a whole.

All further incisions should be placed parallel to the first.

2. No organ is to be separated from a connecting structure until the intervening tissue has been dissected and examined--the ostia of the renal arteries, the renal arteries and veins, and the ureter should be examined before the kidneys are removed from the body; the ampulla, the bile ducts, the gall bladder, the portal vein and the hepatic artery should be examined before the liver is separated from the stomach and duodenum; and the mesentery, mesenteric arteries and veins should be explored before the intestine is separated from the mesentery.

Weights and Measurements of the Viscera.

All viscera should be weighed and measured before they are cut, except the heart. After an organ is cut, blood leaks from the cut surface and the weight may be changed by as much as 20 percent or more. In general the weight, the greatest length, the greatest breadth, and the greatest depth should be recorded. In some organs special measurements are indicated; for example, the circumference of the valvular rings and the thickness of the walls of the heart and the thickness of the cortex and of the entire substance of the kidney (see section VII).

VI. THE TECHNIQUE OF THE AUTOPTSY

Removal of Viscera

Two general forms of technique are available, each of which must be modified to meet special conditions and the experience of the prosector. These are the organ by organ method, and the evisceration method.

Removal of the Viscera Organ by Organ

The incision in the pericardial sac should be extended upward to expose the root of the aorta and the pulmonary artery. With a long knife open the right ventricle and the first part of the pulmonary artery, and examine the lumen for thrombi and emboli. Grasp the heart in the left hand with the apex upward, and with a knife divide the inferior vena cava and the pulmonary veins, where they emerge through the parietal pericardium. Cut the pulmonary artery at least 2 cm. above the valves, and the superior vena cava at its entrance into the pericardium. Finally divide the aorta not less than 5 cm. above the aortic valves and remove the heart.

Heart. With the scissors extend the primary incision in the right ventricle to the apex and thence cephalad along the attachment of the wall of the right ventricle to the posterior interventricular sulcus. The internal point of the scissors, preferably an enterotome, is guided through the tricuspid orifice, and the right atrium opened as far cephalad as the superior vena cava (Fig. 7). Further incisions through the orifice of the inferior vena cava will allow complete exposure of the cavity of the right atrium. The fluid and clotted blood within the cavities of the right atrium and right ventricle should be carefully removed and the character of the heart held firmly in the left hand and with the greatest convexity of the left ventricle directly upward, incise the left ventricle with a knife and open the cavity. This incision should be so placed as to enter the ventricle between the two papillary muscles of the mitral valve. With an enterotome directed through the mitral orifice cut upward through the mitral ring and the wall of the left atrium. To expose fully, extend this incision into several of the major pulmonary veins. In both the right and the left atria a secondary incision should extend into the atrial appendages, fully exposing the cavities of these structures. With a scissors or knife extend the incision in the left ventricle to the apex and thence cephalad through the wall of the left ventricle, close to the anterior interventricular sulcus, until

THE AUTOPSY

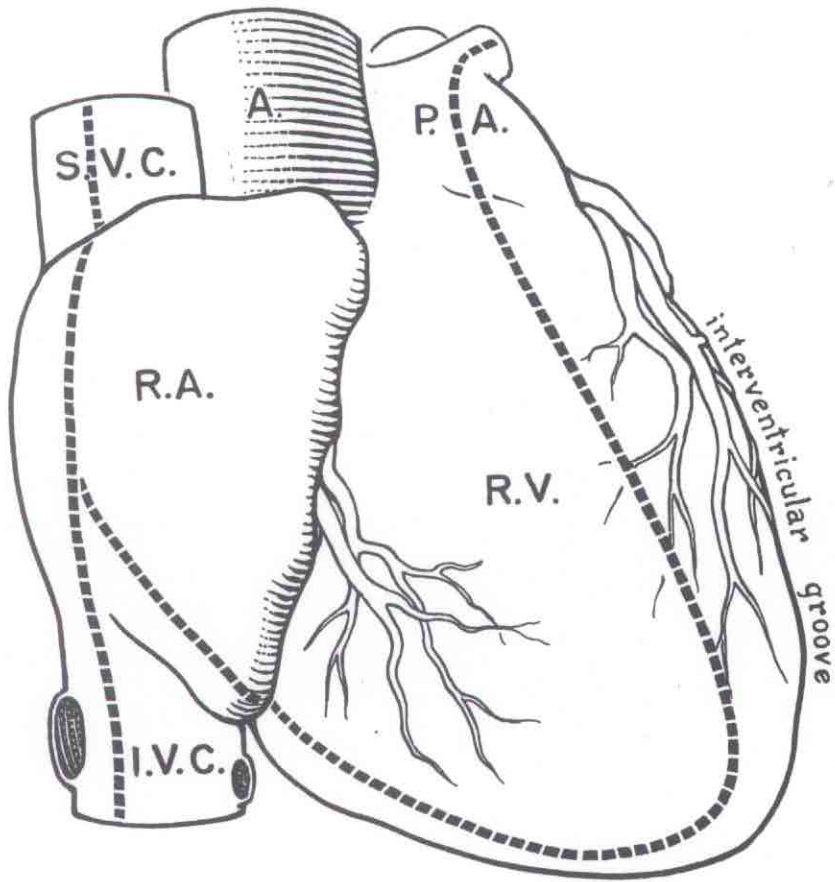


Figure 7

THE AUTOPSY

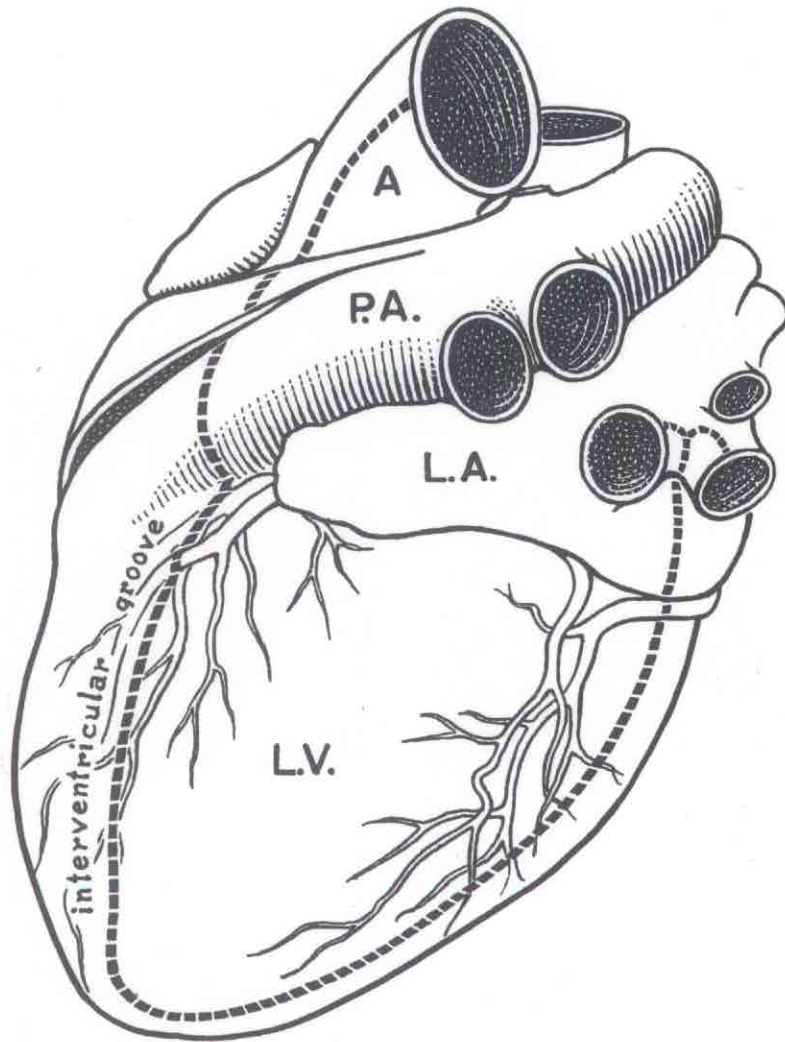


Figure 8

VI. THE TECHNIQUE OF THE AUTOPSY

a point is reached 1 cm. above the level of the pulmonary valves. The scissors should then be guided through the aortic orifice and the aortic ring and aorta opened. The cavities, valves, endocardium and walls of the left atrium and ventricle should be examined (Fig. 8). The size of the ostia of the coronary arteries in the aorta should be recorded. The coronary arteries are to be examined by multiple cross-sections every 5 mm. and should include routinely the left descending coronary artery, the left circumflex coronary artery, and the right coronary artery. The weight of the heart, the thickness of the walls of each atrium and ventricle, and the circumference of each of the valvular rings should be recorded.

For a thorough microscopic study of the heart, numerous sections are necessary. For routine purposes the best section is one taken along the incision in the left ventricle close to the posterior interventricular sulcus. This block, about 3 to 4 mm. in thickness, includes the lower part of the atrial wall, the mitral ring, the mitral valve, the upper part of the ventricular wall and the pericardium covering both the atrium and ventricle. If a section is taken from the ventricular wall alone, the most representative area is the wall of the left ventricle adjacent to one of the papillary muscles. The best section of the right ventricular wall is one from the conus arteriosus.

Trachea and bronchi. With a scalpel and scissors open the anterior surface of the lower part of the trachea and the major bronchi in the midline. Note the presence of fluid and mucus and the character of the mucosa and the wall. Examine and section the lymph nodes at the hilum of each lung and about the bifurcation of the trachea.

Lungs. Divide all structures at the hilum of each lung, noting the contents of the lumens of the bronchi, pulmonary arteries, and pulmonary veins as they are cut. The internal structure of the lung is best exposed by a single incision along the long axis of each lung, extending from the most lateral convexity toward the hilum. This incision should be so placed as to open the maximal surface of each of the lobes of the lung. Any further incisions should be made parallel to the primary incision. The major bronchi are to be opened with a scissors. The lymph nodes at the hilum should be carefully exposed and examined. The principal branches of the pulmonary artery and vein on the cut surface of the lung should be examined for thrombi and emboli, and opened further if necessary. Weigh each lung and select representative blocks for

VI. THE TECHNIQUE OF THE AUTOPSY

microscopic study. Blocks from the various lobes may be cut in distinctive shapes so as to indicate the origin of each.

Spleen. By blunt dissection open the lesser omental sac through the gastrocolic omentum. Examine the anterior surface of the pancreas and the splenic artery and vein coursing on the superior surface of the body and tail of the pancreas. Lift the spleen and divide the vessels at the hilum, so that it may be removed. Weigh the spleen and measure length, breadth and thickness. The cut surface is exposed by a single incision extending from the greatest convexity toward the hilum. Further incisions should be parallel to the first. Fix a characteristic part of the organ including the capsule.

Mesentery and intestine. Examine the mesentery by multiple sections across the mesenteric arteries and veins and lymph nodes. Ligate the jejunum with a double ligature a few centimeters below the ligament of Treitz. With a sharp, long knife separate the intestine from the mesentery as close to the intestinal wall as is possible. On reaching the ileocecal region incise the peritoneum of the posterior abdominal wall and lift the cecum and ascending colon free from the surrounding tissues. Separate the transverse colon from the omental attachments to the stomach, and similarly raise the descending colon free from the posterior abdominal wall. Place a double ligature about the sigmoid colon 5 to 6 cm. above the sigmoidorectal junction. Cut between the two ligatures and lift the entire intestine from the body. With an enterotome open the small intestine along the mesenteric attachment and the large intestine along one of the taenia. The appendix may be examined by multiple cross-sections or by longitudinal incision opening the lumen. As the intestine is opened note the fluidity, color, and other characteristics of the intestinal content. Sections of representative regions are to be taken. Do not rub the fingers over the mucosa or wash it with water before the blocks are taken. Record the thickness, consistency and color of the mucosa and of the wall as a whole. Remove the mesentery by dividing it at its attachment to the posterior abdominal wall.

Gall bladder and bile ducts. Open the first and second portions of the duodenum by an incision on the anterior surface. Locate the major and minor duodenal papillae. Exert pressure on the gall bladder and note whether or not bile streams from the major papilla. Divide the peritoneal covering on the lateral wall of the duodenum and expose the lower part of the common bile duct. With a scalpel open the duct and with scissors extend the incision upward into the hepatic ducts and the cystic duct, and downward into the ampulla. Note the

VI. THE TECHNIQUE OF THE AUTOPSY

fluidity and character of the contained bile and the presence or absence of calculi. The gall bladder should be opened by a longitudinal incision in a way that makes possible the collection of the contained bile in a clean dry bottle. Inspect the bile for concrements and examine the mucosa and wall for evidences of acute and chronic inflammations, tumors and deposits of cholesterol. Similarly open the portal vein in the hepatoduodenal ligament as far distally as the confluence of the superior mesenteric and the splenic veins. Examine the hepatic artery by multiple cross-sections.

Stomach and duodenum. If there is no pathologic change indicating the desirability of retaining the liver, bile ducts, and duodenum in one piece, cut across the structures in the hepatoduodenal ligament and remove the duodenum, pancreas, and stomach in one mass. If there is any pathologic change in the cardiac end of the stomach or in the lower part of the esophagus, the esophagus should be included. Extend the incision in the anterior surface of the first part of the duodenum along the greater curvature of the stomach as far as the cardiac end of the esophagus. Note the character of the stomach content, the thickness, rugae of the mucosa, and other features of the wall such as mosaic pattern. Extend the incision in the second part of the duodenum so as to open the entire length of the third part.

Pancreas. Note the exposed pancreas and examine the cut surface by multiple cross-section or by a single frontal section extending from the inferior border to the superior border. On the cross section locate the pancreatic duct; note its size, content, and character of the wall. Remove the pancreas from the duodenum by careful dissection. Weigh it and measure the long axis, the width of the head, and the average depth. Select blocks of the head, body, and tail for microscopic study. The islands are more numerous in the tail, and this block should be used for routine purposes.

Liver. Remove the liver by division of the triangular ligaments and the hepatic veins as they pass into the inferior vena cava at the lower border of the diaphragm. Weigh the liver and measure the three principal axes. The first incision in the liver should extend on the long axis and be directed from the greater convexity toward the porta hepatis. Further incisions should be parallel to the first. Place representative blocks including the capsule in fixative.

VI. THE TECHNIQUE OF THE AUTOPSY

Adrenals. Dissect the adrenal glands and free them of all extraneous tissue. Weigh the adrenals and examine the cut section by multiple sagittal cuts. Place a part or all of each organ in 10 per cent formalin.

Aorta. With an enterotome open the aorta along the anterior surface. Inspect the intima, the wall, and the orifices of each of the principal branches, noting the size and position. Finally open the inferior vena cava from the level of the diaphragm to the bifurcation of the iliac veins. If there is no pathologic change in the renal arteries or renal vein they may be divided at a point 1 cm. from the aortic orifice.

Urinary tract. With a finger or blunt instrument separate the bladder by dissection into the extraperitoneal tissues of the retro-symphysial space, so that the bladder and prostate are completely free from the pelvic wall. Further dissection posteriorly will separate the rectum and with a long amputating knife, the urethra may be cut distal to the prostate and the rectum not less than 2 cm. above the anorectal junction. The pelvic organs are then reflected upward and outward, exposing the great iliac vessels, and all tissues are separated from the curve of the sacrum and the convexity of the lower lumbar vertebra. Free the kidneys and ureters from the surrounding tissue and divide whatever remaining tissue is required to remove the kidneys, the ureters, bladder, and internal genitalia from the body in one block.

Kidneys. The kidney is grasped in the left hand, with the lateral convexity upward. With a long knife the kidney is accurately divided into an anterior and a posterior half, cutting through the entire substance of the kidney parenchyma, leaving only the soft tissues of the pelvis to hold the two halves together. With a scissors the pelvis and the ureters are opened completely. The renal artery and the renal vein are opened well into the region of the pelvis. The kidney may now be separated by division of the ureter. The weight and length, breadth, and depth should be recorded. The capsule is stripped, exposing the surface of the parenchyma. From each kidney remove a block of tissue 3 to 5 mm. in thickness, including cortex, medulla, and pelvic mucous membrane and place in fixative. Measure the thickness of the cortex and the thickness of the entire renal substance.

The bladder. The bladder is opened by a vertical incision on the anterior surface extending from the fundus to within a few

VI. THE TECHNIQUE OF THE AUTOPSY

millimeters of the internal urethral orifice. As the bladder is opened note the amount and physical characteristics of the contained fluid. Save some in a clean glass vessel if indicated. The cavity is inverted, and the mucosa and wall carefully inspected. Select a block to include all layers of the wall for fixation.

Prostate. The prostate is examined by multiple coronal sections cut from the anterior surface, 5 to 6 mm. apart, extending from the base of the bladder to the apex of the prostate. Note the size and inspect the mucosa of the urethra. Place one of these complete coronal blocks in fixative.

Rectum and sigmoid. The rectum and sigmoid are opened with an enterotome along the posterior midline. The fecal material is removed and the mucosa and wall examined. The rectum is then dissected from the posterior wall of the prostate and bladder, thus exposing the seminal vesicles.

Seminal vesicles. Multiple longitudinal incisions, 2 to 3 mm. apart, along the long axis serve to expose the wall and the lumens of the vesicles. The thickness, the character of the wall, and the physical characteristics of the contained fluid should be noted. Place a representative block in fixative.

Aorta. Open the thoracic aorta and the esophagus. Examine the structures between these two for the thoracic duct and lymph nodes.

Testes and epididymides. By sharp dissection open the inguinal canals and pull the testes from the scrotum. Cut the attachments of the tunica to the base of the scrotum and remove the testes. The tunica vaginalis is opened and the amount and physical characteristics of the contained fluid noted. Each testis and epididymis is then sectioned by a single incision extending through both structures. The weight and measurement should be recorded and observations made on the thickness of the tunica, the tissues of the epididymis, and the consistence of the testis. With a clean forceps determine the ease with which the tubules string from the cut surface. Place a block of the opposite half including the tunica on one surface in fixative.

Vas deferens. The vas deferens should be examined by multiple cross-sections without, however, completely dividing the structure. The size and richness of the pampiniform plexus, together with the

VI. THE TECHNIQUE OF THE AUTOPSY

presence of thrombi within it, should be noted.

Methods for the removal and examination of the female genital organs are given on page 38.

Removal of the Viscera En Masse

Following the primary incision and inspection of the viscera of the thorax and abdomen, the first step in the removal of the organs en masse is the insertion of a finger or blunt instrument into the extraperitoneal tissues of the retrosymphysial space and the separation of the bladder and prostate from the pelvic wall. Further dissection posteriorly will separate the rectum, and with a long amputating knife cut the urethra distal to the prostate, and the rectum not less than 2 cm. above the anorectal junction. The pelvic organs may then be reflected upward and outward, exposing the great iliac vessels, which are divided along the brim of the pelvis, and all of the tissues separated from the curve of the sacrum and the convexity of the lower lumbar vertebra (Figures 9 & 10).

The second step is the separation of the structures in the superior orifice of the thorax. With good hemostasis, effected by the use of hemostats, the 3 major branches of the arch of the aorta are successively divided, the trachea and esophagus are cut, the thoracic organs elevated and pulled downward, and separated by blunt or sharp dissection from the vertebral column.

The third step is the separation of the diaphragm and peritoneum from the lateral and posterior abdominal walls. On each side the diaphragm is cut from the attachment to the abdominal wall in such a way that the incision enters the abdominal wall extraperitoneally. By blunt dissection the remainder of the diaphragm and the entire lateral and posterior peritoneal walls are separated from the underlying muscle. This dissection is carried posteriorly to the vertebral column, behind the kidneys and the adrenal glands.

The fourth step is the separation of the abdominal organs from the vertebral column. This is best accomplished by lifting the thoracic organs onto the left side of the body and rotating the abdominal organs to expose the right side of the vertebral column. By careful sharp dissection the vena cava and aorta are separated from the vertebral column, and the mass of thoracic and abdominal organs may be lifted from the body.

THE AUTOPTSY

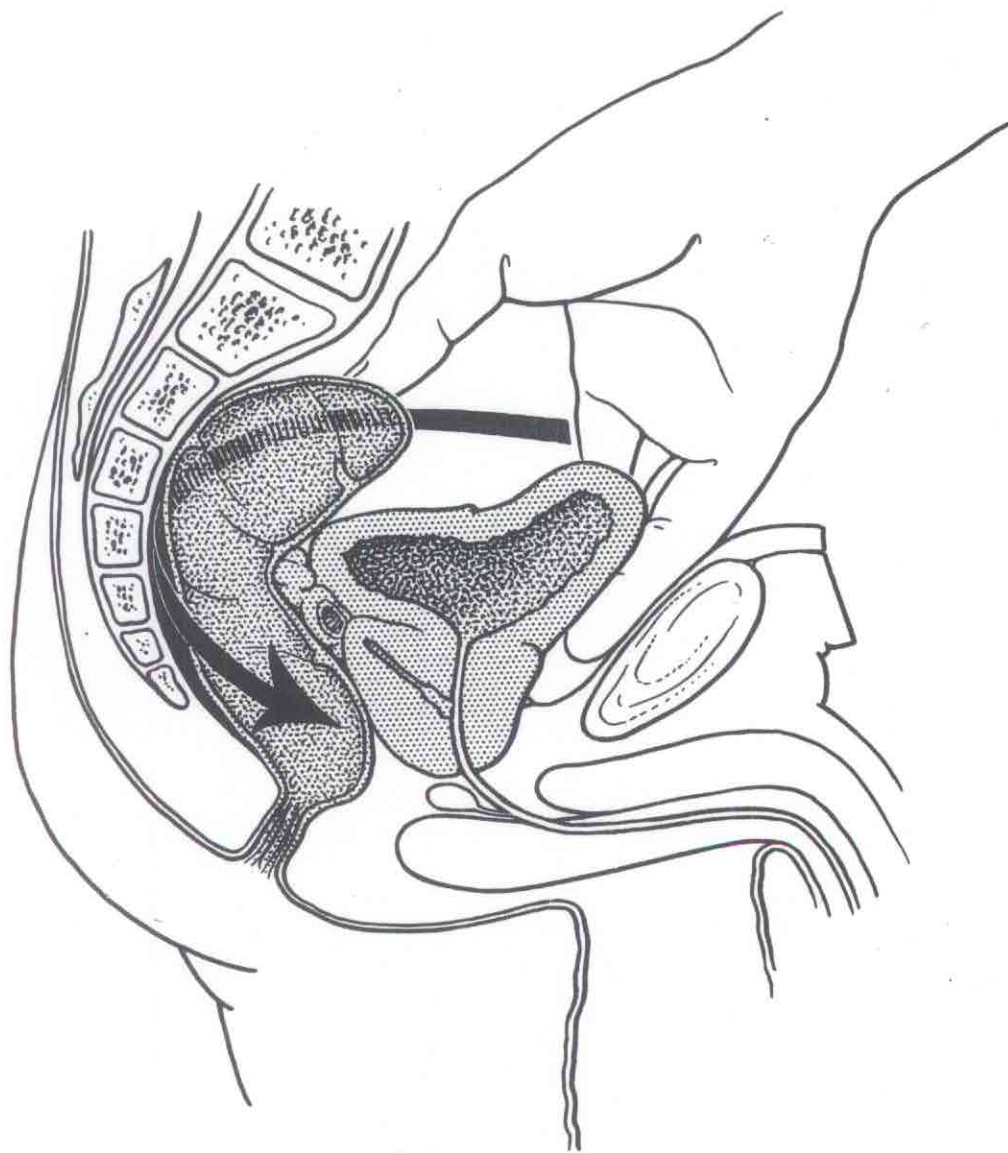


Figure 9

THE AUTOPTSY

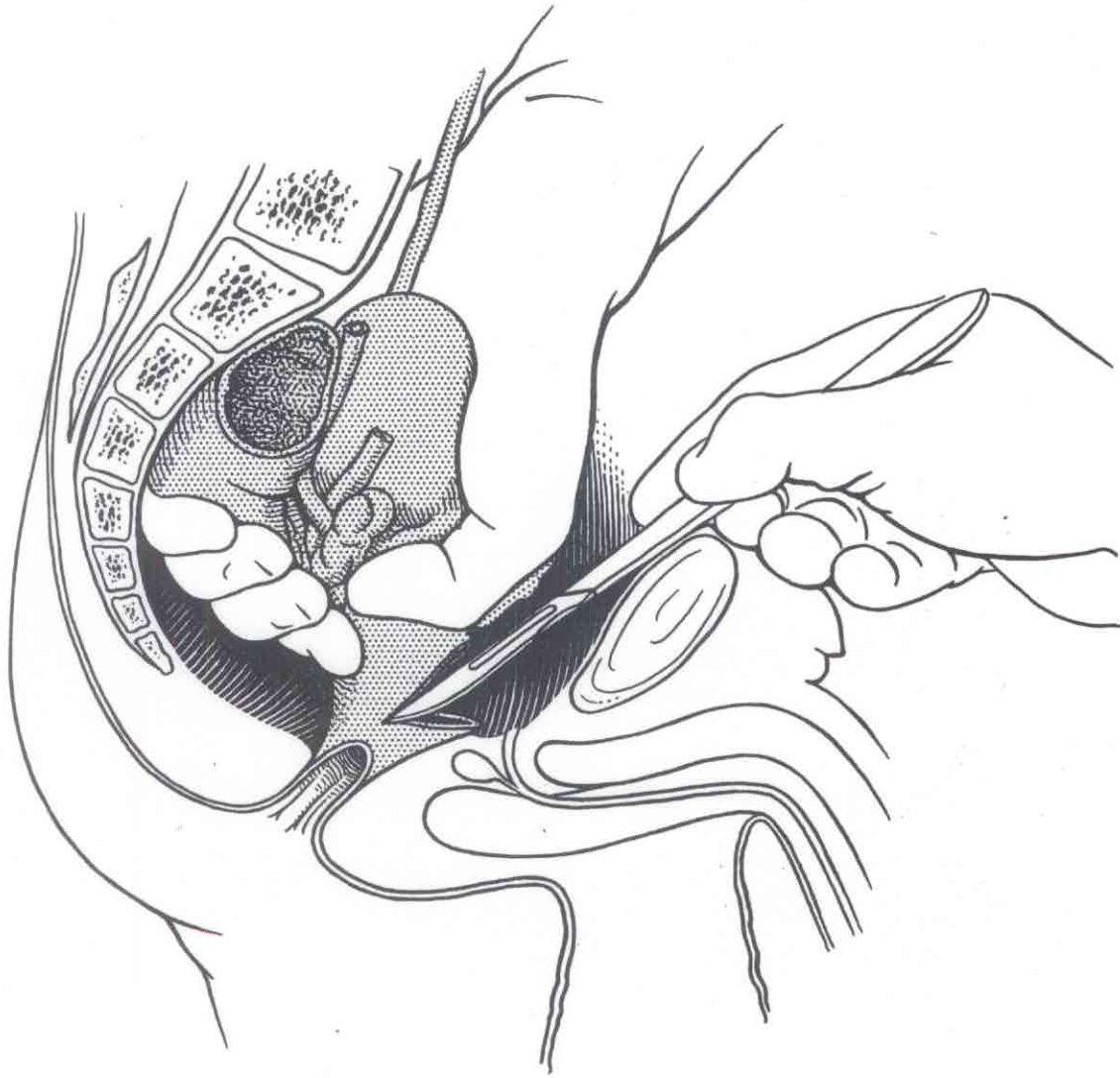


Figure 10

VI. THE TECHNIQUE OF THE AUTOPSY

Removal of testes. The testes should be removed by enlarging the inguinal canal, inverting the scrotum, and cutting the attachment of the tunica vaginalis to the skin of the lower part of the scrotum. If there are related pathologic changes in the genital tract the testes should be elevated and freed before the pelvic organs are removed, so that the entire length of the vasa and the attachments to both the epididymides and the seminal vesicles are preserved.

Removal of external genitalia. If it is necessary to remove the tissues of the floor of the pelvis or a part or all of the external genitalia, the incision in the abdominal wall should be extended caudally over the symphysis pubis to the base of the penis or to the crest of the labia majora. With the large blunt cartilage knife the symphysis pubis is divided and the legs are pulled outward, thus exposing the urogenital triangle and the base of the penis. Further dissection will depend upon what is desired (Figures 11 & 12). In men the skin may be incised on the dorsal surface and the contained tissue dissected free and taken with the pelvic organs. In women the single incision at the anterior commissure of the labia, and the entire external genitalia removed with the pelvic organs.

Dissect the tissues and organs in the following manner:

Retroperitoneal structures in the midline. Place the organs on the table with the posterior surface upward. Insert a scissors into the iliac veins and open these veins and the inferior vena cava as far cephalad as the right renal artery, which should not be divided until it is opened. Dissect and examine the retroperitoneal lymph nodes. Open the aorta from the iliac arteries as far cephalad as the arch. Examine the azygos vein and the thoracic duct. Within the aorta note the size and character of the orifices of the major branches, particularly the renal arteries.

Adrenals. From the region of the angle formed by the diaphragm, the aorta, and the kidneys, dissect and remove the adrenal glands. Free them of all extraneous tissue and examine the cut section by multiple sagittal cuts. Place all or a part in 10 per cent formalin.

Divide the aorta at the level of the diaphragm. Free the kidneys and ureters from the surrounding tissue and separate the aorta from the root of the mesentery by sharp dissection, noting the size and the thickness of the wall of all divided vessels. Reflect the aorta, renal arteries, and kidneys downward, following

VI. THE TECHNIQUE OF THE AUTOPSY

the path of the ureters, until the only structure connecting the pelvic organs with the remainder of the abdominal organs is the sigmoid colon. Divide the sigmoid just above the rectosigmoidal junction. There is thus secured one specimen containing all of the organs of the genito-urinary tract. It should be further dissected as follows:

Kidneys. The kidney is freed of surrounding tissue and grasped in the left hand, with the lateral convexity upward. With a large knife the kidney is accurately divided into an anterior and a posterior half, cutting through the entire substance of the kidney parenchyma, leaving only the soft tissues of the pelvis to hold the two halves together (Figure 13). With a scissors the pelvis and the ureter are opened completely. The renal artery and the renal vein are opened from the orifice well into the region of the pelvis. The kidney may now be separated by division of the renal artery and vein and the ureter. The weight and size should be recorded. The capsule is stripped, exposing the surface of the parenchyma. For each kidney remove a block of tissue 3 to 5 mm. in thickness, including cortex, medulla, and pelvic mucous membrane, and place in fixative. Measure the thickness of the cortex and the thickness of the entire renal substance.

The bladder. The bladder is opened by a vertical incision on the anterior surface extending from the fundus to within a few millimeters of the internal urethral orifice. As the bladder is opened note the amount and physical characteristics of the contents. Save some in a clean glass vessel if indicated. The cavity is inverted, and the mucosa and wall carefully inspected. Select a block to include all layers of the wall for fixation.

Prostate. The prostate is examined by multiple coronal sections cut from the anterior surface, 5 to 6 millimeters apart, extending from the base of the bladder to the apex of the prostate. Note the size of the urethra and inspect the mucosa. Place one of these complete coronal blocks in fixative.

Rectum. The rectum is opened with an enterotome along the posterior midline. The fecal material is removed and the mucosa and wall examined. The rectum is then dissected from the posterior wall of the prostate and bladder, thus exposing the seminal vesicles.

Seminal vesicles. Multiple longitudinal incisions, 2 to 3 mm. apart, along the long axis serve to expose the wall and the lumens of the vesicles. The thickness, the character of the wall, and the physical characteristics of the contained fluid should be noted.

THE AUTOPTSY

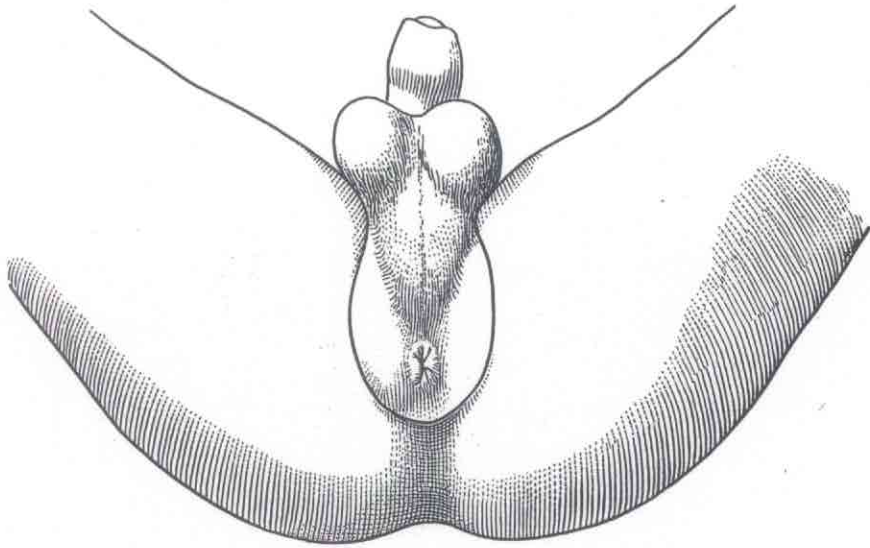


Figure 11

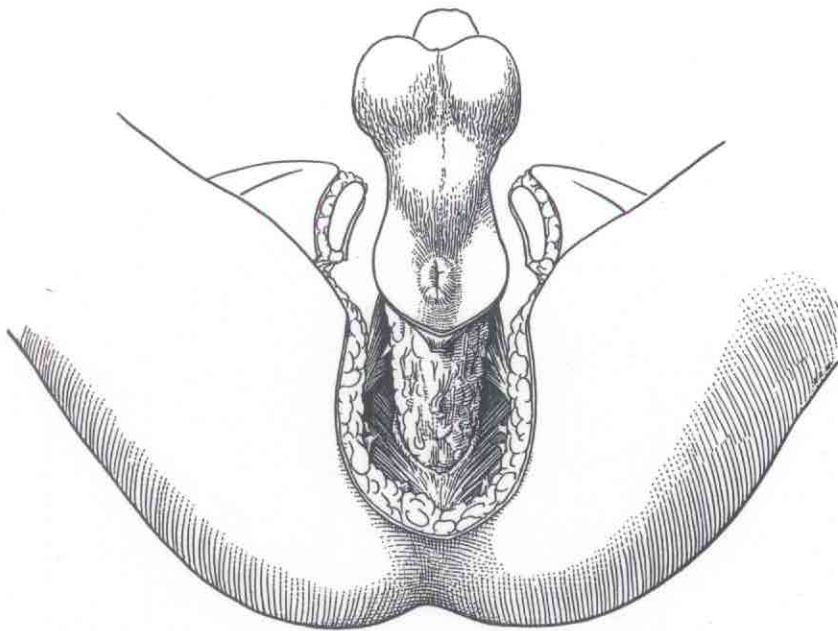


Figure 12

THE AUTOPTSY

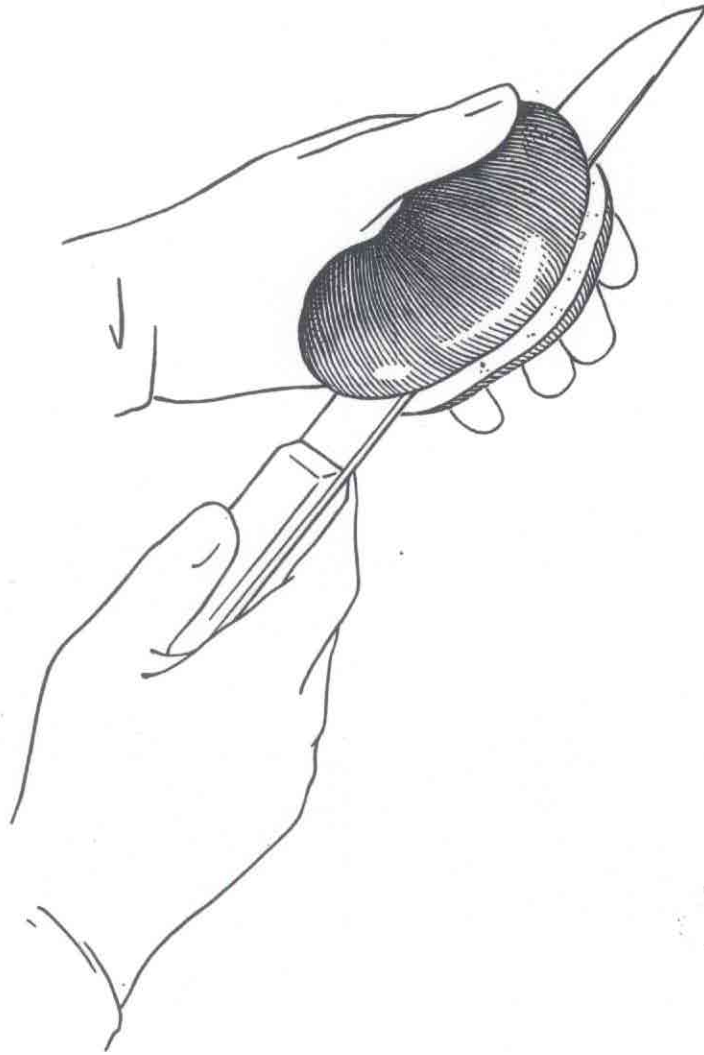


Figure 13

VI. THE TECHNIQUE OF THE AUTOPSY

Place a representative block in fixative.

Testis and epididymis. The tunica vaginalis is opened and the amount and physical characteristics of the contained fluid noted. Each testis and epididymis is then sectioned by a single incision extending through both structures. The weight and measurement should be recorded and observations made on the thickness of the tunica, the tissues of the epididymis, and the consistence of the testis. With a clean forceps determine the ease with which the tubules string from the cut surface. Place a block from the opposite half with tunica on one surface in fixative.

Vas deferens. The vas deferens should be examined by multiple cross-sections without, however, completely dividing the structure. The size and richness of the pampiniform plexus, together with the presence of thrombi within it, should be noted.

Esophagus. The next step in the dissection and examination of the viscera is to open the esophagus along the posterior midline. The mucosa and wall should be examined and the esophagus then elevated and dissected free from the adjacent posterior mediastinal structures as far caudally as the cardia. Cut a block not over 5 mm. wide from the side for microscopic study.

The thoracic and abdominal viscera may then be completely separated from one another by division of the inferior vena cava just above the caval hiatus in the diaphragm, thus leaving the diaphragm with the abdominal organs.

Heart. The thoracic viscera are placed on the table with the anterior surfaces upward, and with the heart grasped in the left hand an incision is made in the wall of the right ventricle just to the right (of the heart, left of the prosector) of the anterior interventricular sulcus. With the scissors, extend this incision into the pulmonary arteries and carefully inspect the lumens of these structures for the presence of emboli or thrombi. With the scissors, extend the primary incision to the apex and thence cephalad along the attachment of the wall of the right ventricle to the posterior interventricular sulcus. The internal point of the scissors, preferably an enterotome, is guided through the tricuspid orifice, and the right atrium opened as far cephalad as the superior vena cava. Further incisions through the orifice of the inferior vena cava will allow complete exposure of the cavity of the right atrium. The fluid and clotted blood within the cavities of the right atrium and right ventricle should be carefully removed and the character of the

VI. THE TECHNIQUE OF THE AUTOPSY

endocardium, the valves, and the musculature observed. With the heart held firmly in the left hand and with the greatest convexity of the left ventricle directly upward, incise the left ventricle with a knife and open the cavity. This incision should be so placed as to enter the ventricle between the two papillary muscles of the mitral valve. With an enterotome directed through the mitral orifice cut upward through the mitral ring and the wall of the left atrium. To expose fully, extend this incision into several of the major pulmonary veins. In both the right and the left atria a secondary incision should extend into the atrial appendages, fully exposing the cavities of these structures. With a scissors or knife extend the incision in the left ventricle to the apex and thence cephalad through the wall of the left ventricle, close to the anterior interventricular sulcus, until a point is reached 1 cm. above the level of the pulmonary valves. The scissors should then be guided through the aortic orifice and the aortic ring and aorta opened to join the incision made in the thoracic aorta as far as the arch. As the aortic ring is cut it is necessary to divide the pulmonary artery. Make certain that this is done not less than 1 cm. above the valve. The cavities, valves, and endocardium, and walls of the left atrium and ventricle should be examined. The size of the ostia of the coronary arteries in the aorta should be recorded. The coronary arteries are to be examined by multiple cross-sections every 5 millimeters, and should include routinely the left descending coronary artery, the left circumflex coronary artery, and the right coronary artery. The coronary arteries should not be opened with a scissors. The heart may now be removed by division of all structures as they pass through the parietal pericardium and separation of the aorta from the adjacent trachea and bronchi. The weight of the heart, the thickness of the walls of each atrium and ventricle, and the circumference of each of the valvular rings should be recorded.

For a thorough microscopic study of the heart, numerous sections are necessary. For routine purposes the best section is one taken along the incision in the left ventricle close to the posterior interventricular sulcus. This block, about 3 to 4 millimeters in thickness, includes the lower part of the atrial wall, the mitral ring, the mitral valve, the upper part of the ventricular wall and the pericardium covering both the atrium and ventricle. If a section is taken from the ventricular wall alone the most representative area is the wall of the left ventricle adjacent to one of the papillary muscles. The best section of the right ventricular wall is one from the conus arteriosus.

Lungs. The internal structure of the lung is best exposed by a

VI. THE TECHNIQUE OF THE AUTOPSY

Removal of testes. The testes should be removed by enlarging the inguinal canal, inverting the scrotum, and cutting the attachment of the tunica vaginalis to the skin of the lower part of the scrotum. If there are related pathologic changes in the genital tract the testes should be elevated and freed before the pelvic organs are removed, so that the entire length of the vasa and the attachments to both the epididymides and the seminal vesicles are preserved.

Removal of external genitalia. If it is necessary to remove the tissues of the floor of the pelvis or a part or all of the external genitalia, the incision in the abdominal wall should be extended caudally over the symphysis pubis to the base of the penis or to the crest of the labia majora. With the large blunt cartilage knife the symphysis pubis is divided and the legs are pulled outward, thus exposing the urogenital triangle and the base of the penis. Further dissection will depend upon what is desired (Figures 11 & 12). In men the skin may be incised on the dorsal surface and the contained tissue dissected free and taken with the pelvic organs. In women the single incision at the anterior commissure of the labia, and the entire external genitalia removed with the pelvic organs.

Dissect the tissues and organs in the following manner:

Retroperitoneal structures in the midline. Place the organs on the table with the posterior surface upward. Insert a scissors into the iliac veins and open these veins and the inferior vena cava as far cephalad as the right renal artery, which should not be divided until it is opened. Dissect and examine the retroperitoneal lymph nodes. Open the aorta from the iliac arteries as far cephalad as the arch. Examine the azygos vein and the thoracic duct. Within the aorta note the size and character of the orifices of the major branches, particularly the renal arteries.

Adrenals. From the region of the angle formed by the diaphragm, the aorta, and the kidneys, dissect and remove the adrenal glands. Free them of all extraneous tissue and examine the cut section by multiple sagittal cuts. Place all or a part in 10 per cent formalin.

Divide the aorta at the level of the diaphragm. Free the kidneys and ureters from the surrounding tissue and separate the aorta from the root of the mesentery by sharp dissection, noting the size and the thickness of the wall of all divided vessels. Reflect the aorta, renal arteries, and kidneys downward, following

VI. THE TECHNIQUE OF THE AUTOPSY

the path of the ureters, until the only structure connecting the pelvic organs with the remainder of the abdominal organs is the sigmoid colon. Divide the sigmoid just above the rectosigmoidal junction. There is thus secured one specimen containing all of the organs of the genito-urinary tract. It should be further dissected as follows:

Kidneys. The kidney is freed of surrounding tissue and grasped in the left hand, with the lateral convexity upward. With a large knife the kidney is accurately divided into an anterior and a posterior half, cutting through the entire substance of the kidney parenchyma, leaving only the soft tissues of the pelvis to hold the two halves together (Figure 13). With a scissors the pelvis and the ureter are opened completely. The renal artery and the renal vein are opened from the orifice well into the region of the pelvis. The kidney may now be separated by division of the renal artery and vein and the ureter. The weight and size should be recorded. The capsule is stripped, exposing the surface of the parenchyma. For each kidney remove a block of tissue 3 to 5 mm. in thickness, including cortex, medulla, and pelvic mucous membrane, and place in fixative. Measure the thickness of the cortex and the thickness of the entire renal substance.

The bladder. The bladder is opened by a vertical incision on the anterior surface extending from the fundus to within a few millimeters of the internal urethral orifice. As the bladder is opened note the amount and physical characteristics of the contents. Save some in a clean glass vessel if indicated. The cavity is inverted, and the mucosa and wall carefully inspected. Select a block to include all layers of the wall for fixation.

Prostate. The prostate is examined by multiple coronal sections cut from the anterior surface, 5 to 6 millimeters apart, extending from the base of the bladder to the apex of the prostate. Note the size of the urethra and inspect the mucosa. Place one of these complete coronal blocks in fixative.

Rectum. The rectum is opened with an enterotome along the posterior midline. The fecal material is removed and the mucosa and wall examined. The rectum is then dissected from the posterior wall of the prostate and bladder, thus exposing the seminal vesicles.

Seminal vesicles. Multiple longitudinal incisions, 2 to 3 mm. apart, along the long axis serve to expose the wall and the lumens of the vesicles. The thickness, the character of the wall, and the physical characteristics of the contained fluid should be noted.

Pages 27-730 missing

VI. THE TECHNIQUE OF THE AUTOPSY

After examination of the scalp an intermastoidal incision, extending over the vertex of the skull, should be made with a scalpel. The blade of the scalpel is best turned outward in order to prevent cutting of the hair (Figure 14). If an individual is bald this incision should be placed as far posteriorly as possible at the posterior extremity of the parietal bosses. This incision is carried through the entire thickness of the scalp, but not through the temporal muscle. Reflect the scalp both anteriorly and posteriorly, taking care that the skin of the forehead is not perforated by the knife, and removing all tissue cleanly from the bone except for the temporal muscle and fascia. The reflection anteriorly should be carried to a point $1\frac{1}{2}$ cm. above the supraorbital ridge. With a sharp instrument plan the saw-cut in the anterior half of the cranial bones. This should extend from the deepest point of one temporal fossa directly behind the external auditory canal, over the frontal bone, running parallel to the supraorbital ridges, and not less than 4 cm. superior to them, to a corresponding point in the opposite temporal fossa (Figure 15). With a scalpel cut the temporal muscle and fascia on each side along this line, and with a blunt instrument separate the tissues from the squamous portion of the temporal bone along this incision. The saw-cut in the posterior half of the cranial bones should be composed of two parts, meeting at an angle in the midline. On each side the cut should extend from the lower end of the anterior cut, backward and upward over the occipital bone to the midline at about the level of the superior nuchal line. The angle formed by the anterior and posterior incisions should be from 100 to 120 degrees, and that between the posterior incisions at the superior nuchal line from 120 to 150 degrees. With a fine-tooth saw, cut through all of the outer table and the greater part of the inner table. With a chisel and hammer break the few remaining parts of the inner table. The fracture line so produced will serve to anchor the skull cap more securely for restoration of the body. Remove the calvarium, separating it from the underlying dura by blunt dissection. With a scalpel open the superior longitudinal sinus, and then with a scissors cut the dura along the saw-cuts in the bone. Reflect the dura toward the midline, and with a scalpel or by blunt dissection divide the cerebral veins on each side. Note the size and appearance of the arachnoidal granulations in this region. With a scissors cut the anterior attachment of the dura within the great cerebral fissure and pull the falx cerebri posteriorly, exposing the full surface of both cerebral hemispheres. With the left hand lift the frontal lobes of each cerebral hemisphere from the floor of the anterior cranial fossa, and with a blunt instrument free the attachments of the olfactory nerves to the cribriform plate of the ethmoid bone. On further retraction of the

VI. THE TECHNIQUE OF THE AUTOPSY

brain, cut the optic nerve, the carotid arteries (leaving not less than 4 mm. within the cranial cavity for ligation), the stalk of the hypophysis, and the third, fourth, fifth, sixth and seventh nerves on each side. As these structures are successively cut, take great care to support the brain in the left hand. With a knife cut the tentorium cerebelli along its attachment to the superior border of the petrous temporal bone on each side. The posterior cranial fossa is thus exposed. Divide the remaining cranial nerves on each side and cut across the vertebral artery and the lower end of the medulla as far caudally as possible. Now support the brain in the right hand and with the fingers of the left reach into the posterior cranial fossa and lift the cerebellum, at the same time rotating the cerebral hemispheres posteriorly and upward. The brain should slip easily from the cranial cavity. Examine the external appearance of the brain, cut through the corpus callosum on each side to expose the lateral ventricles, and then suspend in 10 percent formalin by placing a string beneath the basilar artery and tying it to each side of the edge of the container. In all suspected or known neuropathological conditions the intact brain should be sent to the histopathological center for further study. The dural sinuses, notably the superior petrosal, the inferior petrosal, the sagittal, and the sigmoidal, should be opened. For demonstration of fractures in the base of the skull the dura should be stripped from the bone; this is best done by attaching a hemostat to the edge of the cut dura so as to get traction. Remove the gasserian ganglia from the apex of the petrous temporal bone and fix in 10 percent formalin. Sodium chloride, in a concentration of 8 percent will prevent the brain from sinking in the fixing solution.

If necessary for early gross diagnosis, the brain may be sectioned after five days' fixation and then sent to the central laboratory. Place the brain on a dissecting board with the ventral surface upward. With an amputating knife or a brain knife, remove the brain stem and cerebellum by a section through the interbrain at the level of the substantia nigra. This exposes the veins of Galen and the pineal body. Place the pineal in fixative. Parallel coronal sections are then made through the cerebral hemispheres starting at the frontal poles and continuing to the occipital (Figure 16). The sections should not be more than 1 cm. apart. The vermis of the cerebellum is split sagittally and the two halves of the cerebellum removed from the pons by division of the cerebellar peduncles. Each half of the cerebellum is then sectioned into thin blocks in a plane parallel to the original section of the vermis. The interbrain, pons, and medulla are cut in parallel

THE AUTOPTSY

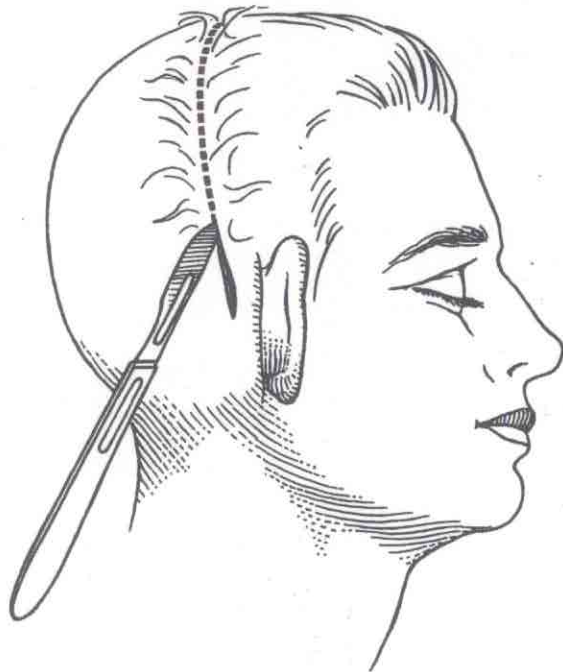


Figure 14

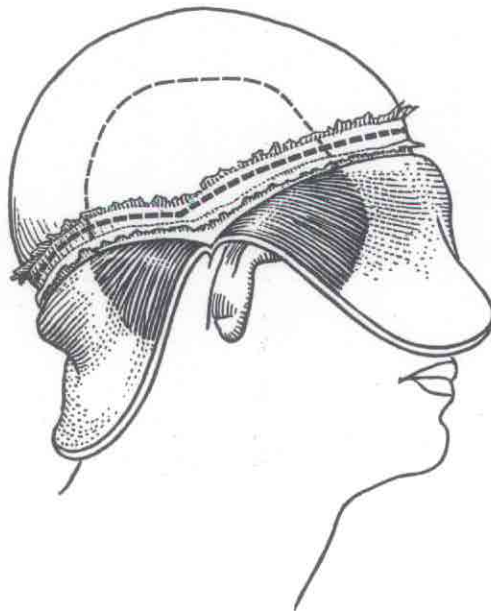


Figure 15

THE AUTOPSY

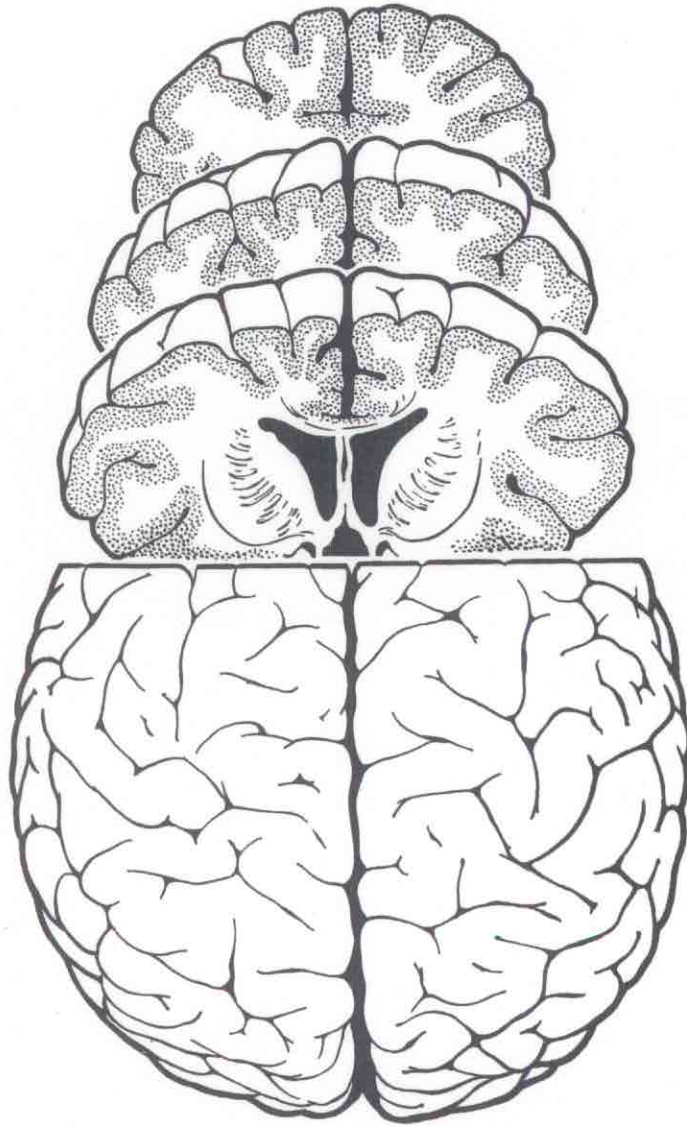


Figure 16

VI. THE TECHNIQUE OF THE AUTOPSY

cross-sections at 5 to 7 mm. intervals.

If conditions require section in the unfixed state the brain should be cut as outlined above. The procedure is greatly expedited if each freshly sectioned surface is pressed firmly against a piece of glass before the next cut is made. Stickiness of the knife as well as of the tissues can be prevented by flooding the knife with 95 percent alcohol.

Pituitary. The pituitary may be removed from the sella by careful sharp dissection, or better after the posterior clinoid processes have been broken through with a chisel. After section in a sagittal plane, place the entire gland in fixative.

Temporal Bones. Each temporal bone should be removed in one piece by means of a motor-driven, small, circular saw or a Stryker cast cutter. In the event that these instruments are not available, a thin-bladed chisel and a light hammer should be used. If too large a chisel is employed, or if the blows struck are too heavy, the bone is apt to fracture or splinter and injure adjacent structures. All cuts should be made with short, light blows. The dura should be left attached to the bone. It goes without saying that great care should be exercised not to remove the temporal bone in such a manner that the head will collapse.

The first cut is parallel to the lateral surface of the skull, just lateral to the eminence for the superior semi-circular canal, (Figure 17). In the average individual this cut will divide the external auditory meatus just lateral to the tympanic membrane. The second cut is roughly parallel to the first, near the apex of the bone where it borders the carotid canal. The third cut divides the petrous portion of the temporal bone along the suture lines which unites it with the great wing of the sphenoid and the squamous portion of the temporal bone. The fourth cut is parallel to the base of the skull and cuts the bone along the line of the inferior petrosal sinus and the more medial part of the transverse sinus. The bone then is secured with a strong forceps, and connective tissue or other attachments severed.

Eyes. Either the entire eye or the posterior half of the eyeball may be easily removed from within the cranial cavity. With a chisel remove the superior bony roof of the orbit. Expose the optic nerve and the eyeball. If the entire eye is removed, care should be taken to separate accurately at the line of attachment of the sclera to the lid, without perforation of the skin of the lid. Place in fixative immediately. For restoration of the external

VI. THE TECHNIQUE OF THE AUTOPSY

appearance of the body, place a piece of black paper immediately behind the eyelids, and fill the orbital cavity with plaster. The embalmer should be cautioned to stitch the eyelids shut with a fine suture in the mucous membrane at the inside of the lid. In most instances it is necessary to remove only the posterior half of the eyeball.

Paranasal sinuses. With a chisel the bony plates separating the cranial cavity from the frontal, the ethmoidal, and the sphenoidal sinuses may be removed and the mucosa and cavities of these structures examined.

Removal and Examination of the Spinal Cord and Vertebral Column

The spinal cord is best removed through a posterior midline incision, extending from the base of the head to the sacrum. The tissues are separated from each side of the spinous processes, and with a periosteal elevator or chisel the lamina over the region to be opened are exposed. With a saw held as close to the spinous processes as possible and directly perpendicular, saw through the lamina. If the outer blade of the saw is too far laterally, the saw will cut into the spinal cord when it enters the canal. If the saw is tilted in the opposite direction the canal will not be entered and the saw will continue through the bone of the pedicle of each vertebral body. A wide-edged chisel and a wooden hammer may be used in place of the saw. With a chisel remove the spinous processes and lamina, thus exposing the dura of the spinal cord. A laminectomy should not be done on the first cervical vertebra but this region tunneled, as any interference with the first cervical vertebra will destroy the rigidity of the connection between the head and the trunk. With a scalpel cut through the dura and the cord or nerves at the lowest point to be examined. With a forceps grasp the dura mater, not the cord, and by gentle traction and sharp dissection separate the dura from the anterior surfaces of the vertebral bodies and remove the spinal cord within the dura mater. With a scissors open the dura along the posterior and anterior midlines. Examine the cut surface by multiple cross-sections made with a knife wet with alcohol. For fixation suspend in a tall jar filled with 10 percent formalin.

If the vertebral column must also be removed, divide the soft tissues of the posterior abdominal wall where they attach to the lumbar vertebra, and with a rib shears cut the attachment of

THE AUTOPTSY

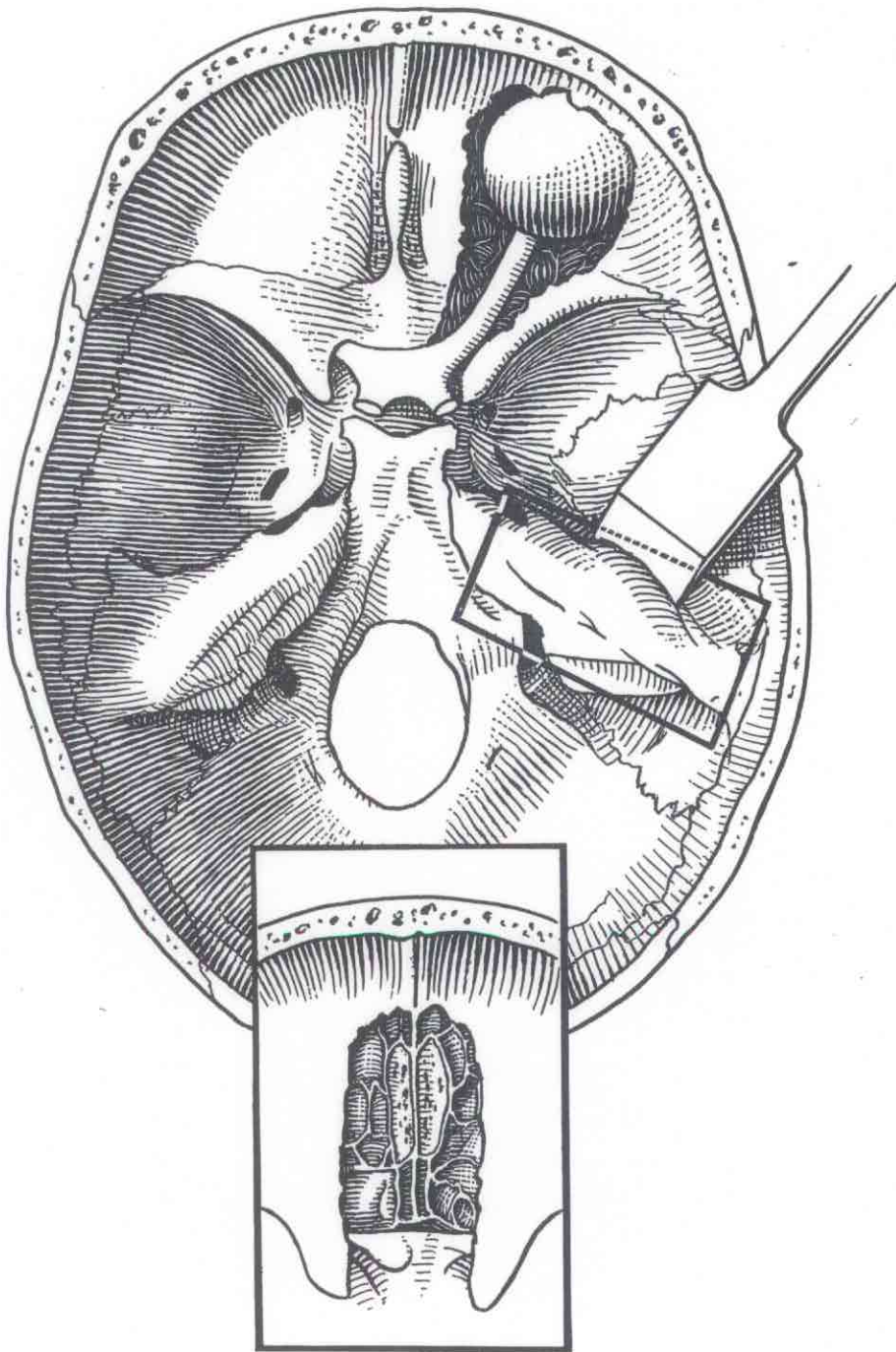


Figure 17

THE AUTOPSY

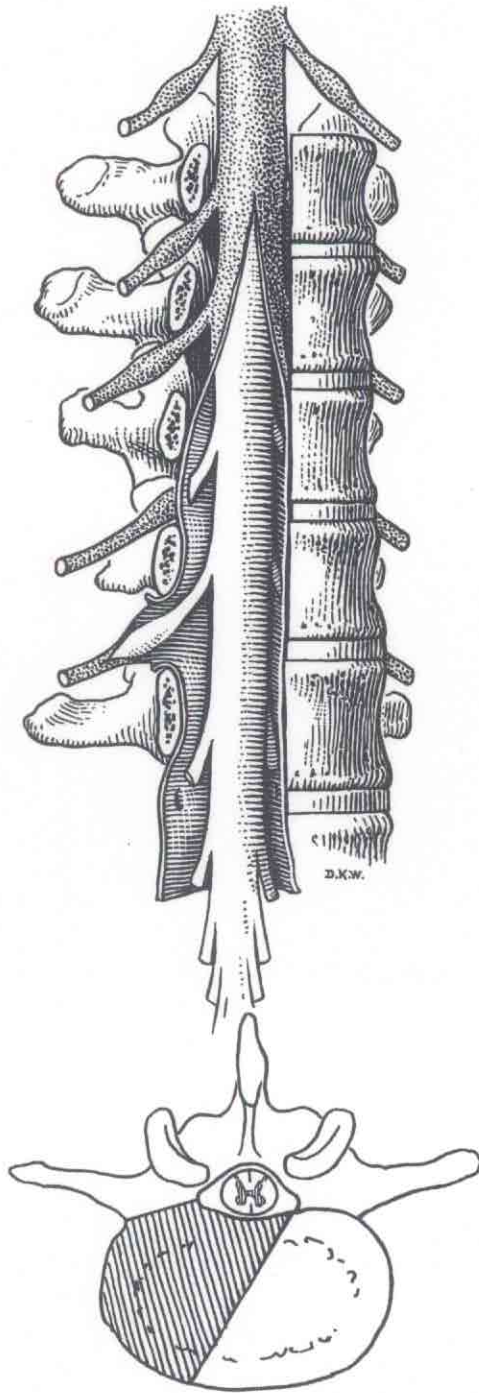


Figure 18

VI. THE TECHNIQUE OF THE AUTOPSY

each rib to the thoracic vertebra. With a heavy cartilage knife cut through the intervertebral discs at the lowest point and highest point of the selected specimen, and lift the vertebral column from the body. On the basis of the suspected pathological change, saw the vertebral column in either a frontal or a sagittal plane. A fine, soft brush with running water will be found useful to remove the bone dust from the freshly sawed surface. The rigidity of the vertebral column should be restored by use of a stick of wood and plaster of Paris.

After fixation the spinal cord should be thoroughly washed and blocks removed from at least the cervical, thoracic, and lumbar levels. These should be prepared for microscopic study as are the blocks from the brain.

Removal of the Spinal Cord by the Anterior Route: A New Postmortem Method (Kernohan)

Removal of the spinal cord and its membranes by reflecting the skin and muscles of the back, and removing the laminae and spinous processes of the vertebrae has been a laborious task, and has retarded satisfactory study of this structure and its appendages. The modification of this technic which is the subject of this note has been used in the laboratories of Pathologic Anatomy of The Mayo Clinic for eight years, and has been so satisfactory and comparatively simple that it seemed to me to be worth recording.

No elaborate equipment or instruments are necessary, and no new ones are required. A saw with a rounded end, a wooden hammer, and an all steel chisel are used. Part of the standard equipment is a large pair of Councilman's bone cutting forceps used to remove the inner and middle ears, and formerly used extensively by orthopedists.

After the organs have been removed from the thorax and abdomen, the bodies of the vertebrae are cleaned, and then cut with the saw in the direction indicated in Figure 18. The cutting should be commenced at the promontory of the sacrum and then continued upward to the fourth thoracic vertebra or even higher. The pedicles on the right are cut, either at the level of the intervertebral foramina with the chisel, or with Councilman's forceps, and leverage is obtained to remove the segment of vertebra laterally, and assists in its removal. The half body of the vertebra can be removed individually by cutting the intervertebral discs with a knife;

VI. THE TECHNIQUE OF THE AUTOPSY

this is a simple procedure, and usually advisable; it permits also examination of the cartilage of the intervertebral discs.

When the segments of vertebrae are removed, the anterior surface of the dura mater and the nerve roots (Figure 18), as well as the dorsal root ganglion and nerve trunks, are exposed. The dura mater with the spinal cord within, the nerve roots, and dorsal root ganglia can be removed intact by cutting the nerve roots of the left side, or if desired, the dorsal root ganglia on this side can be easily obtained for examination. The only objection to this method is the possibility of injuring the spinal cord with the saw, but after a little experience, this danger disappears. Another possible objection is that the cervical segments of the spinal cord are not exposed or readily obtained, but if the cervical cord is desired a thin knife can be inserted between the occipital bone and the atlas and the medulla cut across. The dura mater at its upper level of exposure is cut completely around, and with gentle traction toward the feet, the entire cord, without the dura mater and dorsal root ganglia can be obtained. The spinal cord secured in this manner is intact and satisfactory for histologic or chemical studies.

The advantages of this method compensate for any possible objections which might be made to it. Special permission to examine the spinal cord is not necessary, special equipment is not necessary, the body does not have to be turned, and there is less work for the undertakers. Sufficient strength of the vertebral column remains, but if desirable, the defect in the bones can be repaired with plaster of Paris. By this method the work can be done more easily and more quickly than by that ordinarily used. In this manner I have obtained for examination several hundred spinal cords, and Harmeier has used the method exclusively when removing the filum terminale for his study of the normal structure of this tissue. The method is particularly advantageous in obtaining the lumbar portion of the spinal cord, as well as the cauda equina. At this level, it is difficult to approach the spinal cord from the back because of the heavy muscles, the sacro-iliac joint, and the depth of the cauda equina from the surface.

Removal and Examination of Bones, Joints And Bone Marrow

After removal of the viscera from the abdomen and thorax, the lumbar vertebrae should be opened by a frontal saw-cut, separating the vertebral bodies into an anterior one-third and a posterior

VI. THE TECHNIQUE OF THE AUTOPSY

two-thirds. Place a small block in fixative. This will not destroy the rigidity of the vertebral column. The sternum and the ribs should be examined and small samples taken for histologic study. For removal of bone marrow from the long tubular bones--femur, tibia, and humerus--it is best to incise the skin in a circular direction--10 cm. in length--and separate the muscle and fascia to expose the surface of the bone. With a saw, cut about one-third of the way through the bone at two points about 2 cm. apart. With a chisel and hammer remove the cap of cortical bone. An adequate amount of bone marrow may be secured through this opening (Figure 19).

If one of the long tubular bones is to be removed, a longitudinal incision over the entire length of the bone must be made and the joint at each end disarticulated. With the femur, disarticulation of the head within the acetabulum presents peculiar problems. After exposure of the region of the acetabulum and complete division of the joint capsule, the leg should be rotated outward and adducted. With this maneuver the head will roll out of the acetabulum and the femur may then be easily removed. Exposure of the knee joint is best accomplished through a U-shaped incision, the base of the U passing through the skin directly over the patellar tendon when the leg is in an extended position. The incision is extended through the patellar tendon and the patella, rectus femoris muscle and surrounding tissues elevated for a distance of some 10 to 15 cm. (Figure 20). The lower leg is now flexed on the thigh; the articular surfaces of both the femur and the tibia will be brought into full view and may be examined. If any of the long bones are completely removed the rigidity of the body must be restored by the judicious use of wood and plaster. If an entire bone is to be removed, have this part of the body embalmed before the circulation is interrupted by the dissection.

In suspected lead poisoning save an adequate sample of bone for chemical examination.

Examination of Peripheral Nerves and Neuromuscular Apparatus

Whenever indicated the peripheral nerves and the muscles supplied by them should be removed by properly placed longitudinal incisions through the skin and subcutaneous tissues. Study of these structures is of importance in all injuries to nerves and to the central nervous system. Blocks of tissue should be removed from points above and below the lesions and fixed in 10

VI. THE TECHNIQUE OF THE AUTOPSY

percent formalin. Each block should be placed in a separate bottle of fixative with an identifying label.

Examination of the Tissues of the Arm and Hand

A cardinal principle in all autopsies is that the skin of the face, the neck, the arms, and the hands may not be incised. If the structures within the arm or hand must be examined, it is best to make a complete circular incision through the skin of the upper arm, and invert and roll the skin downward until the region to be examined is reached (Figure 21).

Examination of Tissues of the Face

None but the most expert should attempt examination of the underlying tissues of the face. The procedure is based upon the following steps: preparation of a death mask, thorough embalming and hardening of the skin and subcutaneous tissues, dissection of these tissues from the underlying bone, and final restoration by placing the embalmed skin in the death mask and recasting the facial features with plaster of Paris behind the skin.

Examination of the Female Genitalia

In autopsies of women the internal female genitalia should be removed with the bladder and the rectum. After section and examination of the bladder remove it from the anterior surface of the vagina. Open the vagina with a scissors or knife along the anterior midline. With a sharp knife open the uterus along the anterior midline from the cervix to the extreme tip of the fundus. The cornua may be opened by incisions in the anterior wall at right angles to the primary incision. The thickness of the endometrium and of the myometrium should be measured, and the greatest length, greatest breadth, and greatest depth of the uterus recorded. The uterine tubes should be examined by multiple cross-sections. The ovary is opened by a single incision exposing the largest surface area. The veins and arteries in the broad ligament should be opened by cross-section or longitudinally.

The breast is most conveniently examined after reflection of the skin and subcutaneous tissues over the thorax. Multiple sections extending to within a few millimeters of the skin will expose the mammary tissues. In special cases the nipple should be removed.

THE AUTOPSY

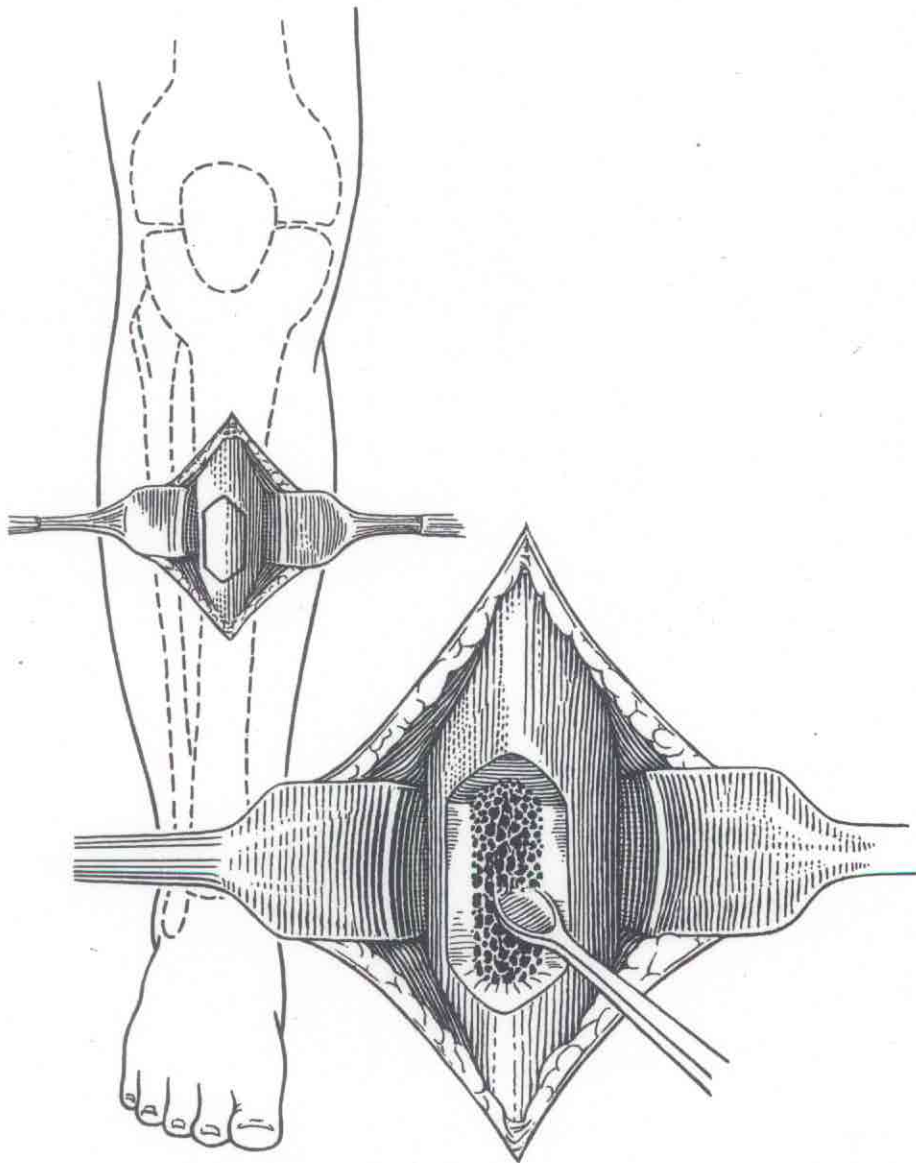


Figure 19

THE AUTOPSY

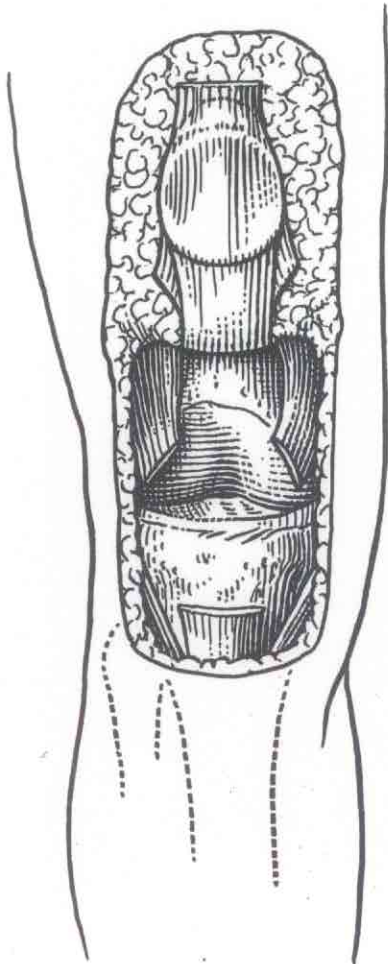


Figure 20

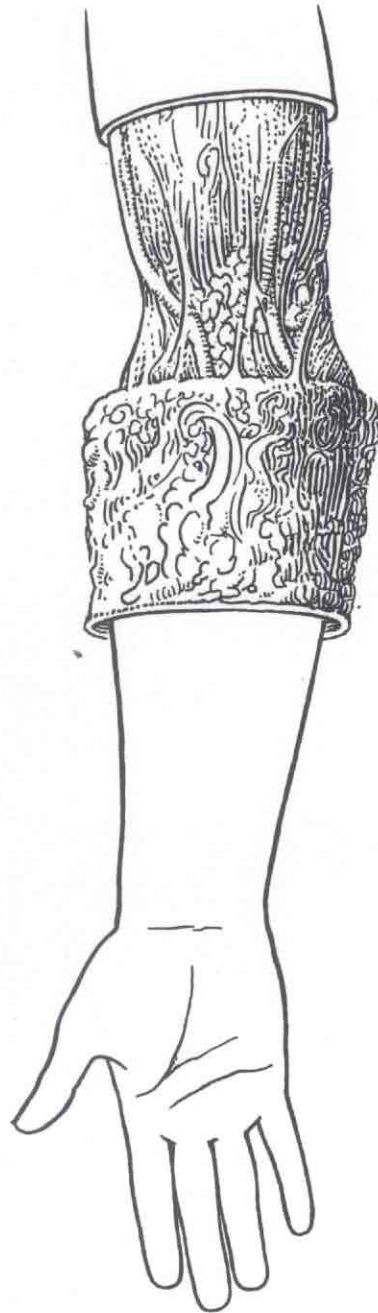


Figure 21

VI. THE TECHNIQUE OF THE AUTOPSY

Blocks of the vagina, cervix, uterus, tube, ovary, and breast should be fixed for microscopic study.

VII. NORMAL WEIGHTS AND MEASUREMENTS

The size and weight of each of the organs varies according to age, stature, and body weight, but the following figures represent the range of normal for adult men between 20 and 30 years of age.

| | |
|-----------------------------------|---------------|
| Brain | |
| Weight | 1250-1400 gm. |
| Sagittal diameter..... | 16-17 cm. |
| Vertical diameter..... | 12-13 cm. |
| Spinal Cord | |
| Length..... | 45 cm. |
| Weight..... | 27-28 gm. |
| Frontal diameters | |
| Cervical..... | 13-14 mm. |
| Thoracic..... | 10 mm. |
| Lumbar..... | 12 mm. |
| Sagittal diameters | |
| Cervical..... | 9 mm. |
| Thoracic..... | 8 mm. |
| Lumbar..... | 9 mm. |
| Pituitary | |
| Weight..... | 610 mg. |
| Pineal | |
| Weight..... | 140-170 gm. |
| Parotid Gland | |
| Weight..... | About 30 gm. |
| Submaxillary Gland | |
| Weight..... | About 17 gm. |
| Thymus | |
| Weight..... | 19-23 gm. |
| Heart | |
| Weight..... | 275-325 gm. |
| Thickness of auricles..... | 1-2 mm. |
| Thickness of left ventricle..... | 8-10 mm. |
| Thickness of right ventricle..... | 2-3 mm. |
| Circumference of mitral ring..... | 10 cm. |
| Circumference of aortic ring..... | 7.5 cm. |

VII. NORMAL WEIGHTS AND MEASUREMENTS

| | |
|---|-----------------------------|
| Circumference of pulmonic ring..... | 8.5 cm. |
| Circumference of tricuspid ring..... | 12 cm. |
| Pulmonary Artery | |
| Circumference..... | 8 cm. |
| Aorta | |
| Circumference of ascending aorta..... | 7.5 cm. |
| Circumference of descending aorta..... | 4.5-6 cm. |
| Circumference of abdominal aorta..... | 3.5-4.5 cm. |
| Thyroid: The size and weight of the thyroid depends upon geographical location, but the normal thyroid should not exceed 40 gm. | |
| Measurements..... | 1.5-2.5 x 3-4 x 4-7 cm. |
| Parathyroids | |
| Weight..... | 115-130 gm. for 4 |
| Lungs | |
| Weight of right lung..... | 375-550 gm. |
| Weight of left lung..... | 325-450 gm. |
| Liver | |
| Weight..... | 1500-1700 gm. |
| Measurements..... | 25-30 x 19-21 x 6-9 cm. |
| Spleen | |
| Weight..... | 125-175 gm. |
| Measurements..... | 3-4 x 8-9 x 12-14 cm. |
| Pancreas | |
| Weight..... | 90-120 gm. |
| Measurements..... | 3.8 x 4.5 x 23 cm. |
| Kidneys | |
| Weight of each..... | 140-160 gm. |
| Measurements..... | 3-4 x 5-6 x 11-12 cm. |
| Thickness of renal substance..... | 20-23 mm. |
| Thickness of cortex..... | 6-7 mm. |
| Volume of renal pelvis..... | 10-15 cc. |
| Seminal Vesicles | |
| Measurements..... | 0.9 x 1.6-1.8 x 4.1-4.5 cm. |
| Testis and Epididymis | |
| Weight together..... | 17-27 gm. |
| Measurements of testis..... | 2-2.7 x 2.5-3.5 x 4-5 cm. |
| Prostate | |
| Weight..... | 14-16 gm. |
| Measurements..... | 2.7 x 3.6 x 1.9 cm. |
| Adrenals | |
| Weight of each..... | 5.7 gm. |
| Measurements..... | 0.5 x 2.5-3.5 x 4-5 cm. |

VII. NORMAL WEIGHTS AND MEASUREMENTS

Gastrointestinal Tract

Length of esophagus, cricoid to cardia..... 25 cm.
Vertical length of stomach.....25-30 cm.
Length of duodenum..... 30 cm.
Length of small intestine.....550-660 cm.
Length of large intestine.....150-170 cm.

Uterus

Weight in nullipara..... 40-60 gm.
Weight after a pregnancy.....75-125 gm.

Ovaries

Weight of one.....8-12 gm.

VIII. THE DESCRIPTIVE PROTOCOL

Describe fully the body as a whole and each organ, being as objective as possible. Avoid the use of diagnostic terms so that the protocol will be objective and may be interpreted by others who may later review it. Include size (weights and measurements), shape, color, consistence, and general description of capsule and cut surfaces of each organ. All departures from normal position and relation and all pathological lesions should be fully described. Note that the kidney is the only organ about which useful information is to be gained by stripping the capsule.

To facilitate coding, indexing, etc. at the Armed Forces Institute of Pathology, prepare the front page as follows, typing only the underlined captions.

Name of Hospital: IAB. NO.

NAME: STATUS: ENTERED SERVICE:

AGE: SEX: RACE: NATIVITY:

ADMITTED: date

DIED: date, hour, place

AUTOPSIED: date, hour, place

VIII. THE DESCRIPTIVE PROTOCOL

CLINICAL DIAGNOSES

- 1.
2. etc.

PATHOLOGIC DIAGNOSES

(Capitalize the significant ones)

CARDIOVASCULAR SYSTEM
RESPIRATORY SYSTEM
SPLEEN AND HEMATOPOIETIC TISSUES:
GASTROINTESTINAL SYSTEM:
LIVER:
PANCREAS:
GENITOURINARY SYSTEM:
CENTRAL NERVOUS SYSTEM:
ENDOCRINE GLANDS:
BONES AND JOINTS:
MISCELLANEOUS:

CLINICAL ABSTRACT

DATE OF ADMISSION
HABITS: Alcohol, tobacco, narcotics, etc.
FAMILY HISTORY: List all information bearing on deaths, illnesses and hereditary tendencies.
PREVIOUS PERSONAL HISTORY: Include all illnesses, operations, wounds, fractures, venereal infections. List all service in Army or Navy and duty in tropics. DID HE OR DID HE NOT HAVE JAUNDICE WITHIN THE PAST YEAR?
PRESENT ILLNESS: Onset of present illness with chronologic abstract of illness.
PHYSICAL EXAMINATION: Weight, height, temperature, pulse, respiration and blood pressure. List all positive findings by systems.
LABORATORY AND X-RAY FINDINGS:
PROGRESS NOTES: To include abstract of patient's illness and hospitalization and major therapeutic measures.
DATE AND HOUR OF DEATH:
(General Note: Describe fully the body as a whole and each organ, being as objective as possible and avoiding the use of pathologic terms and diagnoses so that your protocol will have an intelligible meaning to others who may later review it. Include size, weight, shape, colors, consistency and general description of capsule, (do not try to strip capsule of any organ but kidney!) and cut surface

VIII. THE DESCRIPTIVE PROTOCOL

as it pertains to each organ. List all departures from normal position and relationship. Describe fully all pathologic lesions that are recognized.

(EXAMINE EVERY ORGAN IN the body and COLLECT representative SECTIONS of EACH for future histologic studies and include muscle, bone and marrow.)

GENERAL: Approximate height, weight, age, color, sex, condition as to development and nutrition, degree of rigidity, character and distribution of lividity and degree of post mortem decomposition. Detailed description of exterior, beginning with hair and going to feet to include marks of identification of abdomen, superficial vessels and lymph nodes, external genitalia.

PRIMARY INCISION: Subcutaneous fat, muscles, peritoneum, omentum, intra-abdominal fat, position and relations of abdominal viscera, adhesions, fluid, intra-abdominal and mesenteric lymph nodes; height of diaphragm; pleura fluid; adhesions; pericardium; thymus; mediastinum; thyroid; parathyroids; larynx, pharyngeal and mouth structures.

LUNGS: Weight, relative size, consistence, pleura; cut surface of each lobe; bronchi, hilum, lymph nodes.

HEART: Weight, relative size; epicardium, musculature, valve leaflets, endocardium, coronary arteries; measurements of valve orifices and thickness of ventricular walls.

AORTA AND VESSELS:

SPLEEN: Weight, size, consistence, capsule; cut surface, color, dry or moist, markings; does pulp scrape?

LIVER: Weight, surface; section - consistence, color, markings. Gallbladder and ducts.

PANCREAS: Weight, consistence, cut surface.

ADRENALS: Size, cut surface.

GASTROINTESTINAL TRACT: Esophagus, stomach, intestines, appendix.

GENITOURINARY TRACT: Kidney, weight, size and consistency; capsule strips; subcapsular surface, cut surface; cortical markings; width of cortex and cut surface; pelvis, pelvic fat, ureter, large vessels.

BLADDER: Distended? Character of contents; mucosa; wall.

SEMINAL VESICLES:

PROSTATE:

or UTERUS & ADNEXA:

TESTICLES:

HEAD: Scalp, calvarium, dura, blood sinuses of dura; leptomeninges, fluid and exudate; cerebral vessels.

BRAIN: Convolutions and sulci; consistency; lateral ventricles.

CORD: Dura; exudate; leptomeninges; cut surface at critical levels.

VIII. THE DESCRIPTIVE PROTOCOL

TEMPORAL BONE:

SINUSES OF SKULL:

EAR:

EYES:

BONE MARROW: Ribs, vertebrae, shaft of femur.

BONES AND JOINTS:

MUSCLES:

BACTERIOLOGIC EXAMINATION:

CHEMICAL EXAMINATION:

NOTE: Give your opinions and interpretations, especially as to pathogenesis.

Prosector's Name

IX. SELECTION AND FIXATION OF BLOCKS FOR MICROSCOPIC STUDY

The selection of the blocks of tissue to be used for microscopic study requires as much or more judgment as the examination of the gross specimens. Tissues selected at random serves little useful purpose in amplifying the findings of the gross examination. The following general considerations should be borne in mind in the selection and fixation of blocks of tissue:

1. Care should be taken that the tissue is not crushed or otherwise injured before it is selected and cut from the organ. The mucosa of the intestine should not be touched or washed before the block is taken. Contact of the tissues with water should be avoided before fixation.
2. Use adequate amounts of fixative. Twenty volumes of fluid for each one volume of tissue are recommended.
3. If there is a focal lesion the block should be taken to include the junction of the lesion with the normal tissue.
4. The block should be sufficiently thin to allow rapid penetration of the fixative--not over 5 mm. in thickness.
5. Ample tissues should be taken for microscopic study, and more than one block from significant areas. The blocks should be sufficiently large for orientation and identification of the parts of the organ--not less than 1.5 to 3 cm. square.
6. Sections in each organ should be taken through the critical parts of that organ; for example, the blocks from the kidney

IX. SELECTION AND FIXATION OF BLOCKS FOR
MICROSCOPIC STUDY

should include cortex, medulla, and pelvis; the blocks from the intestine should include a lymphoid follicle; the blocks from the heart should include atrium, valvular ring, valve, and ventricle.

7. In organs covered by a serous membrane at least one block should include the serosa.

8. If there is any question of identification (sections from the base and tip of the appendix, from each of paired organs, or from the various lobes of the lung), each block should be placed in a separate bottle or out in distinctive shapes, in order that absolute identification may be made at a later date.

9. Make certain that the tissue is not bent, twisted, or distorted after it is placed in the fixative. Smaller pieces of tissue may be placed on a paper towel and then carefully floated into the fixative. There is sufficient protein on the surface of most organs to coagulate and hold the tissue to the paper. With larger blocks it is desirable to enclose them between two pieces of copper gauze in order to prevent distortion.

10. Over-fixation is as undesirable as under-fixation. Tissue should never be fixed in Zenker's fluid for longer than 24 hours, and most tissue is adequately and sufficiently fixed at the end of 12 hours.

11. Subsequent treatment of tissue blocks. After fixation in 10 percent formalin for 24 to 48 hours, wash briefly in water and place again in a new volume of 10 percent formalin. After fixation in Zenker's fluid, which should be limited strictly to from 12 to 24 hours, wash for 24 hours in running water and place in 70 percent alcohol. If 10 percent glacial acetic acid has been added for decalcification, fix for 4 to 5 days, wash in running water for 24 hours and then place in 70 percent alcohol. After fixation in Bouin's fluid for 24 to 48 hours, place in 70 percent alcohol and change the alcohol every 24 hours until there is no further leaching of the picric acid into the alcohol. After fixation in Regaud's fluid, the tissue should be washed for 24 hours in running water and placed in 70 percent alcohol.

See Section XVII for instructions on shipment of specimens.

X. THE SELECTION AND FIXATION OF ORGANS
FOR PRESERVATION AS MUSEUM
SPECIMENS

In the selection and preparation of a specimen for display in the museum, the prosector should bear in mind that the tissue is to be viewed by others who do not have the advantage of inspection of the entire organ and other organs of the case.

A. General Principles

The following general principles are suggested as a guide:

1. The specimen should have one flat surface, cut with one stroke of the knife.
2. The specimen should not be thicker than 2 to 3 cm., as fixative will not penetrate beyond a few centimeters. With large organs fix half of the organ and then cut the slab to include the original cut surface.
3. With large solid viscera two parallel surfaces should be prepared, each by a single stroke of the knife.
4. Cut the organ in such a way that orientation is possible.
5. Do not cut a new surface after fixation except as mentioned in 2 above, as the characteristic contour may be lost.
6. Take care that the specimen is placed in the fixative without distortion.
7. Do not cover specimens with paper towels, because these will leave an impression of the fibers of the towel. If the tissue floats, cover it with a fine layer of absorbent cotton, the fibers of which by capillary attraction will pull fluid onto the exposed surface. Cover the container tightly.
8. With opened hollow viscera pin the tissue on a board, but not with such tension as to produce distortion.
9. See that the specimen does not stick to the sides or bottom of the vessel and thus prevent entrance of the fixative on all surfaces.
10. Label each specimen. The most satisfactory method is to

X. THE SELECTION AND FIXATION OF ORGANS
FOR PRESERVATION AS MUSEUM
SPECIMENS

print the identifying number or name on linen cloth with india ink, dip the cloth in melted paraffin, and after cooling, sew the label onto the specimen.

B. Typical Specimens

Special attention should be given to the collection of specimens exemplifying wounds peculiar to military service. The following are suggested as desirable and satisfactory specimens for museum demonstration:

Lungs: The anterior or posterior half of one or both lungs, including the corresponding half of the bronchi and trachea.

Heart: The entire organ.

Liver: A slab not over 2 to 3 cm. in thickness, taken through the long axis, or one-half of the organ.

Spleen: One-half of the organ or a slab 1 to 2 cm. in thickness. In either case the specimen should be taken through the long axis.

Kidney: One entire kidney or one-half of one kidney.

Pancreas: The entire organ.

Intestine: A segment not over 30 cm. in length, including the adjacent mesentery as indicated.

Thyroid: The entire gland, preferably still attached to the trachea.

Adrenal: One entire gland.

Genital tract: The entire organ and adjacent structures, such as the testis, epididymis, and vas; or the prostate, urethra, seminal vesicles and bladder.

C. Fixation of Museum Specimens

Formaldehyde brings about conversion of hemoglobin to acid hematin, and thus the characteristic color of fresh tissue is lost. In the preparation of museum specimens an attempt is made to prevent the decoloration, or to restore the color by some secondary procedure. If the chemicals are available, all tissue for preservation as museum specimens should be fixed according to the Kaiserling method. Otherwise the carbon monoxide method should be employed.

The Kaiserling Method. In the Kaiserling method the tissue is fixed in a solution known as Kaiserling I, made according to the following formula:

X. THE SELECTION AND FIXATION OF ORGANS
FOR PRESERVATION AS MUSEUM
SPECIMENS

Potassium acetate..... 170 gm.
Potassium nitrate..... 90 gm.
Commercial formalin.....1600 cc.
Water.....8000 cc.

After fixation for 3 to 7 days, the specimen is thoroughly washed in running water from 12 to 24 hours and then placed in 95% ethyl alcohol, known as Kaiserling II. The alcohol converts the acid hematin formed by the acting of formaldehyde on hemoglobin into alkaline hamtin, which is redder in color and more permanent than the acid hematin. The specimens should remain in alcohol from 6 to 24 hours, until there is full development of the natural red color. If ethyl alcohol is not available, tertiary butyl alcohol may be substituted. On removal from the alcohol, wash in running water for not over 2 hours, and place in the final mounting fluid, known as Kaiserling III, and made according to the following formula:

Potassium acetate..... 1720 gm.
Glycerol..... 2000 cc.
Water.....10000 cc.

As a preservative add to the above, 20 cc. of phenol or crystals of thymol until the solution is saturated. If phenol or thymol is not available, arsenious acid 4 percent, or sodium fluoride 8 percent, may be substituted, and the potassium acetate reduced to a concentration of 2 percent. If glycerol is not available, propylene glycol is a satisfactory substitute.

The carbon monoxide method. The specimens are fixed for some 3 to 7 days in the following solution:

Commercial formalin..... 100 cc.
Sodium chloride.....1.08 gm.
Sodium bicarbonate..... 1 gm.
Water.....1900 cc.

After thorough fixation, the specimen, with an ample quantity of fixative, is placed in a closed vessel through which illuminating gas may be bubbled. In the original fixation the formaldehyde converted a part of the hemoglobin to acid hematin. The illuminating gas converts the remaining hemoglobin to bright red carbon monoxide hemoglobin. The gas should be bubbled through the

X. THE SELECTION AND FIXATION OF ORGANS
FOR PRESERVATION AS MUSEUM
SPECIMENS

specimen for 15 minutes each day until a satisfactory color is obtained. Care should be taken to see that the personnel in the laboratory are not exposed to the escaping illuminating gas. The specimen is then transferred without washing to the following preserving fluid:

| | |
|----------------------|---------|
| Sugar..... | 40 gm. |
| Chloral hydrate..... | 2 gm. |
| Water..... | 100 cc. |

If sugar is not obtainable, Kaiserling III with glycerol or propylene glycol may be substituted.

When a museum specimen is sent to a central museum, make a note on the jar and in the protocol of the exact procedure used for fixation, restoration of color, and final preservation.

For the smaller laboratories it will be found desirable to ship the specimens to the central museum after primary fixation. Color restoration will then be carried out at the central museum.

XI. BACTERIOLOGICAL EXAMINATION

A detailed etiological study of the tissues at autopsy is as important as the morphological study and may yield the only positive proof of the exact nature of a pathological process. The pathologist is charged with the responsibility for the collection of the material for culture and the proper disposal of the primary cultures. If a bacteriologist is available he should collaborate with the pathologist in the selection and collection of cultures.

What To Culture

It is well to prepare cultures of the heart's blood in all cases under aerobic and anaerobic conditions on both solid and liquid media. From other tissues prepare cultures if the gross appearance of the lesions indicates a bacterial etiology. If any of the sulfonamide drugs have been administered, para-aminobenzoic acid may be added to the media. If para-aminobenzoic acid is not available, hold the cultures for at least a week before reporting them as sterile.

XI. BACTERIOLOGICAL EXAMINATION

How to Secure Cultures

During the course of an autopsy under usual conditions there is gross contamination of the surface of the organs and precaution must be taken to destroy these contaminating bacteria and secure the culture from the depth of the tissue only. A spatula should be heated over a bunsen burner until it is red hot, and applied to the surface of the tissue from which the culture is to be taken. Hold the spatula on the area until the tissue is seared and thoroughly dry. Take care that the area is not subsequently contaminated by contact with surrounding tissue and fluids before the culture is taken.

There are three distinct techniques for securing a culture:

Heart's blood

Plunge a pipette (glass tube drawn to a point and sterilized) or a sterile hypodermic needle (18 to 20 gauge, 3 in.) attached to a 20 cc. syringe through the seared area on the wall of the atrium or ventricle, and draw up the blood by suction.

Solid viscera

With a sterile, sharp instrument break the surface in the seared, dry area and plunge a swab, the end of which is lightly covered with cotton, into the substance of the organ. Withdraw and replace in the sterile test tube from which it was taken. The portion of the swab held by the fingers must not enter the tube. Make certain that there is a small amount of sterile broth in this test tube in contact with the swab; otherwise the culture will dry out within a short time and be worthless. If actual tissue is desired, remove a block about 1 cubic cm. with sterile forceps and scissors from the seared area. Grind in a mortar with sterile broth and inoculate the suspension of fluid and fragments of tissue.

Leptomeninges

If care has been used in the removal of the calvarium, the dura may be reflected over the cerebral hemispheres and cultures taken from the leptomeninges with a swab or pipette without searing of the surface. Otherwise the leptomeninges must be carefully dried

XI. BACTERIOLOGICAL EXAMINATION

with the heated spatula. Under these conditions the bacteria immediately beneath the seared area may be killed by the heat and the swab or pipette should be directed through the subarachnoidal space into an adjacent unheated area.

Special Cultures

Many bacteria grow poorly or not at all on routine culture media and the bacteriologist should be given full information concerning the exact nature of the disease and the character of the pathologic lesions, in order that he may do intelligent and accurate work. The more important diseases requiring special conditions for cultivation and isolation of the bacterium are tuberculosis, typhoid and paratyphoid, dysentery, tularemia, brucellosis, lesions caused by the influenzal bacillus and gonococcus, pertussis and all the fungal diseases. For the preservation of material from spirochetal diseases it is recommended that blood or tissue fluid be drawn into capillary tubes, 8 to 10 cm. in length. The ends of these tubes are sealed in a flame by melting the glass. The spirochete of syphilis may remain active for as long as 48 hours under these conditions.

Smears

Direct examination of stained smears from bacterial infections may yield valuable information. These smears should be prepared in the usual way and stained with methylene blue and Gram's stain. In tuberculosis the smears should be stained for acid-fast bacilli. In many protozoal diseases thick films of blood or tissue fluid should be prepared. Touch a clean slide to a drop of blood or tissue pulp and allow it to spread over an area about 1 cm. in diameter. Dry at 37 degrees in a dust-free atmosphere in a horizontal position. After 2 hours immerse for 5 to 10 minutes in a mixture of 2 percent glacial acetic acid, 4 parts, and 2 percent tartaric acid, 1 part. Remove, drain, and fix with absolute alcohol for 2 to 5 minutes.

Disposal of Cultures

In all hospitals where a skilled bacteriologist is not a member of the staff of the laboratory, the material collected at the

XI. BACTERIOLOGICAL EXAMINATION

autopsy should be sent immediately to the nearest bacteriological laboratory. With each culture there should be a short note containing the pertinent information that will serve as a guide in the selection of culture media and conditions of incubation. In smaller laboratories the pathologist or laboratory officer may attempt to carry out the simpler isolations and identifications, but in all important and doubtful cases assistance should be sought from the nearest laboratory equipped for bacteriological examinations. If the pathologist or clinician knows that a patient with an interesting or unusual bacterial disease is on the wards of the hospital, he should consult with the nearest bacteriologist in order to anticipate what will be required to establish the diagnosis. If no facilities for bacteriological studies are available, the blood and tissues collected at autopsy should be placed in sterile vessels, frozen with dry ice, and shipped to the nearest bacteriological laboratory. Full data on the case should be sent with the specimens.

Specific directions will be found in the following tables for the material to be collected and the mode of handling for the more important infectious diseases.

TABLE OUTLINING COLLECTION OF MATERIAL FOR STUDY OF
SPECIFIC INFECTIONS

| <u>Disease</u> | <u>Material desired</u> | <u>Mode of handling</u> | <u>Serum</u> |
|--------------------|--------------------------|-------------------------------------|--------------|
| Blastomycosis | Lesion, spleen | 0-5°C. or frozen | |
| Coccidioidomycosis | Lesion, spleen | 0-5°C. or frozen | |
| Actinomycosis | Lesion, spleen | 0-5°C. or frozen | |
| Histoplasmosis | Lesion, spleen | 0-5°C. or frozen | |
| | Lesion, blood, spleen | Fixed smears | |
| Torula meningitis | Brain, spleen | 0-5°C. or frozen | |
| | Meninges | Fixed smears | |
| Tuberculosis | Lesion, spleen | 0-5°C. and glycerol or frozen | |
| Anthrax | Lesion, blood | Sterile tube | |
| | Lesion, blood | Fixed smears | |

XI. BACTERIOLOGICAL EXAMINATION

TABLE OUTLINING COLLECTION OF MATERIAL FOR STUDY OF
SPECIFIC INFECTIONS CONTINUED

| Disease | Material desired | Mode of handling | Serum |
|------------------------|---|---|-------------------|
| Tetanus | Lesion | Sterile tube | |
| Gas gangrene | Lesion | Sterile tube | |
| Botulism | Liver (for toxin) | 0-5°C. | |
| | The suspected food | Sterile container | |
| Leprosy | Lesions | 0-5°C. | |
| | Lesions, nasal mucosa | Fixed smears | |
| Colon bacillus | Pus from lesions, urine | Sterile tube | Plain or glycerin |
| Proteus bacillus | Pus from lesions, urine | Sterile tube | Plain or glycerin |
| B. enteritidis | Intestinal contents | Sterile tube and 30% glycerol | Plain or glycerin |
| Typhoid | Spleen, blood, intestinal contents, urine | Sterile tube and 30% glycerol | Plain or glycerin |
| Paratyphoid | Spleen, blood, intestinal contents, urine | Sterile tube and 30% glycerol | Plain or glycerin |
| Cholera | Intestinal contents | Sterile tube and 5% peptone water | Plain or glycerin |
| Bacillary dysentery | Intestinal contents | Sterile tube and 30% glycerol | Plain or glycerin |
| Pneumonia | Lung, blood | 0-5°C. or frozen; blood in capillary tube | Plain |
| Pneumococcus infection | Lesions | | |
| Streptococcus | Spleen, blood, lesion | Sterile tube and 30% glycerol | Plain |
| | Spleen, lesion | Fixed smears | |
| Staphylococcus | Spleen, blood lesion | 0-5°C. | Plain |
| | Lesions | Fixed smears | |

XI. BACTERIOLOGICAL EXAMINATION

TABLE OUTLINING COLLECTION OF MATERIAL FOR STUDY OF
SPECIFIC INFECTIONS CONTINUED

| Disease | Material desired | Mode of handling | Serum |
|---------------------------------|--|--|----------------------|
| Meningococcus | Brain, blood, spinal fluid, lesions | Sterile containers | Plain |
| Gonococcus | Meninges, lesions Lesions, blood Lesions | Fixed smears Frozen Fixed smears | Plain |
| Undulant fever | Lesions, blood, spleen Lesions | Sterile container Fixed smears | Plain or glycerin |
| Plague | Lesions, spleen, lung | Frozen, petro- latum or glycerol Fixed smears | Plain or glycerin |
| Tularemia | Blood, lung Lesions, spleen | Frozen or glycerol | Plain or glycerin |
| Glanders | Lesions, spleen, blood | 0-5°C. | Plain |
| Pertussis | Lung, tracheal con- tents | 0-5°C. | Plain |
| H. influenzae | Lung, tracheal con- tents | Sterile tube | Plain |
| Virus influenza | Lung Blood, serum | Frozen or glycerol Citratad; 0-5°C. | |
| Viral pneumonias | Lung Serum | Frozen glycerol 0-5°C. | 0-5°C. |
| "Q" fever | Lung, spleen | Frozen | 0-5°C. |
| Psittacosis | Lung, spleen | Frozen | |
| Typhus | Brain, spleen, blood | Best in guinea pigs, then frozen | Plain |
| Rocky Mountain spotted fever | Brain, spleen, blood | Best in guinea pigs, then frozen | Plain |
| Tsutsugamushi | Brain (?), spleen blood | Best in guinea pigs, then frozen | Plain |

XI. BACTERIOLOGICAL EXAMINATION

TABLE OUTLINING COLLECTION OF MATERIAL FOR STUDY OF
SPECIFIC INFECTIONS CONTINUED

| Disease | Material desired | Mode of handling | Serum |
|------------------------------|-------------------------------------|---|--------|
| Other typhus-like fevers | Brain, spleen, blood | Best in guinea pigs, then frozen | Plain |
| Variola | Skin lesions, brain* | Frozen, glycerol | 0-5°C. |
| Vaccinia | Blood Skin lesion, brain* | Citrated 0-5°C. Frozen, glycerol | 0-5°C. |
| Varicella | Blood Skin lesions, brain* | Citrated 0-5°C. Frozen, glycerol | 0-5°C. |
| Measles | Blood Blood, serum Brain* | Citrated 0-5°C. Citrated, 0-5°C. Frozen, glycerol | 0-5°C. |
| Mumps | Parotid, testis, brain* | Frozen, glycerol | |
| Lymphogranuloma venereum | Lesions | Mice intranasally or frozen | |
| Poliomyelitis | Brain, cord | Frozen, glycerol | Plain |
| Epidemic encephalitis | Brain | Frozen, glycerol | Plain |
| Equine encephalomyelitis | Brain, cord | Frozen, glycerol | Plain |
| Rabies | Brain, cord | Frozen, glycerol | Plain |
| Lymphocytic choriomeningitis | Brain, cord, liver, blood, kidney | Frozen, glycerol | Plain |
| Dengue | Lymph nodes, spleen Blood, serum | Frozen, glycerol Citrated 0-5°C. | 0-5°C. |
| Yellow fever | Liver, blood | Frozen | Plain |
| Infectious hepatitis | Liver?, duodenal contents | | Plain |
| Epidemic jaundice | Liver?, duodenal contents | Frozen | Plain |

*When complicated by encephalitis.

XI. BACTERIOLOGICAL EXAMINATION

TABLE OUTLINING COLLECTION OF MATERIAL FOR STUDY OF
SPECIFIC INFECTIONS CONTINUED

| Disease | Material desired | Mode of handling | Serum |
|---------------------------------------|---|--|-------|
| Weil's disease | Liver, kidney | 0-5°C. or +30% glycerol | Plain |
| | Blood | Citrated 0-5°C. | |
| | Serum | Capillary tubes | |
| Syphilis | Lesions, exudate | Serum in capillary tubes | Plain |
| Yaws | Lesions, exudate | Capillary tubes | Plain |
| | Lesion, blood serum | Capillary tubes | Plain |
| | Blood | Citrated 0-5°C. | |
| Relapsing fever | Blood serum | Capillary tube | |
| Vincent's angina | Lesions | Fixed smears | |
| Malaria | Spleen, marrow, blood | Thick and thin films | |
| Leishmaniasis | Lesions, spleen, marrow, blood | Thick and thin films | |
| Kala azar | Spleen, marrow, blood | Thick and thin films | |
| Trypanosomiasis | Spleen, marrow, blood, lymph nodes | Thick and thin films | |
| Chagas disease | Spleen, marrow, blood | Thick and thin films | |
| | Atria of heart | Fixed | |
| Filariasis | Blood, spleen | Thick films | |
| | Local lesion | Fixed | |
| Amebic dysentery | Colonic contents, lesion | 5% formalin | |
| Intestinal worms | Intestinal con- tents | 70% alcohol + 5% glycerin or 10% formalin + 5% glycerin | Plain |
| Egyptian schisto- somiasis | Lesion, urine, blad- der and adnexa | 10% formalin | |
| American, Oriental schistosomiasis | Lesion, gut, mesen- tery, rectal con- tents | 10% formalin | |

XI. BACTERIOLOGICAL EXAMINATION

TABLE OUTLINING COLLECTION OF MATERIAL FOR STUDY OF
SPECIFIC INFECTIONS CONTINUED

| Disease | Material desired | Mode of handling | Serum |
|-----------------------------------|--|---|-------|
| Cysticercosis, hydatid disease | Unruptured cysts | 0.3% phenol | |
| Trichinosis | Diaphragm, skeletal muscle, heart 1 foot of ileum tied off | Dry boric acid at 0-5°C. 10% formalin | Plain |

XII. SPECIAL STUDIES OF VIRAL DISEASES

In any case of suspected viral disease, steps should be taken to identify the typical histological changes in the tissue, and to isolate the virus.

For the cytological studies representative blocks of tissue should be fixed in Bouin's fluid or Zenker's fluid and cut in the usual way. For the isolation of the virus not less than 10 gm. of fresh tissue should be removed with sterile precautions from each region to be examined, and preserved in not less than 20 volumes of 50 percent buffered glycerol for each one volume of tissue. Directions for the preparation of buffered glycerol are:

Sterile Buffered Glycerol

- (1) Citric acid 21 gm. to 1,000 cc. double distilled water.
- (2) Anhydrous Na_2HPO_4 28.4 gm. to 1,000 cc. double distilled water.
- (3) Take 9.15 cc. of (1) and 90.85 cc. of (2) to make 100 cc. of buffer solution pH 7.4.
- (4) Mix equal parts of (3) and C. P. glycerol, fill cork-stoppered specimen bottles half full and sterilize at 15 lbs. of steam pressure for thirty minutes.

If buffered glycerol is not available, prepare a 50 percent solution of glycerol in a .9 percent sodium chloride solution and

XII. SPECIAL STUDIES OF VIRAL DISEASES

sterilize it. If dry ice is available, place each 10 gm. sample of tissue in a separate sterile test tube or glass bottle and keep frozen with dry ice.

In viral diseases of the central nervous system it is desirable to have blocks of fresh tissue, about 10 gm. each, from the following 9 regions:

1. Temporal lobe including the hippocampus
2. Motor cortex
3. Olfactory bulbs
4. Midbrain
5. Thalamus
6. Pons and medulla
7. Cerebellum
8. Cervical cord
9. Spinal cord as indicated

Blocks of tissue immediately adjacent should be fixed for microscopic study. These blocks should not exceed two millimeters in thickness. Bouin's or Zenker's fluid is recommended for viral diseases and Regaud's fluid for Rickettsial diseases.

XIII. IMMUNOLOGICAL EXAMINATION

The isolation of a specific bacterium or virus from the tissues does not prove that it is the cause of the disease from which the individual died. The bacterium may be a contaminant or a secondary invader. A virus found after animal passage may be a virus indigenous to the animal used for experimental inoculation. Proof of the relation of a bacterium or virus to disease may be aided by the demonstration of immune bodies in the serum of the ill individual. In all autopsies on patients suspected or known to have died of a bacterial or viral disease, 25 cc. of blood should be removed under sterile conditions from the heart, and placed in sterile centrifuge tubes. Immediately on completion of the autopsy, the sample of blood should be centrifugalized, and the serum removed with sterile pipettes and placed in clean sterile tubes in the icebox. Cresol may be added as a preservative in not over 0.3 percent concentration. No preservative is to be added when the serum is to be used for neutralization tests with viruses.

XIV. TOXICOLOGICAL AND CHEMICAL EXAMINATIONS

Toxicological analysis, especially of body fluids and tissues should never be undertaken except by those who have special training and experience, since the life or liberty of others may depend on the results. Those without experience should not use the irreplaceable material for preliminary tests. In all instances in which there is a likelihood that the investigation will result in civil or criminal litigation a sufficient amount of test material should be saved that the analyses may be repeated at the instigation of counsel for the defendant.

The Clinical History

The fullest information possible must be supplied to the toxicologist if he is to do intelligent and precise work. Points of especial importance in the history are:

- 1) The interval between taking the last food or drink and
 - a) the first appearance of symptoms of poisoning,
 - b) death, if this has occurred.
- 2) The nature of the first symptoms.
- 3) Whether or not any of the following symptoms were present, and if so, which ones, and the time of occurrence:
 - a) vomiting and/or purging
 - b) deep sleep
 - c) tingling of the skin and throat
 - d) convulsions or twitchings of the muscles
 - e) delirium, and clutching at imaginary objects.
- 4) The nature of any other symptoms noticed.
- 5) Whether or not any other person or persons partook of the suspected food or drink and whether or not this person or persons also suffered from symptoms of poisoning.
- 6) All other available information likely to prove useful as a guide to the class of poison administered.

Symptoms of Poisoning

Many diseases produce symptoms which are identical with those

XIV. TOXICOLOGICAL AND CHEMICAL EXAMINATIONS

caused by poisons, and differentiation is difficult until careful study has been made. As an aid in differentiation the following list of symptoms common to both disease and poisoning is given. It must be borne in mind that unusual symptoms may be produced in an individual by various poisons just as unusual symptoms may occur in any disease.

Vomiting

Frequently associated with purging and abdominal pain.

Poisons: Arsenic, antimony, aconite, corrosive acids and alkalies, barium, colchicum, cantharides, digitalis, copper, fluoride, iodine, mercury, phosphorus, phenols, alcohols, veratrum, zinc, poisonous foods.

Diseases: Gastritis and enteritis, gastric and duodenal ulcer, cholera, uremia, acidosis, onset of many infectious diseases, early pregnancy, brain tumor.

Convulsions

Poisons: Aspidium, brucine, camphor, cyanides, santonin, strychnine.

Diseases: Uremia, eclampsia, tetanus, epilepsy, many acute diseases of the cerebrospinal system, especially meningitis.

Coma

Poisons: Opium and its alkaloids and derivatives, chloral, sulphonal, barbiturates, paraldehyde, chloroform, cyanides, CO, CO₂, atropine, hyoscine, scopolamine, the various alcohols and phenols.

Diseases: Uremia, eclampsia, acidosis, cerebral hemorrhage, cerebral embolism and thrombosis, brain injuries, epilepsy and other brain diseases.

Dilatation of Pupil

Poisons: Belladonna and its derivatives, hyoscyamine, stramonium, gelsemium, cocaine, nicotine.

Diseases: Those causing optic atrophy, sympathetic irritation, or oculomotor paresis.

Contraction of Pupil

Poisons: Derivatives of opium, physostigmine, pilocarpine, muscarine.

XIV. TOXICOLOGICAL AND CHEMICAL EXAMINATIONS

Diseases: Tabes and certain other diseases of central nervous system.

General or Partial Paralysis

Poisons: Cyanides, CO, CO₂, botulism.

Diseases: Apoplexy, brain tumor, meningitis.

Slow Respiration

Poisons: Opium and its derivatives, CO, hypnotics.

Diseases: Uremia, compression of brain from any cause, i.e. hemorrhage.

Rapid Respiration

Poisons: Atropine group, cocaine, CO₂.

Diseases: Acute respiratory diseases, lesions of medulla, hysteria.

Delirium

Poisons: Atropine group, cocaine, cannabis indica.

Diseases: Epilepsy, insanity, delirium tremens, organic brain diseases such as meningitis, encephalitis, etc., nephritis, etc.

Dyspnea

Poisons: Strychnine (during the convulsions), cyanides, CO.

Diseases: Those of cardiac and respiratory systems, lesions of medulla and of vagus.

Cyanosis

Poisons: Nitrobenzene, aniline, acetanilide, opium.

Diseases: Same as dyspnea, prolonged convulsions due to any cause, by producing cardiac embarrassment or dilatation.

Special Investigation

In all cases of suspected poisoning a search should be made of the room or other immediate surroundings for the remains of food or drink, medicines, bottles, drinking glasses, hypodermics, etc., any of which may provide evidence of the nature of the poison. The

XIV. TOXICOLOGICAL AND CHEMICAL EXAMINATIONS

presence on the lips and tongue or in the throat of marks of corrosion, and the occurrence in the vomitus of shreds of mucosa indicate that a corrosive poison of some kind has been swallowed. The odor of the breath frequently discloses beyond a doubt that phenol or chloroform or preparations of crude opium have been taken. Careful examination of the vomitus or stomach washings, and in some cases of the feces, may give important evidence, such as the odor of phenol, of cyanides, or laudanum, the luminosity of phosphorus in the dark, and the presence of crustals, especially if colored--the colored salts of arsenic and mercury. It is the responsibility of the laboratory officer or the pathologist to collect and correlate this data. The following rules are of great assistance in distinguishing acute poisoning from disease:

- 1) In poisoning the symptoms usually appear suddenly and generally when the patient is in good health.
- 2) They commonly make their appearance after the taking of food, drink, or medicine.
- 3) If several persons take the same food or drink all will show similar symptoms.

Supplies and Equipment

In addition to the usual instruments and equipment there must be kept on hand an adequate number of glass-topped mason jars of the spring type, and wide and narrow mouthed glass stoppered bottles of various sizes. These vessels should be thoroughly scrubbed with soap and hot water, rinsed, placed in bichromate-sulfuric acid cleaning solution for several hours, rinsed thoroughly in tap water and distilled water, dried and stoppered.

Selection and Preservation of Specimens

In cases where death has occurred within a short period of time following the ingestion of a poison, only the stomach and intestinal contents are required for examination. In all other cases, and in cases about which there is doubt concerning the nature of the toxic agent, the route of administration, or the time of death in relation to the time of administration, the stomach and its contents, part of the intestine and its contents, and samples of the brain, heart, lung, liver, kidney, spleen, blood, urine, spinal fluid, muscle, bone, and hair should be taken, as indicated by the history and symptoms.

Standard Form 508
 Promulgated August 1948
 By Bureau of the Budget
 Circular A-32

| CLINICAL RECORD | | AUTOPSY PROTOCOL | | | | | |
|--------------------|-------|---------------------------------|-------|--------------|-----------|------------|--|
| DATE AND HOUR DIED | | DATE AND HOUR AUTOPSY PERFORMED | | | CHECK ONE | | |
| A. M. | P. M. | A. M. | P. M. | FULL AUTOPSY | HEAD ONLY | TRUNK ONLY | |
| SECTOR | | ASSISTANT | | | | | |

CLINICAL DIAGNOSIS (Including operations)

PATHOLOGICAL DIAGNOSES

| | | | |
|--|--|--------------|----------|
| APPROVED—SIGNATURE | | AUTOPSY NO. | |
| PATIENT'S LAST NAME—FIRST NAME—MIDDLE NAME | | REGISTER NO. | WARD NO. |

(NAME OF HOSPITAL OR OTHER MEDICAL FACILITY)

AUTOPSY PROTOCOL
 Standard Form 508

XIV. TOXICOLOGICAL AND CHEMICAL EXAMINATIONS

Each specimen should be placed in a separate, clean, glass vessel. The total quantity of fluid should be measured, and each of the viscera weighed before taking the specimen, in order that the determinations may be quantitative. Label each glass vessel with all information required to identify the specimen fully and completely. When all of the specimens are taken, wrap each in heavy paper, tie with cord, and seal the top, bottom, free edge, and knot with sealing wax. Mark the wax with some distinctive device in such a manner that tampering would be immediately evident. Keep all specimens so prepared in your immediate possession, or safely locked up, until they are shipped or otherwise delivered to the toxicologist.

If the body has been embalmed, or if the tissues have come in contact with any chemical preservative, a separate sample of this solution should be sent to the toxicologist. If a preservative must be used, 95 percent ethyl alcohol is to be preferred. No preservative should be employed when one of the poisons in question is ethyl alcohol or any other alcohol.

When specimens must be shipped to a distant laboratory, refrigeration is by far the best method of preservation, and may be accomplished by the use of either ice or dry ice. Place the solid dry ice in paper bags on top of the specimen and seal the package with strips of gummed paper. This is adequate for 72 hours. If ordinary ice is used it should be shipped by express, and arrangements made to have it re-iced en route.

Specimens Best Suited for Particular Poisons

Unless the pathologist possesses reliable information regarding the identity of the poison the following samples should be submitted for toxicological examination: brain--500 gm.; liver--500 gm.; blood--500 gm.; urine--all available; 1 kidney; 1 lung; 10 gm. of hair; and the contents of the alimentary canal. Each specimen should be placed in a separate container.

- a. Gastric and intestinal contents: for any poison taken by mouth when death has occurred within a few hours.
- b. Brain: for alcohols, chloroform, ether, alkaloids, barbiturate group, benzene.
- c. Liver: metals, barbiturate group, fluorides, oxalates.
- d. Kidney: metals, especially mercury.
- e. Blood: all gaseous poisons, drowning (see below).

XIV. TOXICOLOGICAL AND CHEMICAL EXAMINATIONS

- f. Bone: lead, arsenic, radium (especially chronic poisonings).
- g. Lung: for inhaled poisons and to prove whether poison entered by inhalation.
- h. Urine: barbiturate group, sulfonal, metals.

If the deceased lived for several days following the ingestion of certain poison, such as chloroform, ethers, alcohol, and the barbiturates, it is not likely to be detectable in materials taken at the autopsy.

Specimens From Cases of Suspected Drowning

If drowning is suspected, take samples of blood, not less than 10 cc. from the right and left sides of the heart, using pipettes with relatively large openings, and being careful not to perforate the septum. Label the bottles "left heart" and "right heart". In addition, secure a specimen of water from which the body was recovered. By determination of the amount of chloride and magnesium in each of the 3 specimens, it is frequently possible to prove that death resulted from drowning.

Shipment of Specimens

All specimens for toxicological analysis should be shipped in a container sealed with wax. A full and complete history and the complete protocol should accompany the specimens.

XV. SPECIAL EVIDENTIARY OBJECTIVES OF THE MEDICOLEGAL AUTOPSY

ALAN R. MORITZ, M.D., Boston, and HERBERT LUND, M.D., Cleveland

An autopsy performed primarily for medicolegal purposes differs from an ordinary autopsy in objectives rather than in technique. A medicolegal autopsy should invariably be witnessed by one or more persons in addition to the autopsy surgeon and the names of witnesses should be included in the report. A written record should be made of the examination at the time of its performance.

XV. SPECIAL EVIDENTIARY OBJECTIVES OF THE
MEDICOLEGAL AUTOPSY

The medicolegal autopsy has, in addition to the educational and scientific objectives of other autopsies, the special purpose of securing information needed for the administration of justice, even though such information is irrelevant by ordinary medical standards. Among the special objectives of a medicolegal autopsy the following are likely to be of particular importance:

1. Are the remains of animal or human origin?
2. Can the corpse be identified?
3. When did death occur?
4. Was the fatal injury received at the place in which the body was found?
5. Can the probable circumstances in which the fatal injuries were received be reconstructed from an examination of the body or of the place in which it was found?
6. Is there any evidence to indicate that the decedent was specially predisposed to injury by accident, suicide, or assault by reason of disease or self-induced intoxication?
7. What objective evidence is there relating to the length of time that elapsed between the incurrment of injury and the occurrence of death?
8. If there are multiple injuries, in what sequence were they received?
9. Is there evidence that more than one assailant participated in the attack and if so what injuries can be attributed to each?
10. Was the fatal injury immediately incapacitating and if not, to what extent and for how long might the decedent have been capable of executing voluntary acts after the injury was received?
11. Did the assailant leave anything in or on the body of the victim that might assist in his apprehension and identification?
12. Is it likely that recognizable traces of the victim were carried away in or on the person of the assailant?

Are The Remains of Animal or Human Origin?

Not infrequently the remains are so fragmentary or so extensively altered by postmortem change that it is not immediately apparent whether they are human or animal.

If putrefactive changes are not too advanced the distinction can be made by means of the precipitin test. Specific anti-sera are available in many large laboratories, not only for distinguishing between materials of animal and human origin but also for

XV. SPECIAL EVIDENTIARY OBJECTIVES OF THE
MEDICOLEGAL AUTOPSY

identifying the kind of an animal from which the material was derived.

If the material to be identified includes any part of the bony skeleton it is almost invariably possible to establish or exclude human origin by consultation with an anatomist, anthropologist, or roentgenologist. Even though only a small fragment of bone is available it is frequently possible to distinguish between animal and human osseous tissue by microscopic examination. There are methods available by which it is often possible to decide between animal or human origin of so small a trace as a single hair.

Can The Corpse Be Identified?

It is the responsibility of the medical investigator to see to it that photographs and fingerprints are made in all instances in which identification is doubtful. If by reason of mutilation or putrefaction it is impossible to establish identification by ordinary means, it is essential that the medical investigator procure all available information likely to be useful in establishing the individual identity of the deceased.

Reliable information concerning sex, stature, age, may be obtained even though only a part of the bony skeleton is available for examination.

Sex may frequently be recognized by the contour of the pelvis or skull, or by the size and contour of the long bones.

Age may be estimated from the epiphyses, the teeth, the laryngeal and sternal cartilages, the sacrum, the hyoid, the cranial sutures, or the condition of the joints.

Stature may be estimated by interpolating the body length from the length of the humerus, tibia, or femur by Pear's formulae.*

943.1 mm. + 1.645 (femur) \pm 48 mm. = stature
832.1 mm. + 2.715 (humerus) \pm 49 mm. = stature
955.9 mm. + 1.988 (tibia) \pm 47 mm. = stature
970.9 mm. + 2.968 (radius) \pm 54 mm. = stature

* Modified by W. M. Krogman.

XV. SPECIAL EVIDENTIARY OBJECTIVES OF THE
MEDICOLEGAL AUTOPSY

The recognition of any of a number of acquired characteristics of the bones or soft tissues may aid in the establishment of individual identity. Thus the recognition of a healed fracture may be of the utmost importance. The surgical absence of a viscous or diseased heart, rheumatic carditis, a focus of encephalomalacia or an enlarged prostate may serve to identify the remains. Detailed information concerning the last meal eaten by the deceased may aid in his identification.

When Did Death Occur?

In cases in which death was not witnessed, the findings and judgment of the physician as to the time of its occurrence are of paramount importance. The following observations are customarily made but circumstances are so varied and peculiar to the individual case that the outline is far from inclusive. Much depends upon the alertness and resourcefulness of the physician, who must extend his observations beyond strictly medical findings and consider all circumstantial evidence. The scene of discovery should be examined, preferably before the body has been removed.

1. Note the temperature of the air and ground, the condition of the bed, floor or ground on which the body lies, the weather conditions, the amount of exposure of the body, the circulation of air, and other conditions which may affect the temperature or decomposition of the body.

2. Note the internal temperature of the body, the intensity and distribution of rigor and livor. If other officials have not completed their observations, there must be as little disturbance of the body as possible in observing these conditions.

a. Temperature: Palpate the exposed and clothed parts of the body. Estimate the amount and distribution of heat. The hands and face are usually exposed and are cold when heat can still be detected in the axillae and perineal regions. If circumstances permit, take the rectal temperature. Gerhardt estimates the rate of cooling in a robust person as 3.5 degrees F. per hour for 3 hrs., then 3 degrees per hr. for 6 hrs. and then 1.2 degrees per hr. indefinitely thereafter until the temperature of the surroundings is reached. In actual practice such a rule is not practical. Cooling varies with size, clothing, wetness, circulation of air, contacts with cold surfaces, etc. Heat is dissipated

XV. SPECIAL EVIDENTIARY OBJECTIVES OF THE
MEDICOLEGAL AUTOPSY

relatively more rapidly in the first hours after death than later, although cases are observed where temperatures are practically unchanged for 2 or 3 hrs. postmortem, and postmortem elevation of temperature has been reported. A fairly practical rule is the statement of Sidney Smith that a clothed adult body at an air temperature of 50-60 degrees F. reaches the temperature of its surroundings in about 28 hrs. If the body is still much warmer than the surroundings, the rate of cooling may be estimated by repeated temperature readings.

b. Rigor: Test the rigidity of the muscles of the face, jaw, neck, abdomen and extremities. The following rules are helpful: (1) Rigor usually commences in the head and neck and progresses to the trunk and extremities, and disappears in the same order. This rule is not infallible, however. (2) Under ordinary weather conditions, incomplete rigor in a warm body is usually diminishing. (3) Even though rigor is generalized, it is still developing if it reappears after being forcibly broken. (4) It is helpful to observe the progress of rigor at definite intervals. The degree and distribution should be noted at the time the body is first discovered, again when the autopsy is commenced, again when the autopsy is completed, and still later if necessary. Interpretation: Generally speaking, there is agreement that rigor usually begins within 2 to 3 hours, is fully developed in 4 to 12 hours and disappears in 10 to 48 hours. It is accelerated by warmth and delayed by cold. It is stronger in health than after wasting disease. Exhaustion hastens its appearance. However, there are other modifying factors and precise conclusions are rarely justified. The rigidity of frozen bodies and burned bodies must be distinguished from rigor mortis.

c. Livor: The appearance of livor is of limited assistance in evaluating the time of death. It may appear before or shortly after death but is usually not definite for an hour or two. It is not fixed for about 12 hours and in cool bodies fixation may require a greater period of time. By "fixation" is meant that livor will not change when the position of the body is altered or prolonged pressure is applied to the livid part. It is well to note whether or not the distribution of livor corresponds to that expected from the position of the body.

3. The condition of the shrubs and plants adjacent to or beneath the body should be observed. Usually the grass of

XV. SPECIAL EVIDENTIARY OBJECTIVES OF THE
MEDICOLEGAL AUTOPSY

temperate climates, if overlain and shaded by a body, loses its chlorophyll in about a week. If the body has been dead for a long period of time and has arrested the growth of the plants beneath it, obtain and label such plants (if they are small) or photograph them (if large) and remove parts for identification. The season of the year in which the body was placed on the ground may thus be determined by a botanist or agriculturalist.

4. If the body is infested by insects, save (in fixative) representative adult insects (flies, beetles, etc.) as well as eggs, larvae and molts (the discarded shell-like external covering). Expert zoological examination may determine how long a time the observed stages of development required.

5. Observe blood stains as to dryness, putrefaction and dilution (as from rain or washing).

Observations to be made at the autopsy table:

1. The physician performing the autopsy should remove the clothing, itemizing each article. The personal effects should be examined for possible clues; for example, the dates of letters or presence of injury to a watch and the time of its stopping, etc. ✓

2. Supplement the findings on temperature, rigor and livor as suggested above. If these conditions are observed for the first time and the body has been removed from the site of discovery, allowances must be made for changes in the temperature, the distribution of livor and the breaking of rigor by manipulation.

3. Note the appearances of decomposition such as softening, loosening, and bleb formation of the skin, drying and discoloration of the skin, distention of the body, protrusion of tongue and eyes, subcutaneous crepitation, adipocere formation (a gray to brown, rancid, greasy change in the subcutaneous fat), texture of organs, presence of gas bubbles, the suffusion of hemoglobin, liquefaction, loss of tissue structure, etc. It is difficult to evaluate these findings because they vary with temperature, moisture, nutrition, amount of blood present in the parts, etc. Only the broadest estimations can be made. Decomposition may be detected in 4 to 5 hours or the changes may be delayed for many days, depending on the circumstances of the

XV. SPECIAL EVIDENTIARY OBJECTIVES OF THE
MEDICOLEGAL AUTOPSY

case. If the conditions of a case are of a nature not within the experience of the pathologist performing the autopsy, judgment must be guarded and advice from those adequately experienced should be sought.

4. In many cases there is reliable evidence as to the time and nature of the last meal eaten by the deceased and the progress of digestion may offer information as to the time which elapsed after that meal before death occurred. The presence of food in the gastrointestinal tract and degree of digestion. The most important consideration is the emptying of the stomach. The stomach empties promptly of a small liquid meal but slowly of coarse food. An average mixed meal is emptied in about 3 or 4 hours. Allowance must be made for local and general pathological changes. The findings are most valuable in the sudden death of a previously healthy person. Lingering deaths may inhibit digestion.

5. The volume of urine in the bladder is occasionally significant. For example, if a person found dead in bed has an empty bladder (and a full stomach), the changes are that he died shortly after retiring. If the bladder is full (and the stomach empty), death probably occurred later during the night.

Was The Fatal Injury Received At The Place In Which
The Body Was Found?

In the case of an unwitnessed death by violence it is likely to be of utmost importance to establish whether or not the fatal injuries were received at the place where the body was found.

In the case of a person found dead it may be obvious from the nature of the injuries that there would have been certain coincidental disturbances of the place where the injuries were received. The presence of injuries of such a nature as to indicate that death was preceded by a violent physical altercation would justify the assumption that they had been received elsewhere if the place in which the body was found was undisturbed. It may be apparent that the decedent bled from his wounds and if no blood is found at the place where the body was discovered it can be assumed that the injuries were sustained at some other place. In most instances in which a person is found dead as a result of mechanical violence the medical investigator should view the body and its environment before either has been disturbed.

XV. SPECIAL EVIDENTIARY OBJECTIVES OF THE
MEDICOLEGAL AUTOPSY

Can The Probable Circumstances In Which The Fatal Injuries Were
Received Be Reconstructed By Examination Of The Body And
The Place Where It Was Found?

The distribution and character of blood drops or smears may be helpful in distinguishing between accident and assault. It may be of paramount importance to establish the direction from which the fatal injury was received. Thus a wound of one type may be consistent with accident, whereas a wound of another type may provide clear evidence of assault. A wound in one location may be compatible with the defendant's plea that he acted in self-defense whereas a wound in another situation may render such an allegation untenable. A single injury may be compatible with accident whereas multiple injuries may in some circumstances be clearly indicative of deliberate assault.

The character of the place where the body was found may indicate in one instance that the injuries may well have been incurred by accident and in another instance that they were probably the result of assault. Thus multiple injuries of a person found dead at the bottom of a ravine or on a highway may be consistent with death by accident whereas the same injuries on a body found on the soft earth of a field could not be the result of an accident at that place.

A careful study of the nature and location of injuries is especially valuable in distinguishing between suicide and homicide. This is particularly true in the case of firearm injuries. In all cases of fatal firearm injury it is essential to distinguish between the entrance and the exit wound and to identify and describe with greatest possible accuracy those characteristics of the target that indicate the distance between muzzle and target at the time that the fatal shot was fired. Thus fouling of the disrupted tissues immediately beneath the entrance wound by powder residues indicates that the muzzle was in contact with the target at the moment of fire. Superficial fouling of the target by powder residues indicates that the muzzle was close to the target when the shot was fired. The shorter the distance between muzzle and target the greater will be the tendency for the combustion residues to be concentrated in the immediate vicinity of the entrance wound. Rarely will combustion products be deposited on the surface of the target if the range of fire is greater than eighteen inches. In cases of fatal injury by close range rifle or shotgun fire in which the question of suicide may be raised

XV. SPECIAL EVIDENTIARY OBJECTIVES OF THE
MEDICOLEGAL AUTOPSY

two measurements should be made. One is the distance between the entrance wound and the trigger when the muzzle is placed against the wound and the other is the distance between the entrance wound and the forefinger of the extended hand. Such measurements will reveal whether the wound could or could not have been self-inflicted.

Is There Any Evidence Regarding The Existence Of A Special
Predisposition On The Part Of The Deceased To The Incur-
ment Of Accidental Or Suicidal Injury Or To Assault?

An especially rich source of information relating to special susceptibility to injury is provided by chemical examination of the blood or brain of the decedent for alcohol. A concentration indicative of acute alcoholism may make plausible an otherwise inexplicable accident. Acute alcoholism may account for suicidal dementia or for behavior changes likely to provoke assault.

The presence of any one of a number of diseases which would predispose to unexpected collapse or to impairment of the normal protective mechanisms might serve to explain an otherwise obscure accident.

What Objective Evidence Is There Relating To The Length Of Time
That Probably Elapsed Between The Incurment Of
Injury And The Occurrence Of Death?

It may be of utmost importance from a medicolegal standpoint to establish as accurately as possible the interval between injury and death. Of aid in obtaining such information is the fact that an injury is normally followed by an orderly sequence of reactive changes. The recognition of these may make it possible to estimate the time that has elapsed. Thus it may be possible as a result of microscopic examination of the injured tissues to state with considerable certainty that a given injury could not have been sustained more than a few minutes before death or that injury was sustained hours, days, or weeks before death. The establishment of the civil or criminal responsibility of some individual may depend to a large degree upon the amount of care that has been exercised in the acquisition of such information. The circumstances may be such that a given individual could or could not be responsible for the fatal injury if it were known that it was received before or after some specified time.

XV. SPECIAL EVIDENTIARY OBJECTIVES OF THE
MEDICOLEGAL AUTOPSY

If There Are Multiple Injuries, In What Sequence Were
They Received?

Not only is it important to determine the interval between injury and death but it is also desirable to reconstruct so far as possible the sequence in which any given series of injuries were received. Not infrequently in cases of multiple injuries it is found that certain wounds were received after others. Some may even have been inflicted after death. In such instances it may be apparent that suicide or a plea of acting in self-defense is untenable. In other instances in which there are multiple injuries it may be found that individual injuries were separated by hours or even days. If such injuries have resulted from assault there may be clear evidence of premeditation and extreme cruelty.

Is There Evidence That More Than One Assailant Participated In
The Attack, And If So, What Injuries Can Be
Attributed To Each?

It is frequently impossible to determine whether one or several assailants participated in any given assault. Such a determination can be made, however, in many instances of homicide by shooting. If examination discloses that the injuries were inflicted by several different weapons as indicated by the character of the wounds or differences in bullets it may sometimes be assumed that several persons participated in the attack. It is important not only that this fact be recognized but also that a detailed description be made of the extent and nature of the injuries produced by each assailant.

Were The Injuries Immediately Incapacitating And If Not, To
What Extent And For How Long Was The Deceased Capable
Of Movement After The Injuries Were Sustained?

It may be of the utmost importance to interpret certain facts in relation to the extent to which the decedent may have contributed to their existence. In such circumstances it may be important to know what he might have done after certain injuries were sustained. If he could not have come unaided to the place where his body was found it can be assumed that someone is in possession of special knowledge regarding the circumstances in which the injury was received.

XV. SPECIAL EVIDENTIARY OBJECTIVES OF THE
MEDICOLEGAL AUTOPSY

The distribution of blood stains may indicate considerable movement on the part of a wounded person. If the decedent was injured in such a manner as to be incompatible with further locomotion it will be apparent that his assailant was also wounded.

Did The Assailant Leave Anything In Or On The Body Of The
Victim That Might Assist In His Identification?

Whenever one person injures another by means of physical violence it is probable that the assailant will leave something in or on the body of the injured person that will aid in the apprehension of the criminal. The most satisfactory evidence in this respect is provided by the finding of a bullet in the body of the dead person. A bullet frequently bears individually characteristic markings by which the firearm from which it was discharged can be identified. Even though the bullet itself is not available it may have left metallic traces in the skin or tissues by which its composition can be determined. If the bullet was fired from close range (under 18 inches) chemical or metallic residues are likely to be present on the skin or clothing of the wounded person. Appropriate examination of such residues may disclose not only the range of fire but also the nature of the ammunition that was used. The ejected shell case from which the fatal shot was fired may provide valuable evidence as to the individual identity of the weapon that was used even though the bullet itself is not available.

Wounds should be examined before the body has been moved and if it is apparent from the entrance wound that the bullet was jacketed and probably from an automatic pistol an immediate search should be instituted for the empty shell case before the body is moved. A marginally soiled entrance wound may constitute presumptive evidence that the bullet was fired from a revolver whereas a clean entrance wound sometimes indicates that the bullet was fired from an automatic pistol or a rifle.

The shape or configuration of wounds may reveal the type of instrument used in their production. Thus the pattern of an automobile tire or radiator grill may be imprinted on clothing or skin. Wounds produced by a given type of hammer, wrench, file, etc., may have highly individual characteristics. The desirability of photographing such injuries is apparent. Such photographs should either be normal size or should be taken with a ruler laid close to the area being pictured.

XV. SPECIAL EVIDENTIARY OBJECTIVES OF THE
MEDICOLEGAL AUTOPSY

If there is evidence that the victim and his assailant engaged in a struggle the latter may have been wounded and tests may disclose not only that certain blood stains were not produced by the victim but may also reveal the blood group to which the assailant belongs. Hairs of the assailant may be found in the hand of the dead person and abraded epidermis of the assailant may be found beneath the dead person's finger nails. In cases of fatal sexual attack in which rape has preceded or been coincident with murder, information useful in establishing the identity of the assailant may be obtained by testing the seminal fluid found on the person or clothing of the decedent. It may be possible to determine the blood group to which the assailant belongs even though the seminal stains are old and dry.

Is It Likely That Recognizable Traces Of The Victim Were
Carried Away In Or On The Person Of The Assailant?

It should be a routine procedure to determine the blood group of the victim of any kind of mechanical injury in which there is a possibility that blood from the decedent was transferred to the person of the assailant or to a weapon or instrument which the assailant may have taken from the scene of the attack. The finding on the clothing or on some article in the possession of a suspect of human blood similar to that of the deceased and dissimilar to that of the suspect provides presumptive evidence either of guilt or incriminating knowledge.

XVI. RESTORATION AND EMBALMING OF THE BODY

In civilian practice the pathologist should make certain that the body is restored for satisfactory work by the embalmer. The following points taken from the report on necropsies prepared by the joint committee representing the New York Academy of Medicine, the New York Pathological Society, and the Metropolitan Funeral Directors' Association under the chairmanship of Dr. George Baehr, serve as a model:

1. In males, the incision is to extend from the supra-sternal notch to the pubes in the midline, passing to the left of the umbilicus. In no circumstances shall the incision in males be extended further upward.

XVI. RESTORATION AND EMPALMING OF THE BODY

2. In females and in sailors who are to be buried in uniforms, the Y-shaped incision is to be used, that is, an incision extending from the acromial end of the clavicle to the xiphoid and up to the acromial end of the corresponding clavicle. The flap thus outlined must be dissected upward close to the deeper structures, and every effort must be made to prevent perforation of the skin in the process of dissection.

Note: In the opinion of the Conference Group the Y-shaped incision of the skin of the thorax is suitable for autopsies on men and is preferable to the incision which extends from the substernal notch to the pubis.

3. At least from one-half to 1 inch (1.2 to 2.5 cm.) of the external carotid arteries is to be left free and ligated, and at least from one-half to 1 inch of the iliacs is to be left intact and ligated.

Note: In some institutions glass cannulae with attached rubber tubing are inserted in the vessels. The rubber tubing should extend through the sutured primary incision.

4. The scalp is to be divided by an incision behind the ear, extending from one mastoid process to the other. The incision is to pass over the vertex when the hair is abundant, or somewhat posterior to this line when it is sparse. In women, the hair is to be parted along the projected line of incision to avoid cutting it. For the same reason, after the initial incision has been made, the knife should be carried in such manner that its sharp edge faces the dissector. Care should be taken not to tear or otherwise injure the scalp. The scalp is reflected backward and forward, so that the calvarium is exposed anteriorly slightly above the frontal eminences and posteriorly somewhat behind the occipital protuberance.

Before the skull is sawed, the line through which the saw is to be carried is to be mapped out with the aid of a sharp instrument. The temporal muscles are to be cut on a plane parallel with the projected line to preserve stumps on either side long enough to provide for suturing and immobilization of the replaced calvarium.

5. The removal of the skull cap is to be planned and carried out in such a manner as to insure its secure approximation. This is best accomplished by sawing in two intersecting lines which meet at an obtuse angle behind the ear, the anterior incision

XVI. RESTORATION AND EMBALMING OF THE BODY

commencing at the level of the hair line.

6. Before closing the cranial cavity, every effort should be made to provide against leakage. This is best carried out by the following procedures: (a) by ligating the carotid and vertebral arteries, (b) by plugging the foramen magnum tightly with cotton and (c) by filling the cranial cavity with oakum.

Note: Some embalmers prefer to close the base of the skull with plaster of Paris. The pathologist should inform himself concerning the usual procedure in his locality.

7. In suturing the skin a moderately small needle should be used so as to avoid leakage and disfigurement.

Note: The Conference Group recommends that thin twine, a moderately small needle and a small stitch be used in suturing the scalp, so as to avoid leakage and disfigurement.

8. After the autopsy is completed, the body is to be delivered to the embalmer in a thoroughly clean condition--the skin washed, all cavities thoroughly sponged and dried and no source of leakage allowed to remain.

9. After the completion of the autopsy, the embalmer is to be allowed the use of the autopsy room for the preparation of the body for burial, provided that this does not conflict with the immediate use of the room for another autopsy and provided also that the embalmers leave no cleaning to be done by the hospital employees.

In the armed forces it is also the responsibility of the medical officer to see that bodies of deceased military personnel are properly embalmed and dressed, and that the casket and shipping box conform with the specifications of the contract made with the local undertaker. After the performance of an autopsy it is the responsibility of the prosecutor to see that the external appearance of the body is properly restored. Before the undertaker can receive payment for his services he must show a certificate that has been signed by the medical officer, stating that all of the conditions of the contract have been fulfilled. In signing this certificate the medical officer assumes a great responsibility, and he should not sign it until he is satisfied that the body will reach the relatives in satisfactory condition. The duty of making this inspection is usually placed on the laboratory officer of the post. He should familiarize himself with the conditions of the contract and make his inspection

XVI. RESTORATION AND EMBALMING OF THE BODY

conscientiously and thoroughly. The performance of an autopsy does not interfere with proper embalming. The following suggestions are offered as a guide for the final inspection:

1. After an autopsy, those viscera which are returned to the body should be properly fixed, the body cavities drained, and the organs covered with hardening compound. Incisions should be closed neatly and tidily with overlapping of skin edges, to insure freedom from leakage in transit. The "baseball" stitch is satisfactory for this purpose.

2. The anal and genitourinary orifices of the body should be securely closed by suture or ligature.

3. There must be uniform fixation of the tissues on the surface of the body. This can be determined only by palpation, particularly of the peripheral parts--nose, ears, fingers, and toes. If any soft parts are discovered they must be "needled" by the undertaker.

4. The skin should be a light pink in color. This is attained by the addition of coloring matter to the embalming fluid and by the use of cosmetics.

5. Unsightly defects in exposed parts of the body should be properly reconstructed.

6. Clothing, usually the uniform, should be clean, tidy, properly applied, and should conform with regulations.

7. The casket and shipping box should be checked against the specifications of the contract.

XVII. COLLECTION OF DATA. SHIPMENT OF SPECIMENS

Small specimens should be shipped in double mailing cases. For protection, the glass container should be carefully packed in cotton. In addition, absorbent cotton wet with fixative should be placed in the glass vessel with the tissue. These precautions will prevent drying of the tissues if the vessel breaks. The label should be marked "First Class Mail, Rush, Specimen for Diagnosis". The pathologist should familiarize himself with the postal regulations concerning the shipment of diseased tissues.

XVII. COLLECTION OF DATA. SHIPMENT OF SPECIMENS

Larger specimen should be shipped by express.

The final autopsy protocol should include the diagnosis, the clinical abstract, the descriptive protocol, and the summary. There should be retained in the laboratory for further study or for consultation representative blocks and slides.

In the armed forces specimens should be prepared and forwarded in accordance with SR 40-410-10 BuMed Cir Ltr 50-50 AFR 160-55 dated 8 June 1950 and changes thereto.

Army-AFIP-Washington, D. C.