



JOHN CONNALLY
GOVERNOR OF TEXAS

January 8, 1964

Dear Mrs. Baker:

When a person literally owes his life to a doctor or a team of doctors, it would seemingly be easy to express his thanks. This must not be the case, however, for it is extremely difficult for me to express in words my appreciation to the medical profession for the treatment I have received at Parkland and since my return to Austin.

The severity of my wounds probably would have resulted in death had there been any delay in medical treatment. Fortunately, a hospital such as Parkland Memorial was available, staffed with personnel trained to react swiftly to any circumstances. I was saved because men and women of great skill and experience were on hand to perform their duty.

Medicine is a profession with lofty traditions. As long as there are doctors like those with whom I have been associated during these weeks of treatment and recovery, there is no doubt in my mind that American medicine will continue its great advances in service to the people.

Sincerely,

A handwritten signature in cursive script that reads "John Connally". The signature is written in dark ink and is positioned above the printed name.

John Connally

Mrs. Marilyn Baker, Managing Editor
Texas State Journal of Medicine
1801 North Lamar Boulevard
Austin, Texas



The Patients

1
2
3
4
5
6
7
8
9
10
11
12
13
14
15
16
17
18
19
20
21
22
23
24
25
26
27
28
29
30
31
32
33
34
35
36
37
38
39
40
41
42
43
44
45
46
47
48
49
50
51
52
53
54
55
56
57
58
59
60
61
62
63
64
65
66
67
68
69
70
71
72
73
74
75
76
77
78
79
80
81
82
83
84
85
86
87
88
89
90
91
92
93
94
95
96
97
98
99
100

PARKLAND Memorial Hospital, Dallas, treats an average of 272 emergency cases a day. It is adjacent to and is the major teaching hospital for the University of Texas Southwestern Medical School. It is staffed by the faculty of the medical school and has 150 interns and residents in all medical specialties. It is a modern hospital, well equipped, one of which any community might be proud. Today—and for none of these reasons—Parkland has a new reputation all over the world, and historians are typing its name into manuscripts that will be textbooks for generations to come. This has happened because three particular gunshot victims were carried there out of the bright November sunlight, two to die and the third to leave by wheel chair almost two weeks later, his arm in a sling.

Many Texas physicians have visited Parkland hospital; many have worked or trained there. Members of the Parkland staff are their acquaintances and friends. Many Texas physicians know personally the surviving gunshot victim, Gov. John Connally; some personally knew President John F. Kennedy who died in Trauma Room 1; perhaps a few even knew Lee Harvey Oswald, the man

at Parkland

charged by Dallas authorities with the assassination of the President and who was himself shot two days later.

The assassination of President Kennedy, the wounding of Governor Connally, and the fatal shooting of Oswald are events of profound import to people everywhere, but they have special, personal meaning for Texans. So because a Texas hospital and Texas physicians figured prominently in this tragedy, the *Texas State Journal of Medicine* records for its readers of the medical profession a full account of treatment given a never-to-be-forgotten trio.

When President John F. Kennedy in a moribund condition entered Parkland on Nov. 22, there was never opportunity for medical history taking. Such a history, had it been taken, would have shown that the patient "had survived several illnesses, the dangers of war, the rigor of exposure in icy waters, and . . . had waged grueling electoral campaigns in spite of a serious and painful back injury."*

Parkland records show that the President arrived at the emergency room sometime after 12:30 p.m. (There is conflict as to the exact moment.) At 1 p.m. Dr. William Kemp Clark, associate professor and chairman of the Division of Neurosurgery of the University of Texas Southwestern Medical School, declared him dead. During the interim of less than 30 minutes, continuous resuscitative efforts were made.


Later that day, several attending physicians filed reports. The following identifies these physicians and gives the gist of their reports:

Charles J. Carrico.—Dr. Carrico was the first physician to see the President. A 1961 graduate of Southwestern Medical School, he is 28 and a resident in surgery at Parkland.

He reported that when the patient entered the emergency room on an ambulance carriage he had slow agonal respiratory efforts and occasional cardiac beats detectable by auscultation. Two external wounds were noted; one a small wound of the anterior neck in the lower one third. The other wound had caused avulsion of the occipitoparietal calvarium and shredded brain tissue was present with profuse oozing. No pulse or blood pressure were present. Pupils were bilaterally dilated and fixed. A cuffed endotracheal tube was inserted through the laryngoscope. A ragged wound of the trachea was seen immediately below the larynx. The tube was advanced past the laceration and the cuff inflated. Respiration was instituted using a respirator assist on automatic cycling. Concurrently, an intravenous infusion of lactated Ringer's solution was begun via catheter placed in the right leg. Blood was drawn for typing and crossmatching. Type O Rh negative blood was obtained immediately.

In view of the tracheal injury and diminished breath sounds in the right chest, tracheostomy was performed by Dr. Malcolm O. Perry and bilateral chest tubes inserted. A second intravenous infusion was begun in the left arm. In addition, Dr. M. T. Jenkins began respiration with the anesthesia machine, cardiac monitor and stimulator attached. Solu-Cortef (300 mg.) was given intravenously. Despite those measures, blood

*Profile in Courage, *MD Medical Newsmagazine* 7:91 (Dec.) 1963.




Editor's Note.—One of the purposes of the *Texas State Journal of Medicine* has been to serve as a historical record of events affecting Texas medicine.

Although the advisors and editors of the *Journal* believe that this record of the medical treatment of President John F. Kennedy, Gov. John Connally, and Lee Harvey Oswald is also of current interest, it is their sincere belief that the historical importance of the record is of even greater value.

The record of medical treatment of three earlier assassinated Presidents of the United States (page 74) undoubtedly has provided students of gunshot wounds a significant record of the treatment available during the particular points in history at which these men died. A review of their treatment may also have aided in the search for better treatment of other victims.

There were several forms in which this record could have been carried, some of which might have provided easier reading, usually an important goal of this *Journal*. The advisors to the *Journal* considered providing a composite review or a reconstructed scene of the events in the operating rooms at Parkland, but to some extent other publications have done this and it was felt that the impressions of the individual participating physicians, written in a period of strain, without consideration for rhetoric, was perhaps of greatest value to medical history.

Therefore, the *Journal* presents the reports showing the separate views of the physicians in charge to let the reader see for himself part of history as it was recorded a few hours after the events of Nov. 22 and Nov. 24. Like the various aspects of the four gospels, as reported by Matthew, Mark, Luke, and John, it is hoped that this form will provide an insight not possible in a more concise, composite presentation.



pressure never returned. Only brief electrocardiographic evidence of cardiac activity was obtained.

Malcolm O. Perry.—Dr. Perry is an assistant professor of surgery at Southwestern Medical School from which he received his degree in 1955. He is 34 years old and was certified by the American Board of Surgery in 1963.

At the time of initial examination of the President, Dr. Perry has stated, the patient was noted to be nonresponsive. His eyes were deviated and the pupils dilated. A considerable quantity of blood was noted on the patient, the carriage, and the floor. A small wound was noted in the midline of the neck, in the lower third anteriorly. It was exuding blood slowly. A large wound of the right posterior cranium was noted, exposing severely lacerated brain. Brain tissue was noted in the blood at the head of the carriage.

Pulse or heart beat were not detectable, but slow spasmodic respiration was noted. An endotracheal tube was in place and respiration was being controlled. An intravenous infusion was being placed in the leg. While additional venesections were done to administer fluids and blood, a tracheostomy was effected. A right lateral injury to the trachea was noted. The cuffed tracheostomy tube was put in place as the endotracheal tube was withdrawn and respirations continued. Closed chest cardiac massage was instituted after placement of sealed-drainage chest tubes, but without benefit. When electrocardiogram evaluation revealed that no detectable electrical activity existed in the heart, resuscitative attempts were abandoned. The team of physicians determined that the patient had expired.

Charles R. Baxter.—Dr. Baxter is an assistant professor of surgery at Southwestern Medical School where he first arrived as a medical student in 1950. Except for two years away in the Army he has been at Southwestern and Parkland ever since, moving up from student to intern to resident to faculty member. He is 34 and was certified by the American Board of Surgery in 1963.

Recalling his attendance to President Kennedy, he says he learned at approximately 12:35 that the President was on the way to the emergency room and that he had been shot. When Dr. Baxter arrived in the emergency room, he found an endotracheal tube

in place and respirations being assisted. A left chest tube was being inserted and cut-downs were functioning in one leg and in the left arm. The President had a wound in the midline of the neck. On first observation of the other wounds, portions of the right temporal and occipital bones were missing and some of the brain was lying on the table. The rest of the brain was extensively macerated and contused. The pupils were fixed and deviated laterally and were dilated. No pulse was detectable and ineffectual respirations were being assisted. A tracheostomy was performed by Dr. Perry and Dr. Baxter and a chest tube was inserted into the right chest (second interspace anteriorly). Meanwhile one pint of O negative blood was administered without response. When all of these measures were complete, no heart beat could be detected. Closed chest massage was performed until a cardioscope could be attached. Brief cardiac activity was obtained followed by no activity. Due to the extensive and irreparable brain damage which existed and since there were no signs of life, no further attempts were made at resuscitation.

Robert N. McClelland.—Dr. McClelland, 34, assistant professor of surgery at Southwestern Medical School, is a graduate of the University of Texas Medical Branch in Galveston. He has served with the Air Force in Germany and was certified by the American Board of Surgery in 1963.

Regarding the assassination of President Kennedy, Dr. McClelland says that at approximately 12:35 p.m. he was called from the second floor of the hospital to the emergency room. When he arrived, President Kennedy was being attended by Drs. Perry, Baxter, Carrico, and Ronald Jones, chief resident in surgery. The President was at that time comatose from a massive gunshot wound of the head with a fragment wound of the trachea. An endotracheal tube had been placed and assisted respiration started by Dr. Carrico who was on duty in the emergency room when the President arrived. Drs. Perry, Baxter, and McClelland performed a tracheostomy for respiratory distress and tracheal injury. Dr. Jones and Dr. Paul Peters, assistant professor of surgery, inserted bilateral anterior chest tubes for pneumothoraces secondary to the tracheo-mediastinal injury. Dr. Jones and assistants had started three cutdowns, giving blood and fluids immediately. In spite of this, the President was pronounced dead at 1:00 p.m. by

Dr. Clark, the neurosurgeon, who arrived immediately after Dr. McClelland. The cause of death, according to Dr. McClelland was the massive head and brain injury from a gunshot wound of the right side of the head. The President was pronounced dead after external cardiac massage failed and electrocardiographic activity was gone.

Fouad A. Bashour.—Dr. Bashour received his medical education at the University of Beirut School of Medicine in Lebanon. He is 39 and an associate professor of medicine in cardiology at Southwestern Medical School.

At 12:50 p.m. Dr. Bashour was called from the first floor of the hospital and told that President Kennedy had been shot. He and Dr. Donald Seldin, professor and chairman of the Department of Internal Medicine, went to the emergency room. Upon examination, they found that the President had no pulsations, no heart beats, no blood pressure. The oscilloscope showed a complete standstill. The President was declared dead at 1:00 p.m.

William Kemp Clark.—Dr. Clark is associate professor and chairman of the Division of Neurosurgery at Southwestern Medical School. The 38-year-old physician has done research on head injuries and has been at Southwestern since 1956.

He reports this account of the President's treatment:

The President arrived at the emergency room entrance in the back seat of his limousine. Governor Connally of Texas was also in this car. The first physician to see the President was Dr. Carrico.

Dr. Carrico noted the President to have slow, agonal respiratory efforts. He could hear a heart beat but found no pulse or blood pressure. Two external wounds, one in the lower third of the anterior neck, the other in the occipital region of the skull, were noted. Through the head wound, blood and brain were extruding. Dr. Carrico inserted a cuffed endotracheal tube and while doing so, he noted a ragged wound of the trachea immediately below the larynx.

At this time, Drs. Perry, Baxter, and Jones arrived. Immediately thereafter, Dr. Jenkins and Drs. A. H. Giesecke, Jr., and Jackie H. Hunt, two other staff anesthesiologists, arrived. The endotracheal tube had been connected to a respirator to assist the President's breathing. An anesthesia machine was substituted for this by Dr. Jen-

kins. Only 100 per cent oxygen was administered.

A cutdown was performed in the right ankle, and a polyethylene catheter inserted in the vein. An infusion of lactated Ringer's solution was begun. Blood was drawn for typing and crossmatching, but unmatched type O Rh negative blood was immediately obtained and begun. Hydrocortisone (300 mg.) was added to the intravenous fluids.

Dr. McClelland arrived to help in the President's care. Drs. Perry, Baxter, and McClelland did a tracheostomy. Considerable quantities of blood were present in the President's oral pharynx. At this time, Dr. Peters and Dr. Clark arrived.

Dr. Clark noted that the President had bled profusely from the back of the head. There was a large (3 by 3 cm.) amount of cerebral tissue present on the cart. There was a smaller amount of cerebellar tissue present also.

The tracheostomy was completed and the endotracheal tube was withdrawn. Suction was used to remove blood in the oral pharynx. A nasogastric tube was passed into the stomach. Because of the likelihood of mediastinal injury, anterior chest tubes were placed in both pleural spaces. These were connected to sealed underwater drainage.

Neurological examination revealed the President's pupils to be widely dilated and fixed to light. His eyes were divergent, being deviated outward; a skew deviation from the horizontal was present. No deep tendon reflexes or spontaneous movements were found.

When Dr. Clark noted that there was no carotid pulse, he began closed chest massage. A pulse was obtained at the carotid and femoral levels.

Dr. Perry then took over the cardiac massage so that Dr. Clark could evaluate the head wound.

There was a large wound beginning in the right occiput extending into the parietal region. Much of the right posterior skull, at brief examination, appeared gone. The previously described extruding brain was present. Profuse bleeding had occurred and 1500 cc. of blood was estimated to be on the drapes and floor of the emergency operating room. Both cerebral and cerebellar tissue were extruding from the wound.

By this time an electrocardiograph was

hooked up. There was brief electrical activity of the heart which soon stopped.

The President was pronounced dead at 1:00 p.m. by Dr. Clark.

M. T. Jenkins.—Dr. Jenkins is professor and chairman of the Department of Anesthesiology at Southwestern Medical School. He is 46, a graduate of the University of Texas Medical Branch in Galveston, and was certified by the American Board of Anesthesiology in 1952. During World War II he served in the Navy as a lieutenant commander.

When Dr. Jenkins was notified that the President was being brought to the emergency room at Parkland, he dispatched Drs. Giesecke and Hunt with an anesthesia machine and resuscitative equipment to the major surgical emergency room area. He ran downstairs to find upon his arrival in the emergency operating room that Dr. Carrico had begun resuscitative efforts by introducing an orotracheal tube, connecting it for controlled ventilation to a Bennett intermittent positive pressure breathing apparatus. Drs. Baxter, Perry, and McClelland arrived at the same time and began a tracheostomy and started the insertion of a right chest tube, since there was also obvious tracheal and chest damage. Drs. Peters and Clark arrived simultaneously and immediately thereafter assisted respectively with the insertion of the right chest tube and with manual closed chest cardiac compression to assure circulation. Dr. Jenkins believes it evidence of the clear thinking of the resuscitative team that the patient received 300 mg. hydrocortisone intravenously in the first few minutes.

For better control of artificial ventilation, Dr. Jenkins exchanged the intermittent positive pressure breathing apparatus for an anesthesia machine and continued artificial ventilation. Dr. Gene Akin, a resident in anesthesiology, and Dr. Giesecke connected a cardioscope to determine cardiac activity.

During the progress of these activities, the emergency room cart was elevated at the feet in order to provide a Trendelenburg position, a venous cutdown was performed on the right saphenous vein, and additional fluids were begun in a vein in the left forearm while blood was ordered from the blood bank. All of these activities were completed by approximately 12:50 at which time external cardiac massage was still being carried out effectively by Dr. Clark as judged

by a palpable peripheral pulse. Despite these measures there was only brief electrocardiographic evidence of cardiac activity.

These described resuscitative activities were indicated as of first importance, and after they were carried out, attention was turned to other evidences of injury. There was a great laceration on the right side of the head (temporal and occipital), causing a great defect in the skull plate so that there was herniation and laceration of great areas of the brain, even to the extent that part of the right cerebellum had protruded from the wound. There were also fragmented sections of brain on the drapes of the emergency room cart. With the institution of adequate cardiac compression, there was a great flow of blood from the cranial cavity, indicating that there was much vascular damage as well as brain tissue damage. President Kennedy was pronounced dead at 1 p.m.

It is Dr. Jenkins' personal feeling that all methods of resuscitation were instituted expeditiously and efficiently. However, he says, the cranial and intracranial damage was of such magnitude as to cause irreversible damage.

John Connally

The health of the Governor of Texas has been news on at least two occasions before his serious injury on Nov. 22. As Secretary of the Navy, while on a visit to Austin, John Connally was accidentally stabbed in the eye by a bayonet as he reviewed ROTC troops; and shortly after his inauguration as Governor, he underwent surgery for hernia.

When he arrived with the President at Parkland's emergency entrance, the Governor had been wounded by a bullet that had pierced his chest, arm, and thigh. In a recent interview with editors of the *Journal*, he recalled raising himself up in the back seat of the limousine but was unable to raise himself onto the stretcher. Mrs. Connally, the Governor's wife, also present at the interview, explained that her husband, still conscious, was then aided in getting onto the stretcher. He was then taken into Trauma Room 2, across the hall from Trauma Room 1 where the President had been carried.

Soon afterwards he was taken to an operating room. Later, four Parkland physicians described the treatment given the Governor.

Text of Note to Hospital From Governor

November 30, 1963

TO THE STAFF AND PERSONNEL
OF PARKLAND HOSPITAL:

Words cannot adequately express my personal appreciation for the care, treatment and supreme thoughtfulness my family and I have received from all of you.

These have been trying days for everyone connected with this great hospital, but you have risen to the occasion with a dedication to duty which merits the highest confidence and praise. Parkland has proved again that it is one of the finest institutions of its kind in the world.

I will probably not have the opportunity to thank each of you individually, so I hope you will accept this message as an expression of my heartfelt gratitude. I speak also for Mrs. Connally, the children, other members of my family, my staff and the officers of the Department of Public Safety who have received so many courtesies from Parkland employees. We will always remember your help and consideration.

Sincerely,
(Signed)
JOHN CONNALLY

Robert R. Shaw.—Dr. Shaw, professor of thoracic surgery at Southwestern Medical School, returned to Dallas last summer after spending a year and a half in Kabul, Afghanistan, as head of the Medico team there. A graduate of the University of Michigan Medical School at Ann Arbor, he is 58. He was certified by The Board of Thoracic Surgery in 1948, and has practiced in Dallas since 1938.

Dr. Shaw performed a thoracotomy, removed rib fragments, and debrided the chest wound. Diagnosis of the chest condition was gunshot wound of the chest with comminuted fracture of the fifth rib, laceration of the middle lobe, and hematoma of the lower lobe of the right lung.

The Governor was brought to the operating room from the emergency operating room where a sucking wound of the right chest had been partially controlled by an occlusive dressing supported by manual pressure. A tube had been placed through the second interspace of the right chest in the mid-clavicular line and connected to a water-seal bottle to evacuate the hemopneumothorax. An intravenous infusion of lactated Ringer's solution had already been started. As soon as the patient was positioned on the operating table the anesthesia was induced by Dr. Giesecke and an endotracheal tube was put in place.

As soon as it was possible to control respiration with positive pressure, the occlu-

sive dressing was taken from the right chest and the extent of the wound more carefully determined. It was found that the bullet had made a wound of entrance just lateral to the right scapula, close to the axilla, had passed through the latissimus dorsi muscle, shattered approximately 10 cm. of the lateral and anterior portion of the right fifth rib, and emerged below the right nipple. The wound of entrance was approximately 3 cm. in its longest diameter and the wound of exit was a ragged wound approximately 5 cm. in its greatest diameter. The skin and subcutaneous tissue over the path of the missile moved in a paradoxical manner with respiration indicating softening of the chest.

The skin of the whole area was carefully cleansed with Phisohex and iodine. The entire area, including the wound of entrance and wound of exit, was draped partially excluding the wound of entrance for the first part of the operation.

An elliptical incision was made around the wound of exit removing the torn edges of the skin and the damaged subcutaneous tissue. The incision was then carried in a downward curve up toward the right axilla so as not to have the skin incision over the actual path of the missile through the chest wall. This incision was carried down through the subcutaneous tissue to expose the serratus anterior muscle and the anterior border of the latissimus dorsi muscle.

The fragmented and damaged portions of the serratus anterior muscle were excised. Small rib fragments that were adhering to periosteal tags were carefully removed preserving as much periosteum as possible. The fourth and fifth intercostal muscle bundles were not appreciably damaged. The ragged ends of the damaged fifth rib were cleaned with the rongeur. The pleura had been torn open by the secondary missiles created by the fragmented fifth rib.

The wound was widely opened and exposure was maintained with a self-retaining retractor. Approximately 200 cc. of clot and liquid blood was removed from the pleural cavity. The middle lobe had a linear rent starting at its peripheral edge, going down toward the hilum separating the lobe into two segments. There was an open bronchus in the depth of this laceration. Since the vascularity and the bronchial connections to the lobe were intact it was decided to repair the lobe rather than to remove it. The repair was accomplished with a running suture of #000

chromic gut on an atraumatic needle closing both pleural surfaces as well as two running sutures approximating the tissue of the central portion of the lobe. This almost completely sealed off the air leaks which were evident in the torn portion of the lobe. The lower lobe was next examined and found to be engorged with blood and at one point a laceration allowed the oozing of blood from the lobe. This laceration had undoubtedly been caused by a rib fragment. The laceration was closed with a single suture of #000 chromic gut on an atraumatic needle. The right pleural cavity was now carefully examined. Small rib fragments were removed. The diaphragm was found to be uninjured. There was no evidence of injury to the mediastinum and its contents. Hemostasis had been accomplished within the pleural cavity with the repair of the middle lobe and the suturing of the laceration in the lower lobe. The upper lobe was found to be uninjured.


The drain which had previously been placed in the second interspace in the mid-clavicular line was found to be longer than necessary so approximately 10 cm. of it was cut away and the remaining portion was fenestrated with two additional openings. An additional drain was placed through a stab wound in the eighth interspace in the posterior axillary line. Both these drains were then connected to a waterseal bottle.

The fourth and fifth intercostal muscles were then approximated with interrupted sutures of #0 chromic gut. The remaining portion of the serratus anterior muscle was then approximated across the closure of the intercostal muscle. The laceration of the latissimus dorsi muscle on its inner surface was then closed with several interrupted sutures of #0 chromic gut.

Before closing the subcutaneous tissue, 1,000,000 units of penicillin and 1 gm. of streptomycin in 100 cc. normal saline were instilled into the wound.

A small wound was then made in the most dependent portion of the wound coming out near the angle of the scapula. A large Penrose drain was drawn out through this stab wound to allow drainage of the wound of the chest wall. The subcutaneous tissue was then closed with interrupted #0 chromic gut, inverting the knots. The skin was closed with interrupted vertical sutures of black silk.

Attention was next turned to the wound of entrance. It was excised with an elliptical incision. It was found that the latissimus



Parkland Memorial Hospital

dorsi muscle, although lacerated, was not badly damaged so that the opening was closed with sutures of #0 chromic gut in the fascia of the muscle. Before closing this incision, the Penrose drain could be felt, by palpation with the index finger, immediately below in the space beneath the latissimus dorsi muscle. The skin was closed with interrupted vertical mattress sutures of black silk. Drainage tubes were secured with safety pins and adhesive tape, and dressings were applied.

As soon as the operation on the chest had been concluded, Drs. Gregory and Shires started the surgery that was necessary for the wounds of the right wrist and left thigh.

Charles F. Gregory.—Dr. Gregory is an orthopedic surgeon certified in 1953 by the American Board of Orthopaedic Surgery. He is 44, professor and chairman of orthopedic surgery at Southwestern Medical School, and a graduate of the Indiana University School of Medicine, Indianapolis. He is a veteran of both World War II and the Korean War.

There was comminuted fracture of the Governor's right distal radius which occurred when the bullet passed through the chest and struck the arm. Dr. Gregory debrided the wound and reduced the fracture.

This took place while the patient was still under general anesthesia following a thoracotomy and repair of the chest injury which was done by Dr. Shaw.

The right upper extremity was thoroughly shaved and prepped in the routine fashion. The patient was draped in the routine fashion using stockinette. An addition was the use of a debridement pan.

The wound of entry on the dorsal aspect of the distal right forearm at the junction of the distal fourth of the radius and its shaft was approximately 2 cm. in length and rather oblique, with a loss of tissue and with considerable contusion at its margins. There was a wound of exit along the volar surface of the wrist about 2 cm. above the flexion crease of the wrist in the midline.

The wound of entrance was carefully ex-

cised and developed through the muscles and tendons from the radial side of that bone to the bone itself where the fracture was encountered. It was noted that the tendon of the abductor pollicis longus was transected. Only two small fragments of bone were removed; one approximately 1 cm. in length consisted of lateral cortex which lay free in the wound and had no soft tissue connections, and another much smaller fragment 3 mm. in length. Small bits of metal were encountered at various levels throughout the wound. Wherever they were identified and could be picked up, they were submitted to the Pathology Department. Throughout the wound there were noted fine bits of cloth like mohair. Dr. Gregory was told that the patient was wearing a mohair suit at the time of the injury thus accounting for the deposition of such organic material within the wound.

After as careful and complete a debridement of the volar wound as possible and the integrity of the flexor tendons and the median nerve on the volar side established, the wound of exit on the volar surface of the wrist was closed primarily with wire sutures. The wound of entrance on the radial side of the forearm was only partially closed, being left open for the purpose of drainage. This was in deference to the presence of mohair and organic material deep in the wound.

In view of the urgency of the Governor's original chest injury, it was impossible to definitely ascertain the status of the circulation or the nerve supply to the hand and wrist on the right side on admission. Accordingly, it was determined as best it could be at the time of the operation. The radial artery was found to be intact and pulsating normally. The integrity of the median nerve and the ulnar nerve over a long distance was not established by Dr. Gregory. These would be repaired at a later date if necessary. Following closure of the volar wound and partial closure of the radial wound, dry sterile dressings were applied and a long arm cast was then applied with skin traction, rubber band variety, attached to the thumb and index finger of the right hand. An attitude of flexion was arranged at the right elbow, and postoperatively the limb was suspended from an overhead frame.

George Thomas Shires.—Dr. Shires, 38, is professor and chairman of the Department of Surgery at Southwestern Medical School.

He is a 1948 graduate of Southwestern, a former Navy officer, and was certified by the American Board of Surgery in 1956.

Dr. Shires performed the surgery for exploration and debridement of the gunshot wound of the Governor's left thigh. The operation lasted 20 minutes. He reported that there was a 1 cm. punctate missile wound over the juncture of the middle and lower third, medial aspect, of the left thigh. X-rays of the thigh and leg revealed a bullet fragment which was imbedded in the body of the femur in the distal third. The leg was prepared with Phisohex and iodine and was draped in the usual fashion.

Following this, the missile wound was excised and the bullet tract was explored. The missile wound was seen to course through the subcutaneous fat and into the vastus medialis. The necrotic fat and muscle were debrided down to the region of the femur. The direction of the missile wound was judged not to be in the course of the femoral vessel, since the wound was distal and anterior to Hunter's canal. Following complete debridement of the wound and irrigation with saline, the wound was felt to be adequately debrided enough so that three simple through-and-through, stainless steel alloy #28 wire sutures were used encompassing skin, subcutaneous tissue, and muscle fascia on both sides. Following this, a sterile dressing was applied. The dorsalis pedis and posterior tibial pulses in both legs were good. The thoracic procedure had been completed at this time, the debridement of the compound fracture in the arm was still in progress at the time this soft tissue injury repair was completed.

The Governor's postoperative convalescence has been good, according to Dr. Shires. On the sixth postoperative day, the cast on his right arm was windowed and a routine delayed primary closure, with through-and-through stainless steel alloy wire, was performed. On the 14th postoperative day, the arm was x-rayed and a new cast was applied. On the 19th postoperative day, after ambulation, the Governor developed a superficial saphenous thrombophlebitis in the right ankle. This was the site of a sterile cutdown done in the operating room at the time of the initial injury for the administration of blood, fluids, and antibiotics. For this he was placed on a regimen of bed rest, elevation, heat, and heparin for a period of two weeks.

A. H. Giesecke, Jr.—Dr. Giesecke is an as-

sociate anesthesiologist in the Department of Anesthesiology at Parkland and an assistant professor at the University of Texas Southwestern Medical School. He is 31 years old and a 1957 graduate of the University of Texas Medical Branch.

Dr. Giesecke had learned from Dr. Jenkins that the President had been shot. He went to Trauma Room 1 to assist with the President, but was soon called to attend Governor Connally in Operating Room No. 5 in the main operating suite on the second floor where the Governor had been taken. On the way, Dr. Hunt briefed him, saying that she had examined the Governor and had found his color to be ashen, his pulse was of normal rate and volume, but he was dyspneic and tachypneic, grunting as he exhaled. She recalled having passed a cuff link to Mrs. Connally while the Governor was having a chest tube placed.

Upon arrival in the operating room, Dr. Giesecke was brought an anesthesia machine which he hurriedly checked for safe operation. He then introduced himself to the Governor, determined that he had not eaten since early morning, had not had any serious medical illnesses, and had not been in shock. At this time, he had 150 ml. of blood in the chest bottle, his color was as Dr. Hunt had described, his nail beds were cyanotic, his pulse was 100 and full, and he was alert and had not been premedicated.

Dr. Giesecke checked his mouth for foreign bodies and started 10 liters per minute oxygen by mask from the anesthesia machine. At this time he was having a cutdown performed in his right ankle and his trunk shaved from the clavicles down, including the right axilla. A Foley catheter was being placed in his bladder and 200 cc. urine was recorded.

Because of his poor color, respiratory distress, and probable large blood loss, Dr. Giesecke decided to omit thiopental and to use cyclopropane and oxygen. Accordingly, he asked for quiet and for the Governor to be covered with a clean cotton blanket. At 1 p.m., 20 minutes after his arrival in the emergency room, Dr. Giesecke started slowly with 800 cc. cyclopropane per minute plus 2 liters of oxygen per minute. His color had improved but his respirations were still rapid at 40 with grunting exhalations. The Governor lost consciousness without excitement at 1:07 p.m. and was given 80 mg. succinylcholine chloride very slowly intravenously to

prevent hard fasciculations and passive regurgitation. Laryngoscopy was atraumatic and easy and no abnormalities were noted. The pharynx and trachea were sprayed with 4 per cent cocaine and intubated with a 34 Fr. endotracheal tube with a Knight-Grimm-Sanders cuff which was inflated to provide a good fit.

During the induction, Dr. Hunt connected the leads to the electrocardiograph monitor. Dr. Hunt reported a very transient bradycardia during the intubation. The pulse rapidly returned to 100 and the electrocardiogram looked normal. A blood pressure cuff and stethoscope was applied to the left arm and blood pressure was noted at 100/70. The explosion-proof x-ray machine was moved in and x-rays taken of the chest, right arm, and left thigh and leg. Blood was drawn for typing and crossmatching, and the hemoglobin was reported at 15.2 gm. per 100 cc.; urine was normal. Respirations were controlled, the position of the endotracheal tube was checked by auscultation of the chest and reference to the x-rays. The Governor was placed in a semi-lateral position with the wounded side up. The right arm, by a sling over the chest, was supported from the operating table. The skin incision was made at 1:35, 55 minutes after the Governor arrived in the emergency room.

Dr. Shaw, Dr. James Boland, resident in thoracic surgery, and Dr. James Duke, resident in surgery, operated for 1 hour and 45 minutes. The patient's position was changed to supine, and Drs. Gregory and William Osborn operated on the arm and Drs. Shires, and McClelland operated on the left arm simultaneously.

The cyclopropane was turned off at 4:45 p.m. and 50 mg. meperidine was given intravenously. The Governor regained consciousness during the application of the cast to the right arm and forearm. The endotracheal tube was irrigated with 50 ml. normal saline in 10 ml. increments, followed by suctioning, which yielded moderate amounts of bloody mucus. The oropharynx was cleaned. The estimated blood loss at surgery was 1296 cc. in the chest bottle, suction bottle, and weighed sponges. Urine output was 450 cc. He received 3 liters of lactated Ringer's solution, 2 liters of which contained 5 per cent dextrose; 2000 ml. whole blood; and 125 ml. 5 per cent dextrose in water. His color was pink, pulse 110, blood pressure 120/70, and his extremities were warm and dry. He was

awake, could open his eyes, and nod his head on command; therefore he was extubated.

Total anesthetic time was 3 hours and 50 minutes; total operating time was 3 hours and 15 minutes.

Upon extubation, Governor Connally spoke immediately, saying he felt well, but he was somewhat restless.

The immediate postoperative course was satisfactory, without hypotension, and with only a hint of cyanosis, which resolved over the following three to four hours; during which time he complained of soreness of his right shoulder and a sensation of needing to urinate, caused by the urethral catheter.

During surgery he received 1,000,000 units of penicillin after it was determined that he was not sensitive following a discussion with his wife and a call to Dr. W. B. Swift of Fort Worth. In addition, he received 500 mg. tetracycline. He had received 0.5 cc. tetanus toxoid in the emergency room prior to transfer to the main operating suite.

Lee Harvey Oswald

On Nov. 24, two days after the shooting of President Kennedy and Governor Connally, an ironic event brought to Parkland the man whom Dallas police had charged with the murder of the President. Lee Harvey Oswald, 24, had been shot.

Initial care and surgery were handled by Parkland physicians, including some of those who had cared for the President and the Governor. Oswald was brought into the emergency room at 11:32 a.m., to the operating room at 11:42 a.m. and at 1:07 p.m. he was pronounced dead in spite of all efforts.

Dr. Shires.—The surgery performed on Oswald, who had been shot in the upper abdomen and chest, was done by Drs. Shires, Perry, McClelland, and Jones, and included an exploratory laparotomy, thoracotomy, and efforts to repair the aorta, vena cava, and multiple organ injuries. Dr. Shires has said that on previous inspection an entrance wound over the left lower lateral chest edge was revealed and an exit was identified by subcutaneous palpation of the bullet over the right lower lateral chest cage. At the time he was seen preoperatively, Oswald was without perceptible blood pressure, his heart beat was heard intermittently at 130 beats per minute, he had an endotracheal tube in place and was receiving only oxygen by anesthesia at the time he was moved to the operating room.

Under endotracheal oxygen anesthesia, a long midline abdominal incision was made. Bleeders were not apparent and none were clamped or tied. Upon opening the peritoneal cavity, approximately 2 to 3 liters of blood, both liquid and in clots, was encountered. This was removed. The bullet pathway was then identified as having shattered the upper medial surface of the spleen, then entered the retroperitoneal area where there was a large retroperitoneal hematoma in the area of the pancreas. Following this, bleeding was seen to be coming from the right side, and upon inspection, there was seen to be an exit to the right through the inferior vena cava, thence through the superior pole of the right kidney, the lower portion of the right lobe of the liver, and into the right lateral body wall.

First the right kidney, which was bleeding, was identified, dissected free, retracted medially, and the inferior vena cava hole was clamped with a partial occlusion clamp of the Satinsky type. Following this immobilization, packing controlled the bleeding from the right kidney.

Attention was then turned to the left, as bleeding was massive from the left side. The inspection of the retroperitoneal area revealed a huge hematoma in the midline. The stomach had been penetrated by the bullet. The spleen was then mobilized, as was the left colon, and the retroperitoneal approach was made to the midline structures. The pancreas appeared to be shattered in its midportion; bleeding was seen to be coming from the aorta. This was dissected free. Bleeding was controlled with finger pressure by Dr. Perry. Upon identification of this injury, it was seen that the superior mesenteric artery had been sheared off of the aorta; there was some back bleeding from the artery. This was cross-clamped with a small, curved DeBakey clamp. The aorta was then occluded with a straight DeBakey clamp above and a Potts clamp below. At this point all major bleeding was controlled, blood pressure was reported to be in the neighborhood of 100 systolic. Shortly thereafter, however, the pulse rate, which had been in the 80 to 90 range, was found to be 40, and a few seconds later found to be zero. No pulse was felt in the aorta at this time. Consequently, the left chest was opened by Dr. Perry through an intercostal incision in approximately the fourth intercostal space. A Finochietto retractor was inserted, and the heart was seen to be flabby and not beating at all. There

was no hemopericardium. There was a hole in the diaphragm but no hemothorax. A left closed suction chest tube had been introduced while the patient was in the emergency room prior to surgery, so that there was no significant pneumothorax on the left side. The pericardium was opened, cardiac massage was started, and a pulse was obtainable with massage. The heart was flabby, consequently calcium chloride followed by 1 mg. epinephrine hydrochloride and 90 mg. Xylocaine Hydrochloride were injected into the left ventricle. The standstill converted to fibrillation. Following this defibrillation was done, using 240, 360, 500, and 750 volts, and finally successful defibrillation was accomplished after a second attempt with the defibrillator. However, no effective heart beat could be instituted. A pacemaker was inserted into the wall of the right ventricle and grounded on skin, and pacemaking was started. A very feeble, small, localized, muscular response was obtained with the pacemaker, but still no effective heart beat. At this time Dr. Shires was informed by Dr. Jenkins that there were no signs of life in that the pupils were fixed and dilated, there was no retinal blood flow, no respiratory effort, and no effective pulse could be maintained even with cardiac massage. The patient was pronounced dead at 1:07 p.m.

Anesthesia consisted entirely of oxygen. The patient was never conscious from the time of his arrival in the emergency room until his death at 1:07 p.m. The subcutaneous bullet was extracted from the side during the attempts at defibrillation which were rotated among the surgeons. The cardiac massage and defibrillation attempts were carried out by Drs. McClelland, Perry, and Jones. Assistance was obtained from the cardiologist, Dr. Bashour.

Dr. Jenkins.—In a statement concerning resuscitative efforts for Oswald, Dr. Jenkins reported that Dr. Jones, after being notified through the office of the administrator of the hospital, informed a surgical and anesthesiology team that Lee Harvey Oswald had sustained a gunshot wound and was being brought to the emergency operating room for emergency and definitive treatment. By the time that the patient, Oswald, was registered into the emergency operating room, there was assembled a resuscitative team in the emergency operating room surgical room.

Dr. Jenkins recalls that the following physicians were members of the resuscitation

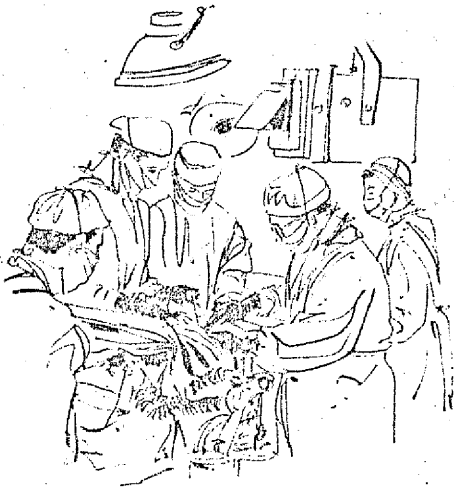team: Drs. Jenkins and Akin, with an anesthesia machine and full resuscitative equipment for the maintenance of ventilation; Drs. Gerry Gustafson, Dale Coln, and Charles Crenshaw, all residents in surgery, who were prepared to introduce cannulae into the veins via cutdowns or percutaneous puncture; Dr. Jones with chest drainage equipment; Dr. William R. Osborne, resident in orthopedics, for necessary orthopedic services; and Dr. William Risk, resident in urology, for evaluation of possible urological damage. Dr. Perry was present to direct the surgical approach. There were many other medical personnel present in addition to these, but the physicians named figured importantly in the initial resuscitative experience, Dr. Jenkins said.

As the patient, Oswald, was brought into the operating room, Dr. Akin introduced a #36 cuffed endotracheal tube and connected it to an anesthesia machine for assisted ventilation or controlled respiration with oxygen. It was obvious that the patient was in extremis as judged by his general pallor, the cold extremities, the dusky or ashen gray color of his nail beds, his gasping respiration, and his dilated pupils and dry conjunctiva. There was a small, oval, traumatized area in approximately his left anterior axillary line at approximately the sixth intercostal space, and a foreign object, thought to be a bullet, could be palpated in his right posterior axillary line at about thoracic dermatome ten.

No time was expended in making these observations and evaluation of the patient's status, for at the time the endotracheal tube was being inserted, three members of the staff were performing venous cutdowns, one in each lower extremity and one in the left forearm. These were performed by Drs. Coln, Crenshaw, and Gustafson. Because of the obvious chest wound and appearance of pneumothorax on the left, Dr. Jones inserted a chest tube and connected it to a closed waterseal drainage bottle. The head of the emergency room cart was lowered into a Trendelenburg position. There was no perceptible peripheral arterial pulsation. However, the cardioscope tracing showed electrical cardiac activity with a heart rate of approximately 130 per minute. Blood was sent to the blood bank for immediate typing and crossmatching, and two units of uncrossmatched type O, Rh negative blood was started by pressure infusion from plastic

blood containers.

It was obvious that this patient had sustained such an injury that he was continuing to lose blood internally very rapidly. Drs. Shires, McClelland, and Perry collaborated in the decision to move the patient immediately to the main operating suite for emergency laparotomy, since the suspected path of the bullet would seem to traverse the left leaf of the diaphragm, the aorta and inferior vena cava, and perhaps the right kidney and part of the liver. (Dr. Risk had inserted a Foley catheter into the urinary bladder, obtaining only a scant quantity of urine which was not blood tinged.)



With the anesthesia machine still connected to the patient, he was transported to the elevator and into the operating room which had already been prepared for emergency surgery. The abdominal incision was made at 11:44 a.m., 12 minutes from the time the patient was first admitted to the emergency operating room.

The operating team consisted of Drs. Shires, McClelland, Perry, and Jones. The anesthesia team consisted of Drs. Akin, Jenkins, and Dr. Harlan Pollock, resident on anesthesiology.

In describing the patient's condition and the parasurgical considerations, Dr. Jenkins says that by the time of the beginning of surgery, type-correct blood (A-1, Rh negative) was available and was administered under pressure through the three venous cut-downs. Dr. Curtis Spier, fellow in anesthesiology, cannulated a vein in the right forearm to aid in fluid replacement.

Under the influence of blood administration and pulmonary ventilation with 100 per

cent oxygen, the patient's pulse rate slowed from 130-150 to 80 per minute, and by 12 o'clock he had a discernible peripheral blood pressure, recorded at about 60 systolic, and by 12:10 p.m. his blood pressure was 90/60 and his pulse rate remained regular at 80 per minute.

By 12:15 p.m. he had received 3000 ml. of blood and 800 ml. of 5 per cent dextrose in lactated Ringer's solution. Estimated and measured blood loss at this time was 4000 ml.

By 12:30 p.m. he had received 6000 ml. of blood and 1 gm. of calcium gluconate intravenously. His measured blood loss at this time was 5000 ml., and it was also obvious that an additional quantity was sequestered in his bowel lumen and bowel wall.

At this time the surgical and anesthesia teams consulted about the patient's fluid status and decided that he needed a quantity of balanced salt solution; therefore, in two of the cutdown veins, 5 per cent dextrose in lactated Ringer's solution was begun. (Despite this rapid blood and fluid replacement, the patient's pulmonary status seemed satisfactory in that there was no perceptible change in compliance, as judged by the resistance to ventilation by compressing the reservoir breathing bag.)

At 12:37, Dr. Akin, who was monitoring the heart sounds with a chest stethoscope, reported that the cardiac tones were becoming weaker and the pulse rate was slowing from the previous rate of 80, to 60, to 40, to 30, and then became imperceptible. (These changes in rate were verified by a change in electrical activity as shown on the cardiograph.) Palpation of the heart through the diaphragm from the abdominal operating site was performed by Dr. Shires, who reported that he could not feel cardiac activity and he noted that the aorta had now ceased to pulsate. Dr. Perry opened the left chest with an incision at approximately the fourth intercostal space, extending from the sternum laterally to the left anterior axillary line. Under direct vision it was verified that rhythmic cardiac activity had ceased, the heart was dilated. Ten milliliters of 10 per cent calcium chloride were injected into the chamber of the left ventricle. The heart, which had been flaccid prior to this injection, showed an increase in muscular tone and was not dilated. One mg. of epinephrine hydrochloride in 90 mg. of 1 per cent lidocaine was injected into the left ventricular chamber, reducing the heart in overall size.

Ventricular fibrillation ensued. Manual cardiac systole (cardiac massage) was begun by Dr. Perry while the internal defibrillation apparatus was readied. Four attempts at ventricular defibrillation were made, with Dr. McClelland applying the defibrillation paddles to the heart, utilizing successively voltages of 240, 360, 500, and 750 without successfully effecting defibrillation. Between the applications of the defibrillation paddles, manual cardiac systole was continued alternately by Drs. Perry and McClelland.

At 12:55 p.m., the internal pacemaker, provided by Dr. Bashour, was attached to the heart, but the electrical stimulus provided by this pacemaker was not effective in producing visible cardiac systole. Two other attempts at internal defibrillation were made. The second defibrillating current produced asystole, but the internal pacemaker still did not stimulate effective cardiac activity.

Manual cardiac systole was re-started, causing palpable carotid pulse, but the patient's obvious external appearance was that circulation was ineffective as judged by the development of an ashen gray cyanosis. With an ophthalmoscope, Dr. Jenkins had periodically checked the retina for circulation during the resuscitative processes, and the retina could be visualized until 1:05 p.m., when

it was apparent that the lens had become opaque, and retinal circulation was not observed. The patient was pronounced dead at 1:07 p.m. The bullet which was palpable in the right posterior axillary line was removed and sent out by the operating room supervisor, Miss Audrey Bell, to be turned over to the legal authorities.

As a summary of fluid replacement, this patient received 15 and 1/2 units of blood and 4200 ml. of 5 per cent dextrose in lactated Ringer's solution.

It is Dr. Jenkins personal feeling that all methods of resuscitation were instituted expeditiously and efficiently. Having observed this patient from the time he was wheeled into the emergency operating room, Dr. Jenkins felt that Oswald sustained a period of cerebral hypoxia or anoxia for the period of time lapsing between the gunshot wound which he received and the time that effective ventilation with oxygen was started in the emergency operating room. Considering the cerebral changes which would begin at the time of initial anoxia, notably cerebral edema, Dr. Jenkins felt that many vital centers, including the cardiovascular center, were irreparably damaged, despite all resuscitative measures, introducing the final cardiac asystole. The trauma which patient Oswald had sustained was too great for resuscitation.

Medical History

Gunshot Wounds of Four Presidents

AS LONG AS man tries to understand his environment, historians will probably compare one great event to similar preceding ones. Physicians, too, will evaluate significant medical events and try to put them in perspective.

Up until Nov. 22, 1963, physicians who studied gunshot wounds pondered over the aspects of medical care given to three assassinated Presidents of the United States. Now, the type of injury and the treatment of a fourth President has been entered into journals for comparison. In addition, the treatment of Governor John Connally of Texas may be studied and compared in the same books because of the event that linked him with President Kennedy.

Dr. S. B. Harper, reporting in the *Pro-*

ceedings of the Staff Meetings of the Mayo Clinic in January, 1944, described the injuries and treatment of Presidents Lincoln, Garfield, and McKinley.

Lincoln

The fatal bullet which struck Abraham Lincoln entered the occipital bone at the level of the transverse sinus about an inch to the left of the midline. "The path of the bullet," reports Dr. Harper, "was then obliquely forward across the brain, ending in the right frontal lobe. Extensive comminuted fractures of both orbital plates occurred, these apparently were the result of contrecoup since the dura over the frontal lobe was