

INVESTIGATIONS

Dispute on JFK assassination

Eighteen years later, Dallas medical team disagrees: where was the

By Ben Bradlee
Globe Staff

DALLAS — Buried in the mounds of books, official reports and investigative files on the assassination of John F. Kennedy on Nov. 22, 1963, is a dispute about the medical evidence that has never been resolved.

The crux of the issue is the precise location of the gaping head wound which all concerned acknowledge that the President sustained.

The gaping head wound was seen by at least 12 doctors and four nurses who treated Kennedy at Parkland Memorial Hospital here minutes after he was shot. Fourteen of the 16 were interviewed recently by The Globe. Eight of those said that an official tracing of an autopsy photograph of the back of the President's head does not show the wound as they recall it.

What significance the dispute plays in unraveling the puzzle of the Kennedy assassination is uncertain: If the recollections of these doctors and nurses are correct, it could ultimately mean that the Warren Commission was wrong in its conclusion that Kennedy was shot from the rear by a single gunman; or, it could be simply an indication that the doctors and nurses were wrong about what they think they saw.

Eleven of the doctors and three of the nurses (none of whom has seen the actual Kennedy autopsy photographs) were shown the tracing of the most pertinent autopsy photo, which was prepared for the House Select Committee on Assassinations and published in its final report in 1979.

A 12th doctor who treated the late President refused to be interviewed and a fourth nurse could not be reached by The Globe. But both are on record as having placed the head wound in an area which is not consistent with the official tracing.

Neither the Warren Commission nor the House Assassinations Committee, which concluded that President Kennedy was "probably" assassinated as part of a conspiracy, attempted to resolve the discrepancies by showing the autopsy photos to the Parkland doctors and nurses. Critics have called this a fundamental flaw in both investigations.

A majority of the doctors and nurses interviewed this year (five of the doctors, three of the nurses) said they recalled seeing a large wound in the right rear of Kennedy's head. The tracing of the autopsy photograph

BOSTON SUNDAY GLOBE

evidence persists

President's mortal head wound?

Photograph shows what appears to be a flap of bone protruding from the right side of the head. But the back of the head shows no gaping wound.

'There's a definite conflict'

"There's a definite conflict," commented Dr. Richard B. Dalany when shown the official tracing. "That's not the way I remember it."

"It's not true," added Doris M. Nelson, nursing supervisor of the Parkland emergency room the day of the assassination, when she examined the official tracing. "There wasn't even hair (in the back of the head) . . . It was blown away. All that area was blown out."

In testimony before the Warren Commission or in earlier written reports, all the Dallas doctors and nurses who made specific reference to the location of the head wound either said it was squarely in the occipital area (back of the head) or that it extended from the right parietal area (side of the head) into the occiput.

If these doctors were precise in their application of the terms occipital and parietal, why isn't such a wound visible in the autopsy photograph taken of the back of the head?

One possible explanation is that the doctors and nurses, considering that they were more concerned with saving Kennedy's life than observing his wounds, were mistaken in their observations, or were imprecise in describing what they saw. However, the Dallas doctors and nurses who dispute the accuracy of the official tracing told The Globe they are firm in their recollections.

Critics of official investigations into the Kennedy assassination have advanced two other possible explanations: 1) that the photo in question has been doctored to eliminate evidence of a gaping exit wound in the back of the head to make the evi-

defence conform to the official theory that Kennedy was shot from the rear by Lee Harvey Oswald, acting alone, or 2) that the President's head wounds were surgically altered before his body arrived at Bethesda Naval Hospital in Maryland for autopsy.

Kennedy is officially said to have sustained two wounds, one which entered in the lower back of his neck and exited at his throat and one which entered the back of his head and exited at the right side of his head, creating a gaping wound. The most detailed description of the large head wound given the Warren Commission was furnished by Dr. Robert N. McClelland, a surgeon who treated Kennedy in the Parkland emergency room. But McClelland put

this large defect in the back of the head, not the side.

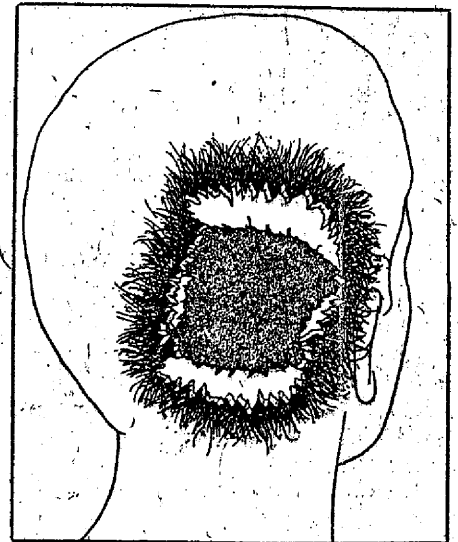
McClelland told the Warren panel he stood at the head of the operating table and thus was in "such a position that I could very closely examine the head wound, and I noted that the right posterior portion of the skull had been extremely blasted. It had been shattered, apparently, by the force of the shot so that the parietal bone was protruded up through the scalp and seemed to be fractured along its right posterior half, as well as the occipital bone being fractured in its lateral half, and this sprung open the bones that I mentioned in such a way that you could actually look down into the skull cavity itself and see that probably a third or so, at least, of the brain tissue, posterior cerebral tissue and some of the cerebellar tissue, had been blasted out."

NOTED BY SOURCES

The autopsy and its findings have been discussed in books and articles by such critics as Edward Epstein, Harold Weisberg, Sylvia Meagher, Vincent Salandria and Cyril Wecht. Harrison Livingstone, a Baltimore researcher, first showed the official tracing of the autopsy photograph of the back of President Kennedy's head to several of the Dallas doctors, and elicited doubts from them as to the tracing's accuracy.

Controversial artist's drawing

One of the many amateur investigators of the assassination who has published a book about the event, Josiah Thompson, a former professor of philosophy at Haver-



Left: The official tracing commissioned by the House Assassinations Committee of a photo taken of the rear of President Kennedy's head during his autopsy. Flap of bone protrudes at right, but no gaping wound can be seen. Arrow (added by Globe) shows a small entrance wound in the cowlick area, about four inches higher and to the left of where the autopsy doctors located it in their report.

Right: A drawing representing the location of Kennedy's gaping head wound as described by Dr. Robert N. McClelland, one of the Dallas doctors who treated him. A majority of those doctors and nurses attending Kennedy who were in a position to see the head wound agree with McClelland and dispute the official tracing.

ford College, commissioned an artist to prepare a drawing based on the McClelland description. The drawing, approved by McClelland prior to its publication in the book, depicts a fist-sized wound with edges scored out in the lower right rear of the head.

McClelland reaffirmed in a recent telephone interview that the drawing was what he "vividly remembers" the head wound looking like.

Some Warren Commission critics and other researchers have erroneously cited this drawing as representing the Dallas doctors' and nurses' sole view of the head wound.

Actually, according to Globe interviews, they are not unanimous in their opinions or recollections. Five of the doctors and nurses agree with McClelland on the drawing and strongly assert that the wound was in the back of the head; four other doctors say that the tracing of the autopsy photograph shown them by The Globe is "consistent" with their recollection of the head wound.

Two doctors lean toward this official

view, while five others tend toward the McClelland view that the wound was in the rear of the head, but fall short of giving it a blanket endorsement.

Of the six doctors who said that they agree or tend to agree with the official tracing showing no gaping wound extending into the occipital region, five have, at one time or another, gone on record as saying that the wound did extend into the occiput.

For example, Dr. Charles J. Carrico, the first physician to treat Kennedy, testified twice before the Warren Commission, first describing the head wound as "a large, gaping wound located in the right, occipital-parietal area," and then as a "five by (seven) cm. defect in the posterior skull, the occipital region." Carrico was not interviewed by The Globe, but in a letter sent in response to questions, he said the official tracing of the autopsy photograph showed "nothing incompatible" with what he remembered of the back of the head.

The sixth doctor supportive of the official tracing, Dr. Robert G. Grossman, now a professor and chairman of the department of neurosurgery at the Baylor College of Medicine in Houston, was working next to the senior neurosurgeon present, Dr. Kemp Clark, at Kennedy's head. Grossman told The Globe that he observed two separate wounds: a large defect in the parietal area above the right ear, and a second wound, about one-and-a-quarter inches in diameter, located squarely in the occiput. Grossman, the only physician to report seeing two such distinct wounds, was never called to testify before the Warren Commission or the House Assassinations Committee. Nor were Dr. Dulany or Nurse Patricia Gustafson, one of those who said

that Kennedy's gaping wound was in the back of his head.

Disagreement on wound's visibility

In interviews, some doctors doubted the extent to which a wound to the rear of the head would have been visible since the President was lying supine with the back of his head on a hospital emergency cart.

But others, like Dulany and Grossman, said the head at some point was lifted up, thereby exposing the rear wound. Added Gustafson: "One of the doctors asked me to put a pressure bandage on the head wound and I tried to do so, (but) there was really nothing to put a pressure bandage on. It was too massive. So he told me just to leave it be." The wound, she said, was in "the back of the head."

"Definitely in the back?" she was asked.

"Yes," she said.

To critics of the official investigations,

it is inconceivable that the presumably skilled Dallas doctors, conversant with anatomical terms, would consistently mis-use words like "cerebellum" and "occipital" and say that the wound extended into the back of the head if, in fact, it did not.

But speaking to the occipital question, Grossman, a neurosurgeon, suggested that part of the confusion surrounding the location of the head wound could be the result of the imprecision with which the term "occipital" is used. While the occiput refers specifically to a bone in the lower back section of the head, Grossman said many doctors loosely use the term to refer to "the back fifth of the head." There is this ambiguity about what constitutes the occipital and parietal area. It's very imprecise.

Until now, to critics, the most plausible explanation for the discrepancy between the Dallas observations and the autopsy photograph of the rear of the head was that the photo was a forgery.

Some of the critics, notably the House Assassinations Committee's own photographic consultant, Robert J. Groden of Lodi, N.J., have argued that the failure of the Warren Commission and the House committee to show the autopsy photographs to the Parkland doctors and nurses cast doubt on the House committee's conclusion that the photos were authentic. The question of authenticity was not addressed by the Warren panel.

In a little-noticed dissent published in one of the appendices to the House committee report, Groden, who did the original optical enhancement work of Abraham Zapruder's now-famous home movie of the assassination, asserted that four of the autopsy photographs (two in color, two in black and white) showing a similar view of the back of the President's head had been altered to eliminate evidence of a gaping hole in the back of the head.

Based on the recent doubts voiced by:

most of the Dallas doctors and nurses. The Globe last month received permission from the Kennedy family to view the autopsy photographs at the National Archives in Washington. This was done with the aid of three independent photo-optics experts to determine the validity of Groden's allegations.

All of the photo consultants concluded that the photographs were authentic. (See accompanying article.)

Author David Lifton, in his new book "Best Evidence," published by Macmillan, advances a different, far more radical explanation for the discrepancies between

ASSASSINATION, Page A24

■ ASSASSINATION

Continued from Page A23

the observations of the Dallas doctors and the autopsy photographs: that between the time Kennedy's body left Dallas and the time it arrived in the autopsy room at the Bethesda Naval Hospital in Maryland some six hours later, the wounds on the corpse were surgically altered to change the evidence concerning the number and direction of shots, as part of a plot to support the single-assassin theory.

Lifton cites an FBI report prepared by two agents who attended the autopsy, James Sibert and Francis O'Neill. The report, declassified and released years after the Warren report was published, states that "... it was also apparent that a tracheotomy had been performed, as well as surgery of the head area, namely in the top of the skull." No surgery other than the tracheotomy was performed by the Dallas doctors. In subsequent memoranda, Sibert explained that his statement was based on

REMARKS MADE AT THE TIME BY THE LEAD AUTOPSY, Dr. James J. Humes.

The 700-page book, whose thesis Lifton himself admits strains the imagination, is nonetheless a thoroughly researched account based largely on public documents and buttressed by new evidence in the form of statements from several Bethesda hospital technicians and military bystanders who were eyewitnesses to the movements of Kennedy's body.

Concerned that some of these witnesses might later retract what they told him, Lifton recorded their statements on videotape which has been viewed by The Globe. Lifton said he was moved to interview the Bethesda attendants after reading a statement in one of the volumes of the House

1979, saying that Kennedy's body had arrived at Bethesda in a body bag. This conflicted with the testimony of many witnesses who told the Warren Commission the body left Dallas wrapped in sheets.

Lifton located witnesses who told him that Kennedy's body first arrived at Bethesda in a plain gray shipping casket, not the bronze casket it left Dallas in, and that the body was inside a zippered body bag.

In a telephone interview, retired Brig. Gen. Godfrey McHugh, President Kennedy's Air Force aide who said he was with the President's casket for all but five minutes or so that day, castigated Lifton's book as "absolutely absurd; it's full of lies and false implications." When he wasn't with the casket, McHugh said, Mrs. Kennedy, aides or the Secret Service always were. He said he saw the President's body taken out of the bronze casket inside the Bethesda morgue, but he conceded he could not attest to the fact that the body was inside that casket from the time it left Parkland Hospital until it reached the morgue.

Besides photo forgery, rejected by The Globe panel, and the more radical Lifton thesis of surgical alteration, there is a third, quite innocent, possibility advanced by some, including the House Assassinations Committee, as an explanation for the discrepancies between the Dallas and Bethesda observations: that the Parkland physicians, concerned chiefly with trying to save Kennedy's life rather than observe his wounds, simply were mistaken in what they saw.

A variation of the mistaken hypothesis is that, as Dr. Grossman suggested, the Dallas doctors erroneously described the head wound. The autopsy photograph of the right side of Kennedy's head, seen by The Globe at the National Archives but not shown to the Dallas doctors, depicts a massive wound which extends about two inches behind the ear toward the back of the head. It is possible, according to Grossman, that the doctors loosely used the word "occipital" in describing a wound that extended to the back fifth of the head, or that they assumed, without lifting up the head, that the defect did reach the back.

Whatever the answer, it is likely that few will be satisfied, and that The Globe's Dallas interviews add up to another mysterious footnote to the Kennedy legacy.