


# The Baltimore CHRONICLE

Vol. 7, No. 5

August 15, 1979



Druid Hill Avenue and Eutaw Street during the Sesqui-Centennial 1880. Photo from *Baltimore Two Hundredth Anniversary*.

House Report of Kennedy Assassination Inadequate:

## Parkland Doctors' Testimony Shows Autopsy Photos Forged

by Harrison E. Livingstone  
Dallas, July 30, 1979

As this paper first reported in June (verified and carried by *The Baltimore Sun* on July 9), the autopsy photographs of the body of President John F. Kennedy are forgeries, altered with a visible matte insertion.

This reporter has since conducted a number of interviews with the doctors at Parkland Hospital in Dallas who treated the President in his final moments.

Without exception, the doctors—when shown the altered autopsy photo—declared it fake, and described wounds entirely different from those alleged by the Warren Commission.

The Parkland doctors repeated their previous testimony (made before journalists, the Warren Commission and the recent Assassination Committee) that the

back of Kennedy's head was blown away, leaving "a large, gaping wound," said Dr. Adolph H. Giesecke, Jr. Dr. Giesecke stated that the doctors at Parkland had raised the head from the table and shined a light through the hole. "Much of the back of the brain was missing," he said.

On viewing the faked autopsy photo of the back of President Kennedy's head, Dr. Jackie Hunt said, "I can do a lot of funny things in my darkroom, too." She described a large hole in the back of the head, with the occipital parietal bone blown away.

"Why do they cover it up?" Dr. Fouad Bashour repeated several times. Dr. Bashour, a cardiologist, worked to keep the President's heart beating. He repeatedly demonstrated with his hand that the back of the President's head was

See Page 3

# KENNEDY HAS OTHER ANOTHER WOUND

Continued From Page 1

blown away.

This doctor looked at the drawing taken from the autopsy photo, shown on page 104 of Volume VII of the medical evidence, and said, "This is not the way it was." He pointed to a flap of skull on the side of the head in the picture and asked, "What's this?", adding, "No. Why do they cover it up?"

None of the doctors recognized the "entry wound" on the back of the head in the picture. Dr. Marion Jenkins repeatedly poked at the occipital protuberance and said, "This is where the wound was."

Dr. Robert Shaw said, "If the body hadn't been stolen away from us, and had Dr. Rose performed a proper autopsy, there would be no question these 15 years."

Dr. Charles Baxter said that, without question, the back of the President's head was blown away. "It was a large, gaping wound in the occipital area," he said, "a tangential wound."

Dr. Baxter also stated that the wound in the throat, which was never discovered by the autopsy doctors, was "no more than a pinpoint. It was made by a small caliber weapon. And it was an entry wound."

Dr. Donald Seldin did not want to talk to anyone. "I just can't remember, I just can't help you," he said. "It's been so long. What is it now? Fifteen years?"

Dr. Robert McClelland, a neurosurgeon, confirmed also that the right posterior portion of the skull had been blown away, and states that the drawing on page 140 of *Six Seconds In Dallas* by Josiah Thompson was an accurate representation of the rear head wound.

Dr. Paul C. Peters, who was not present at the time of the interview,

returned the two differing illustrations of the back of the President's head—the one offered as evidence in the Committee, and the other in Thompson's book—and stated, "I have marked an 'X' on the picture which more accurately depicts the wound, although neither is quite accurate in my opinion. There was a large hole in the back of the head through which one could see the brain." Dr. Peters' X was on the Thompson drawing.

Dr. Giesecke expressed disturbance that the President's body was so quickly removed from Texas and that a proper autopsy was not conducted by the military. (The many faults of this autopsy are outlined in Vol. VII of the Appendix to *The Report of the Assassination Committee*, page 193.)

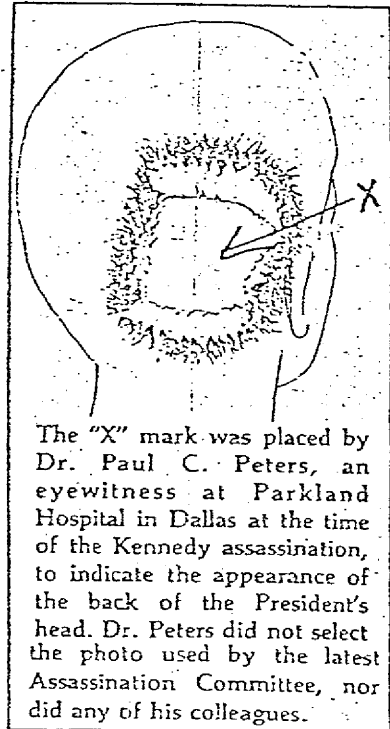
General Philip Wehle, Commanding Officer of the U.S. Military District, Washington, D.C., was present in the autopsy room at Bethesda Naval Hospital when Kennedy's body was examined, and "ordered us not to perform certain procedures," said Dr. Pierre Finke.

The wound through the back was therefore never probed to see if it connected to the throat wound. Had this been done, there would be proof as to whether the President was struck from behind in the back, or from in front in the throat, or if a single bullet passed through the President from behind and struck Governor Connally.

Additional gunshot wounds found at that time would have proved a conspiracy then. It is only now that the Assassination Committee is admitting to an extra gunshot from the grassy knoll, which therefore admits to an additional gunman, and a conspiracy.

\*\*\*  
Lt. William Pitzer, who was supposed to have taken the autopsy photos of the President, was—according to a story in *The Waukegan News-Sun* on May 1, 1975) murdered. He was shot with a .45 caliber pistol and found with the gun in his right hand, though he was left-handed. Pitzer's death was ruled a suicide. Pitzer has evidently become a non-person in the case; his name does not appear on the list of those present at the autopsy that was published by the Committee on page 8 of volume VII.

An examination of the two drawings that accompany this article will reveal the wide discrepancy between what the Committee accepted as evidence and what many reliable medical witnesses have attested to.



The "X" mark was placed by Dr. Paul C. Peters, an eyewitness at Parkland Hospital in Dallas at the time of the Kennedy assassination, to indicate the appearance of the back of the President's head. Dr. Peters did not select the photo used by the latest Assassination Committee, nor did any of his colleagues.

THE UNIVERSITY OF TEXAS  
HEALTH SCIENCE CENTER AT DALLAS

DEPARTMENT OF SURGERY  
Division of Urology  
Paul C. Peters, M.D.  
Professor & Chairman  
Terry D. Allen, M.D.  
Professor

SOUTHWESTERN MEDICAL SCHOOL  
5325 Harry Hines Blvd  
Dallas, Texas 75225  
214/688-7206

August 7, 1979

Mr. H. E. Livingston  
30 West 25th Street  
Baltimore, Maryland 21218

Dear Mr. Livingston:

I have marked an "X" on the picture which more accurately depicts the wound, although neither is quite accurate in my opinion. There was a large hole in the back of the head through which one could see the brain.

Sincerely yours,

*Paul C. Peters*  
Paul C. Peters, M.D.  
Professor and Chairman  
Division of Urology

PCP:pl